TMD
Pankey E2

John R Droter DDS
Annapolis, Maryland

www.jrdroter.com

John R Droter, DDS

To get todays lecture slides:
go to www.jrdroter.com

Seminar Download

Pankey E2

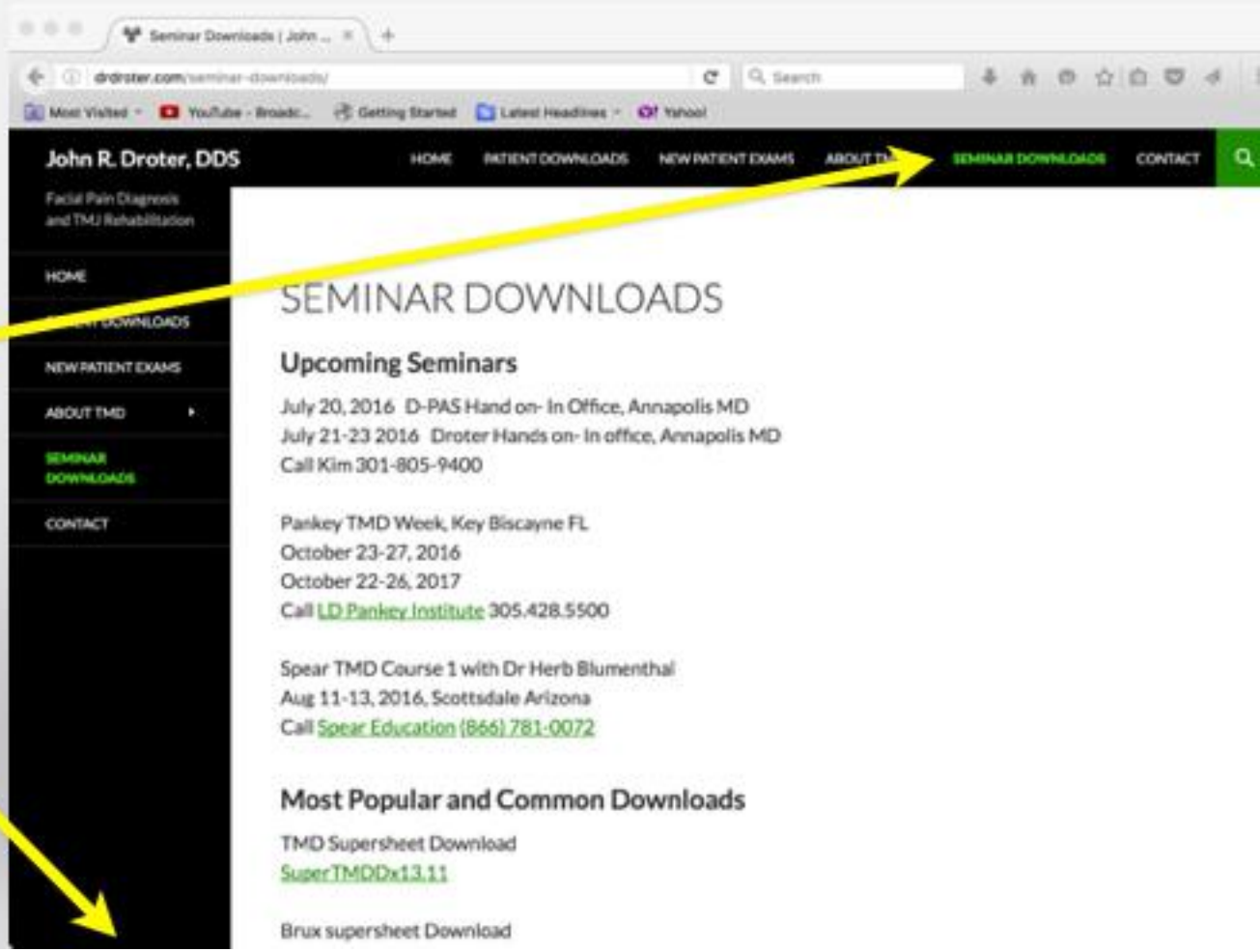

Hello. I am:

John R Droter DDS
Annapolis, Maryland

Milestones

Need to publish.....

Visiting Faculty Spear Education 2013

Visiting Faculty LD Pankey Institute 2008

Visiting Faculty Orthodontic Program
Washington Hospital Center 2000

On staff AAMC: Orthopedic Rounds
In OR for TMJ Surgery

Devoted Facial Pain Practice 1996
(No Hygiene to Check!!)

CT and MRI Imaging Joints 1992
Guy Haddix, DDS: Mentor
(3,100 images and rising)

Post Grad CE- GPR, LD Pankey Institute, Dawson, Mahan, Gremillion, Spear, Kois

Disclosures:

Ski Coach for National Ski Patrol
Level 3 Certified Profession Ski Instructors of America

Atomic Skis- Sponsored.
I do benefit financially.

LD Pankey Institute- I am paid
a small honorarium for lectures

BioResearch- "Product Refinement"
I call and make suggestions.
I started buying equipment 1999.
Started teaching training 2013.
Paid honorarium for training lectures

Spear Education- Paid honorarium for lectures

All of my slides have been altered with respect to cropping and exposure. None have been "photoshopped" to misrepresent reality

You have TMD patients in your practice

Headaches

Fatigued

16 yo F

Parafunctional Grinding

Parafunctional Clenching

Why is TMD So Confusing?

John R Droter DDS
Annapolis, Maryland

Short

The Diagnostic Process

When diagnosing and treating facial pain, we have entered the world of medicine.

Think!!

Differential Diagnosis
All the choices

Diagnostic tests (Observations)
Narrow down the choices

Working Diagnosis
Treating as if

Not completely resolved

Final Diagnosis
Only after problem resolved

Always make a differential diagnostic list
Ask, " It appears to be this, but what else could it be?
Be aware you are blinded by your beliefs

Differential Diagnosis
Diagnostic Boxes: Pattern Recognition

"My Tooth Hurts"

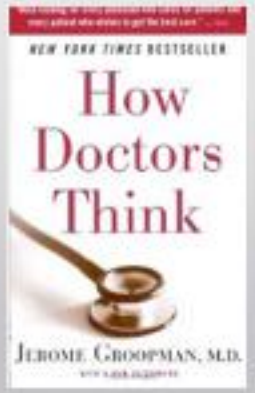

Differential Diagnosis
Diagnostic Boxes: Pattern Recognition

"My Tooth Hurts"

- Reversible Pulpitis secondary to caries
- Irreversible Pulpitis secondary to caries
- Pulpitis secondary to split tooth
- Pulpal necrosis
- Sinus Infection
- Sympathetic Mediated Pain
- Referred Pain from Muscle Trigger Point
- Neuroma

- Periodontal Infection
- Inflamed Tissue secondary to popcorn husk
- Aphthous Ulcer

- Periodontal ligament inflammation secondary to Occlusal Trauma
- Pulpits secondary to Occlusal Trauma
- Other

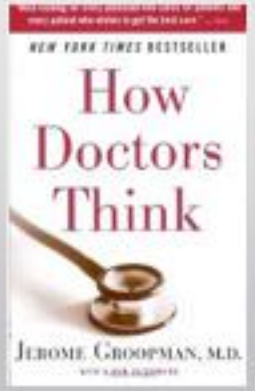

Referred Pain

Convergence

More primary sensory neurons than secondary neurons that travel to brain

50:1 Ratio

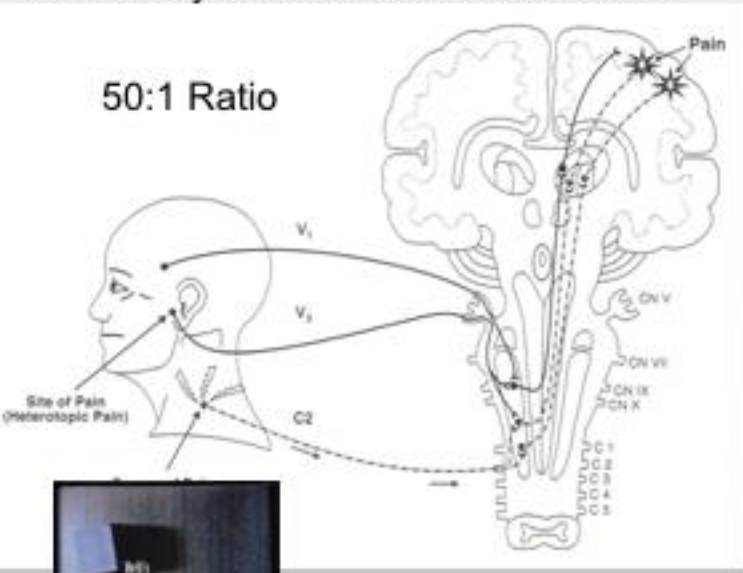

"Bells Orofacial Pain"
Jefery Okeson

Trigger Points

Contracted mass of actin, myosin and histamine

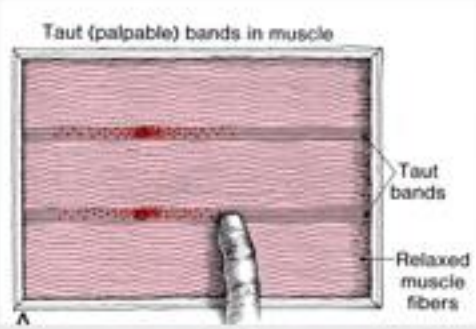

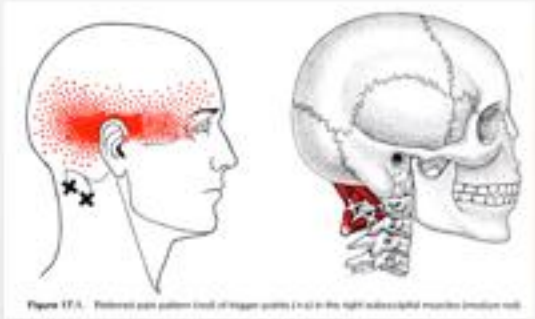

"The Trigger Point Manual"
Janet Travell, MD

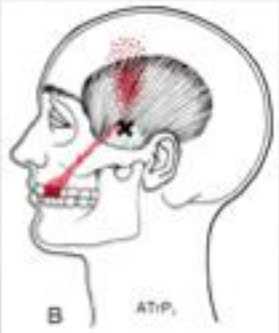

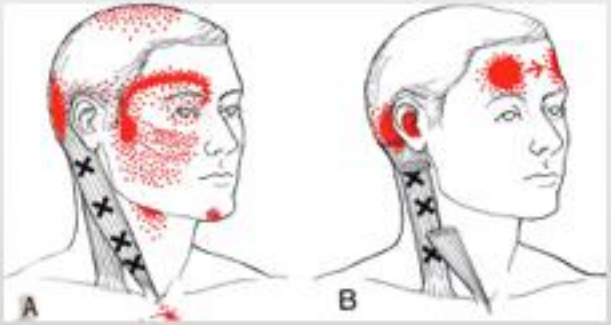

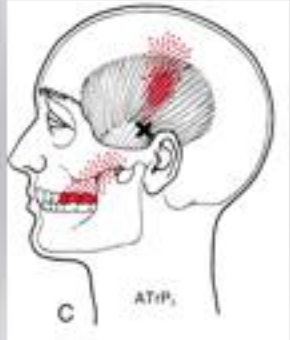

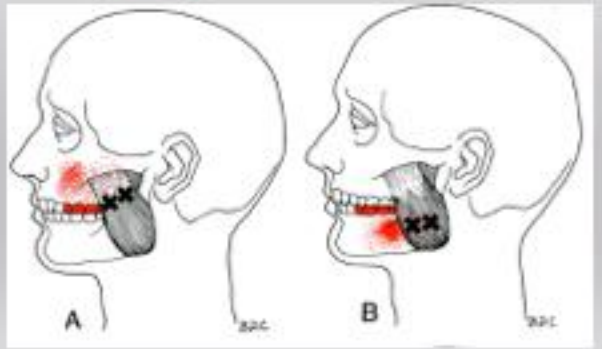

Differential Diagnosis
Diagnostic Boxes: Pattern Recognition

"My Tooth Hurts"

- Reversible Pulpitis secondary to caries
- Irreversible Pulpitis secondary to caries
- Pulpitis secondary to split tooth
- Pulpal necrosis
- Sinus Infection
- Sympathetic Mediated Pain
- Referred Pain from Muscle Trigger Point
- Neuroma

- Periodontal Infection
- Inflamed Tissue secondary to popcorn husk
- Aphthous Ulcer

- Periodontal ligament inflammation secondary to Occlusal Trauma
- Pulpits secondary to Occlusal Trauma
- Other

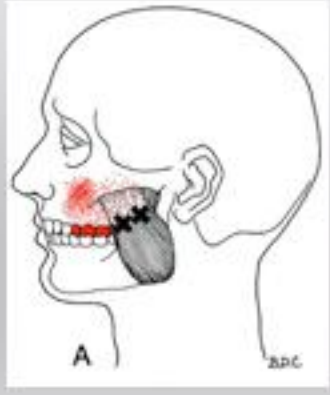

"How Doctors Think", by Jerome E. Groopman

Diagnose by Pattern Recognition
Tendency to make patients fit what we know
Ignore signs and symptoms that do not fit

Always make a differential diagnostic list
Ask, " It appears to be this, but what else could it be?
Be aware you are blinded by your beliefs

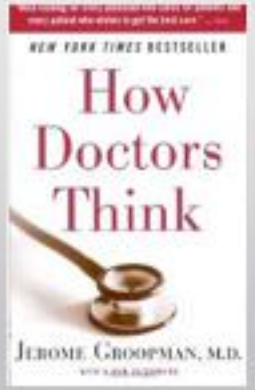

TMJ/TMD Confusion

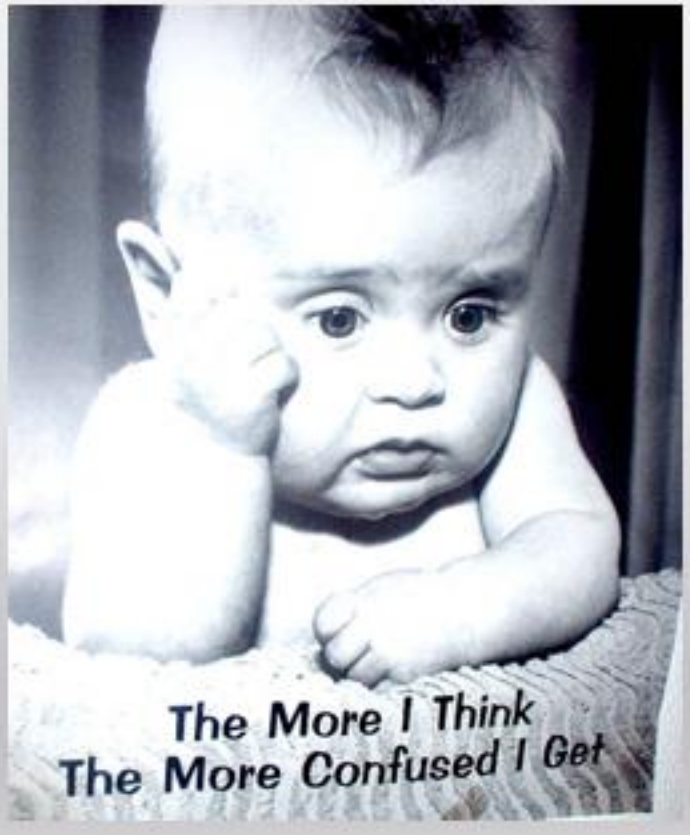

Dogmatic Arguments

Why Confusion?

TMD/TMJ
Symptoms based

Not One Disease

Temporomandibular Disorders (TMD) is an umbrella term covering any condition causing pain or dysfunction in the temporomandibular joint, muscles of mastication, trigeminal nerve, facial nerve, and associated head and neck musculoskeletal and neural structures.
Craniomandibular Disorders would be a better term (CMD).

TMDs- What are the choices? (190 Diagnoses, 7 Categories)

1. TMJ Damage

Adhesions and ankylosis of temporomandibular joint
Avascular Necrosis Mandibular Condyle
Cartilage Fibrillation, Mandibular Condyle, Fossa
Closed Lock, Jaw Cartilage, Acute
Closed Lock, Jaw Cartilage, Chronic
Closed Lock, Jaw Cartilage, Intermittent, Mechanically dysfunctional
Crush Injury Mandibular Condyle
Crystal arthropathy, unspecified, TMJ
Dislocation jaw cartilage due to injury, Sequela
Dislocation jaw cartilage with reduction, favorable adaptation, TMJ
Dislocation jaw cartilage without reduction, favorable adaptation, TMJ
Effusion, TMJ
Impingement Retrodiscal Tissue
Inflammatory Tissue Bone Resorption, TMJ Condyle
Loose Body (Joint Mice), TMJ
Malignant neoplasm of bones of skull and face
Open Lock TMJ, Recurring
Osteoarthritis TMJ, active degeneration
Osteoarthrosis- Inactive
Osteochondritis Dissecans TMJ
Osteolysis Mandibular Condyle, Active
Perforation Meniscus, TMJ
Perforation Pseudodisc, TMJ
Psoriatic Arthritis TMJ
Rheumatoid Arthritis Sero Negative TMJ

2. Muscles of the TMJ

Dystonia
Habitual posture forward mandible
Hemifacial Muscle spasm
Inhibitory Reflex Dysfunction, Periodontal Ligament Masseter Muscle
Muscle Atrophy, TMJ
Muscle Bracing Neck Stabilization
Muscle Bracing Pain Avoidance
Muscle Bracing TMJ stabilization
Muscle Bracing Airway **Patency** (with Tongue)
Muscle Contracture Fibrosis Lateral Pterygoid
Muscle Contracture Fibrosis Masseter, Medial Pterygoid, Temporalis
Muscle Fatigue Overuse
Muscle Hypertrophy TMJ Muscles

3. Cranial Alignment/Occlusion

Cranial Distortion / Misalignment
Hemifacial Hypoplasia
Hyper Occlusal Awareness
Iatrogenic Orthotic Damage
Malocclusion Anterior Open Bite
Malocclusion Centric occlusion MaxIC discrepancy
Malocclusion Deep Bite
Malocclusion due to mouth breathing
Malocclusion due to TMJ bone loss
Malocclusion due to tongue, lip or finger habits
Malocclusion Insufficient anterior occlusal guidance
Malocclusion lack of posterior occlusal support
Malocclusion Posterior Openbite Bilateral
Malocclusion Posterior Openbite Unilateral
Malocclusion unspecified
Malposition /Misalignment: Maxilla, Temporal Bone, Mandible
Mandibular asymmetry
Mandibular hyperplasia
Mandibular hypoplasia
Mandibular Retrognathia
Maxillary asymmetry
Maxillary hyperplasia
Maxillary hypoplasia
Maxillary Retrognathia
Occlusal Adaptation, Favorable
Occlusal Dependency for Joint Stabilization/ Proprioception
Tooth Intrusion
Tooth Supereruption

4. Cervical Damage

Cervical Vertebrae Alignment Dysfunction
Cervicocranial Syndrome
Muscle Guarding due Neck Instability
Trigger Point Neck Muscle with Referred Pain
Trigger Point Neck Muscle, Localized Pain

5. Parafunction

Excessive Tooth Wear, Damage
Hypersensitive Occlusion
Parafunction clech/grind wiggle
Parafunctional Clenching Teeth, Awake
Parafunctional Clenching Teeth, Sleep
Parafunctional Grinding Teeth, Awake
Parafunctional Grinding Teeth, Sleep
Parafunctional Tongue Bracing avoiding uncomfortable tooth contact
Parafunctional Tongue Bracing Neck stabilization
Parafunctional Tongue Bracing to maintain Airway
Parafunctional Tongue Bracing unknown cause

6. Whole Body / Systemic

Lyme Disease Arthritis
Magnesium Deficiency
Obstructive Sleep Apnea
Osteoporosis without current pathological fracture
Pathological Habitual Movement Pattern
Postural Disharmony Standing
Postural Disharmony Walking
Postural Forward Head Position
Upper Airway Resistance, UARS

7. Other

Nerve Entrapment Masseteric Nerve due to Masseteric hypertonicity
Neuroma Trigeminal Nerve
Obsessive-Compulsive Personality Disorder
Other
Otitis Ear Infection
Pain disorder exclusively related to psychological factors. Somatoform pain disorder
Pain disorder with related psychological factors
Retrolaval Sensitization

1. TMD: TMJ Damage and Diseases

Adhesions and ankylosis of temporomandibular joint
Avascular Necrosis Mandibular Condyle
Cartilage Fibrillation, Mandibular Condyle, Fossa
Closed Lock, Jaw Cartilage, Acute
Closed Lock, Jaw Cartilage, Chronic
Closed Lock, Jaw Cartilage, Intermittent, Mechanically dysfunctional
Crush Injury Mandibular Condyle
Crystal arthropathy, unspecified, TMJ
Dislocation jaw cartilage due to Injury, Sequela
Dislocation jaw cartilage with reduction, favorable adaptation, TMJ
Dislocation jaw cartilage without reduction, favorable adaptation, TMJ
Effusion, TMJ
Fracture of subcondylar process of mandible
Gout, TMJ
Growth Disturbance Prepuberty due to TMJ damage
Hemarthrosis TMJ, Traumatic
Hyperplasia Mandibular Condyle,
Hypoplasia Mandibular Condyle
Hypoxia Reperfusion Injury, TMJ Cartilage Damage
Hypoxic Progressive Condylar Resorption
Impingement Retrodiscal Tissue
Inflammatory Tissue Bone Resorption, TMJ Condyle
Loose Body (Joint Mice), TMJ
Malignant neoplasm of bones of skull and face
Open Lock TMJ, Recurring
Osteoarthritis TMJ, active degeneration
Osteoarthrosis- Inactive
Osteochondritis Dissecans TMJ
Osteolysis Mandibular Condyle, Active
Perforation Meniscus, TMJ
Perforation Pseudodisc, TMJ
Psoriatic Arthritis TMJ
Rheumatoid Arthritis Sero Negative TMJ
Rheumatoid Arthritis TMJ
Sprain Discal Ligament TMJ, acute with joint edema
Subluxation on Loading, TMJ
Subluxation on Movement, TMJ
Synovial Cyst (Ganglion Cyst)
Synovial Hyperplasia
Synovitis

My Core Belief

The TMJ is a synovial joint of the human body and will undergo the same disease processes as any other synovial joint

Understanding orthopedic medicine is the key to understanding joints, including the TMJ



Buy Salter's Orthopedic Textbook.
When you have a patient with specific disease (i.e. osteoarthritis), read that chapter.

Textbook of Disorders and Injuries of the Musculoskeletal System
Robert Salter MD

Maxillofacial Imaging
Larheim
Westesson

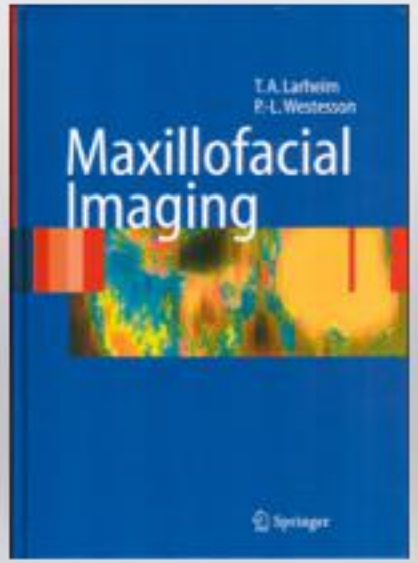

Stomatognathic System Interrelationship

A change in any one area
will affect the others

"Adaptation"

This is a **dynamic**
orthopedic System

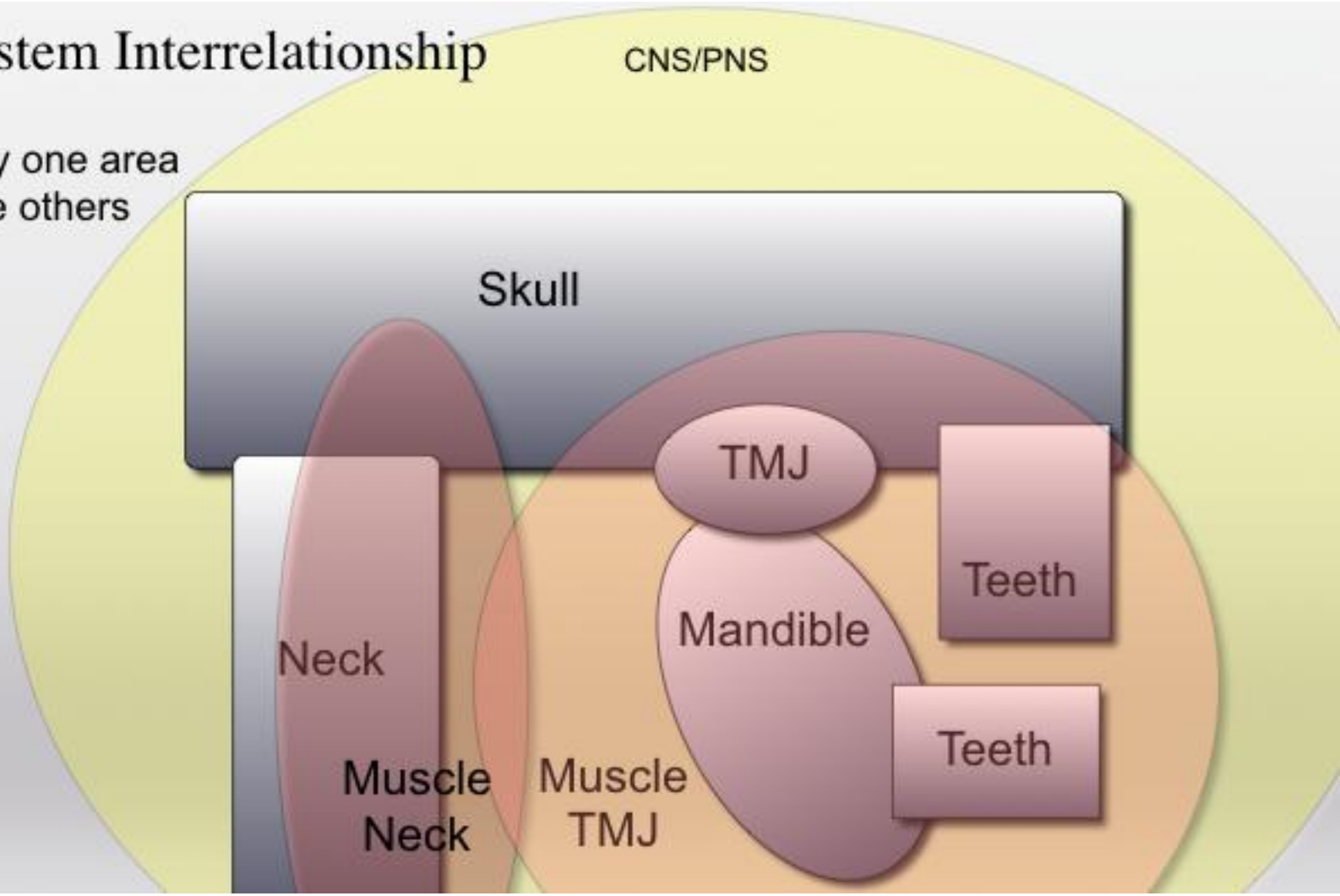

venn diagram

Stomatognathic System Interrelationship

A change in any one area
will affect the others

"Adaptation"

This is a **dynamic**
orthopedic System

Diagnosis each area separately
1. TMJ
2. TMJ Muscles
3. Occlusion
4. Neck and Neck Muscles
5. Parafunction
6. Whole Body

6

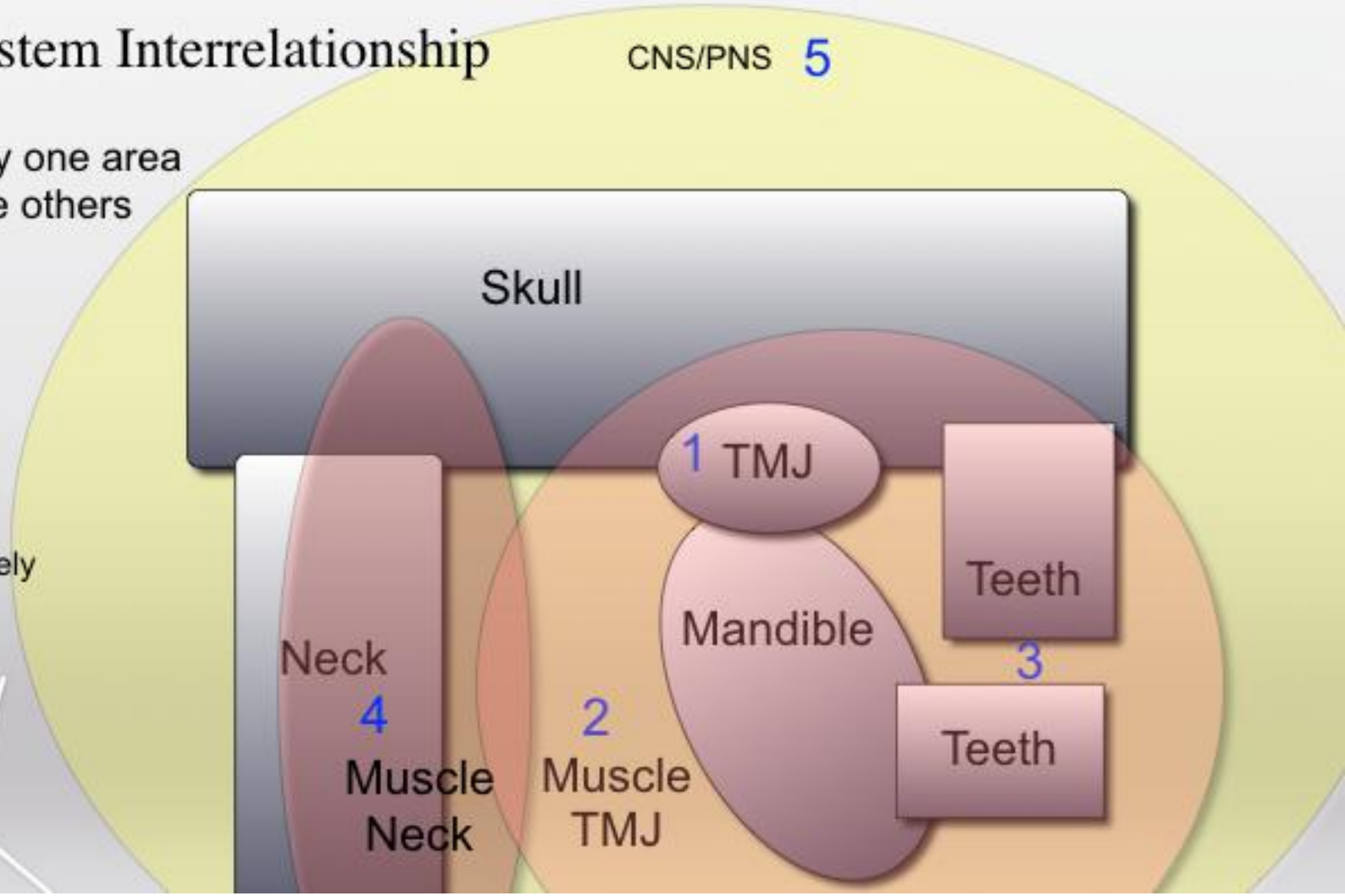

TMDs- What are the choices? (190 Diagnoses, 7 Categories)

1. TMJ Damage

Adhesions and ankylosis of temporomandibular joint
Avascular Necrosis Mandibular Condyle
Cartilage Fibrillation, Mandibular Condyle, Fossa
Closed Lock, Jaw Cartilage, Acute
Closed Lock, Jaw Cartilage, Chronic
Closed Lock, Jaw Cartilage, Intermittent, Mechanically dysfunctional
Crush Injury Mandibular Condyle
Crystal arthropathy, unspecified, TMJ
Dislocation jaw cartilage due to injury, Sequela
Dislocation jaw cartilage with reduction, favorable adaptation, TMJ
Dislocation jaw cartilage without reduction, favorable adaptation, TMJ
Effusion, TMJ
Impingement Retrodiscal Tissue
Inflammatory Tissue Bone Resorption, TMJ Condyle
Loose Body (Joint Mice), TMJ
Malignant neoplasm of bones of skull and face
Open Lock TMJ, Recurring
Osteoarthritis TMJ, active degeneration
Osteoarthrosis- Inactive
Osteochondritis Dissecans TMJ
Osteolysis Mandibular Condyle, Active
Perforation Meniscus, TMJ
Perforation Pseudodisc, TMJ
Psoriatic Arthritis TMJ
Rheumatoid Arthritis Sero Negative TMJ

2. Muscles of the TMJ

Dystonia
Habitual posture forward mandible
Hemifacial Muscle spasm
Inhibitory Reflex Dysfunction, Periodontal Ligament Masseter Muscle
Muscle Atrophy, TMJ
Muscle Bracing Neck Stabilization
Muscle Bracing Pain Avoidance
Muscle Bracing TMJ stabilization
Muscle Bracing Airway **Patentcy** (with Tongue)
Muscle Contracture Fibrosis Lateral Pterygoid
Muscle Contracture Fibrosis Masseter, Medial Pterygoid, Temporalis
Muscle Fatigue Overuse
Muscle Hypertrophy TMJ Muscles

3. Cranial Alignment/Occlusion

Cranial Distortion / Misalignment
Hemifacial Hypoplasia
Hyper Occlusal Awareness
Iatrogenic Orthotic Damage
Malocclusion Anterior Open Bite
Malocclusion Centric occlusion MaxIC discrepancy
Malocclusion Deep Bite
Malocclusion due to mouth breathing
Malocclusion due to TMJ bone loss
Malocclusion due to tongue, lip or finger habits
Malocclusion Insufficient anterior occlusal guidance
Malocclusion lack of posterior occlusal support
Malocclusion Posterior Openbite Bilateral
Malocclusion Posterior Openbite Unilateral
Malocclusion unspecified
Malposition /Misalignment: Maxilla, Temporal Bone, Mandible
Mandibular asymmetry
Mandibular hyperplasia
Mandibular hypoplasia
Mandibular Retrognathia
Maxillary asymmetry
Maxillary hyperplasia
Maxillary hypoplasia
Maxillary Retrognathia
Occlusal Adaptation, Favorable
Occlusal Dependency for Joint Stabilization/ Proprioception
Tooth Intrusion
Tooth Supereruption

4. Cervical Damage

Cervical Vertebrae Alignment Dysfunction
Cervicocranial Syndrome
Muscle Guarding due Neck Instability
Trigger Point Neck Muscle with Referred Pain
Trigger Point Neck Muscle, Localized Pain

5. Parafunction

Excessive Tooth Wear, Damage
Hypersensitive Occlusion
Parafunction clech/grind wiggle
Parafunctional Clenching Teeth, Awake
Parafunctional Clenching Teeth, Sleep
Parafunctional Grinding Teeth, Awake
Parafunctional Grinding Teeth, Sleep
Parafunctional Tongue Bracing avoiding uncomfortable tooth contact
Parafunctional Tongue Bracing Neck stabilization
Parafunctional Tongue Bracing to maintain Airway
Parafunctional Tongue Bracing unknown cause

6. Whole Body / Systemic

Lyme Disease Arthritis
Magnesium Deficiency
Obstructive Sleep Apnea
Osteoporosis without current pathological fracture
Pathological Habitual Movement Pattern
Postural Disharmony Standing
Postural Disharmony Walking
Postural Forward Head Position
Upper Airway Resistance, UARS

7. Other

Nerve Entrapment Masseteric Nerve due to Masseteric hypertonicity
Neuroma Trigeminal Nerve
Obsessive-Compulsive Personality Disorder
Other
Otitis Ear Infection
Pain disorder exclusively related to psychological factors. Somatoform pain disorder
Pain disorder with related psychological factors
Retrolaval Sensitization

Normal Joint with Normal Occlusion

All teeth touch evenly with condyles seated in fossa

What happens to the occlusion if
the disc is dislocated?

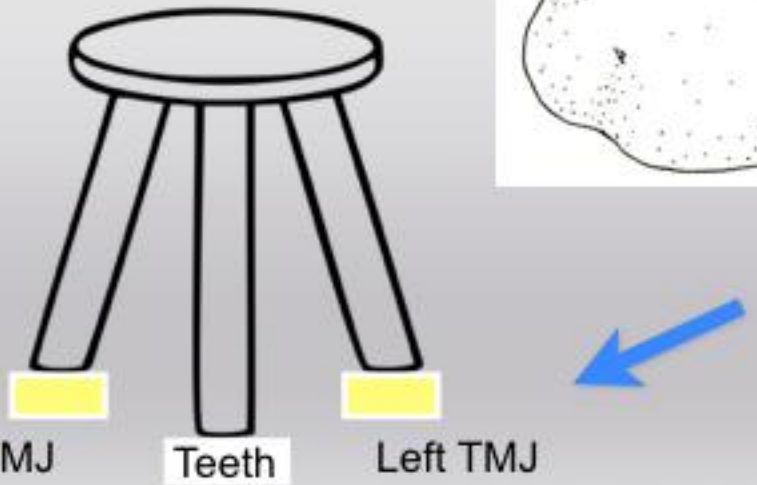

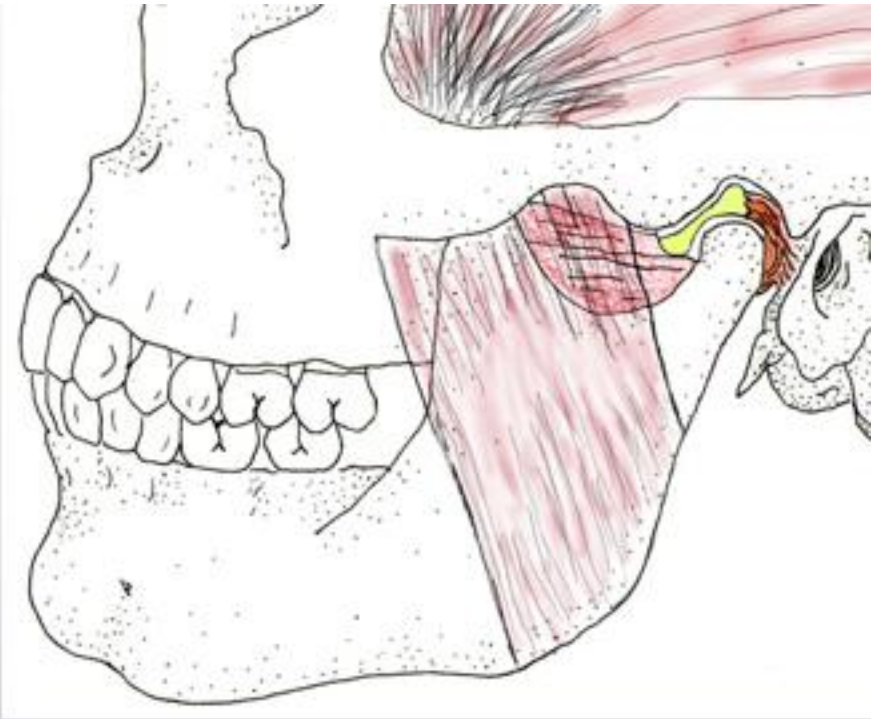

Normal Joint with Normal Occlusion

All teeth touch evenly with condyles seated in fossa

What happens to the occlusion if
the disc is dislocated?

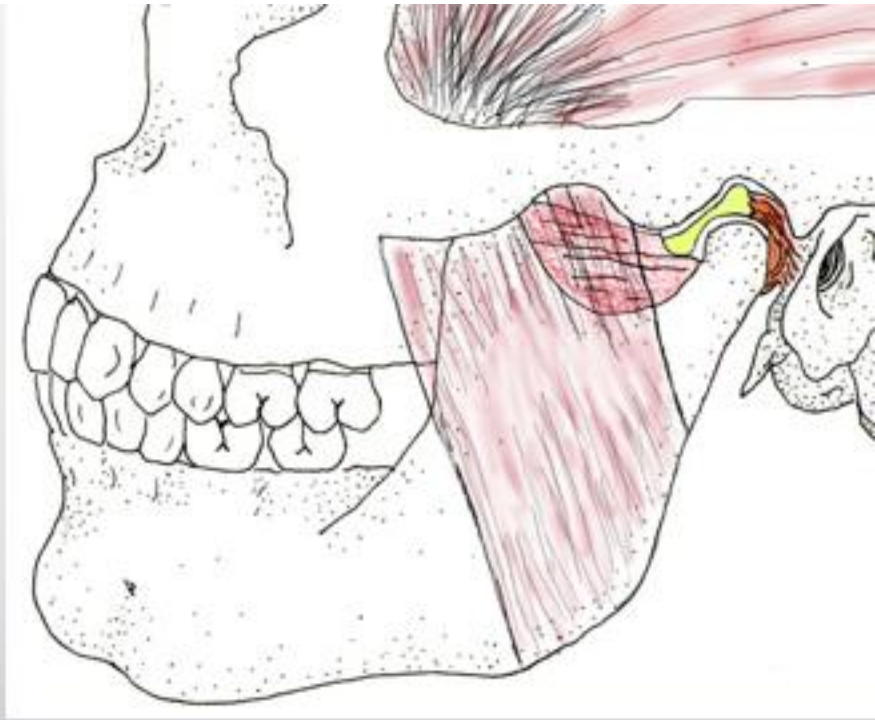

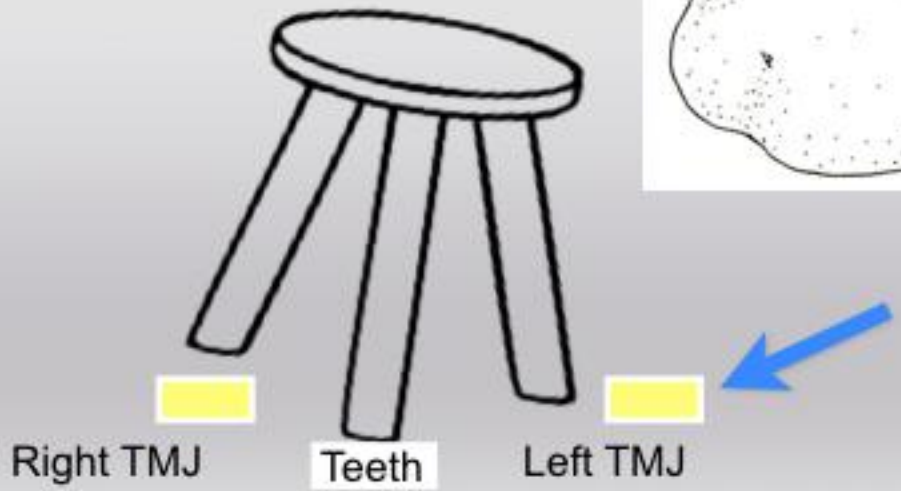

Damaged Joint with Malocclusion

All teeth touch evenly with condyles seated in fossa

What happens to the occlusion if the disc is dislocated?

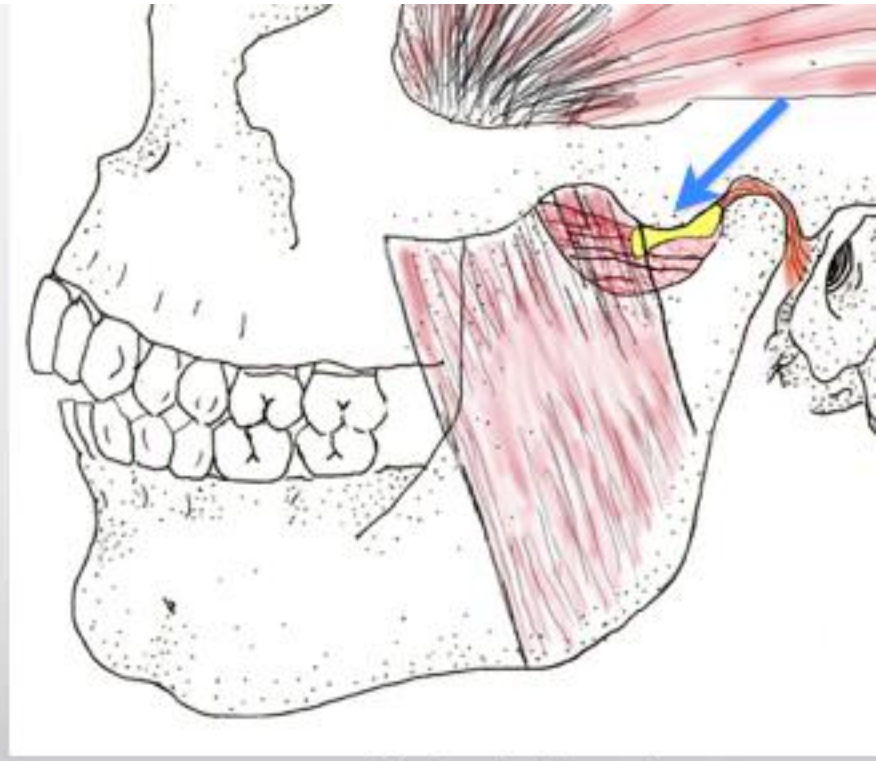

Contact of most posterior tooth

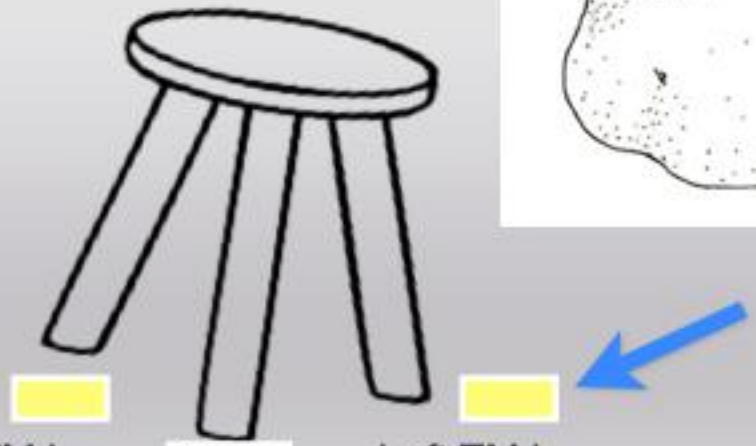

Damaged Joint with Malocclusion

85% damaged joints adapt favorably with respect to the TMJ.

Anteriorly Dislocated Disc, Mandible shifts:
Inadequate Anterior Guidance
Uneven Occlusion,
CR≠MaxIC
Occlusal Muscle Disharmony develops.

Treat favorably adapted joints with OMD the same as healthy joints with OMD:
Occlusal Adjustment

CR≠MaxIC should be 2mm or less.

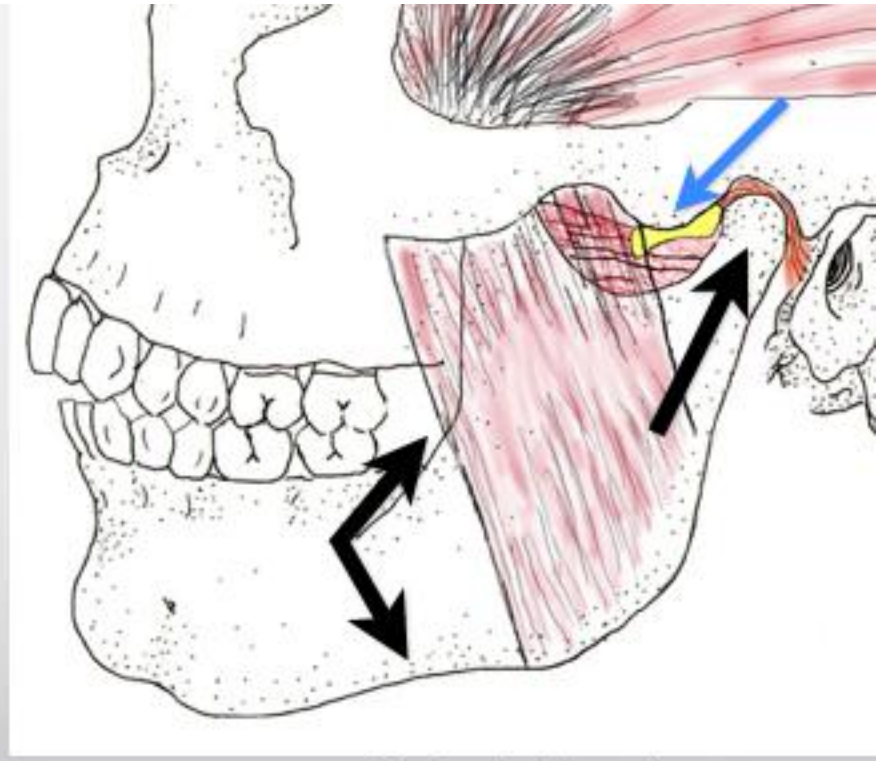

Contact of most posterior tooth

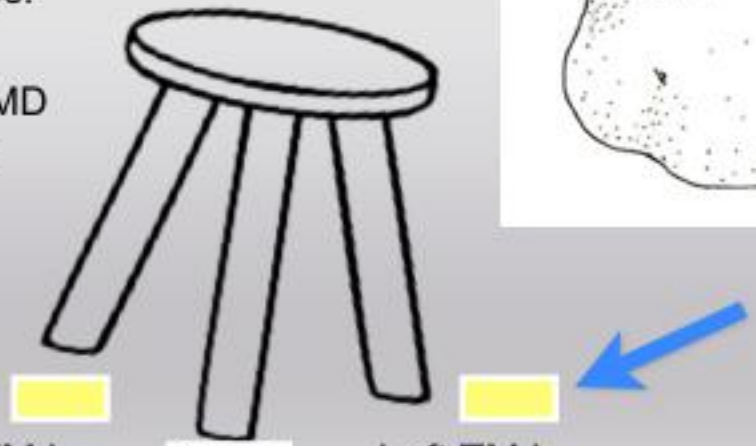

TMDs- What are the choices? (190 Diagnoses, 7 Categories)

1. TMJ Damage

Disc Dislocation

Crystal arthropathy, unspecified, TMJ
Dislocation jaw cartilage due to injury, Sequela
Dislocation jaw cartilage with reduction, favorable adaptation, TMJ
Dislocation jaw cartilage without reduction, favorable adaptation, TMJ
Effusion, TMJ

Impingement Retrodiscal Tissue
Tissue Bone Resorption, TMJ Condyle
(Joint Mice), TMJ
oplasm of bones of skull and face
MJ, Recurring
TMJ, active degeneration
e- Inactive
tis Dissecans TMJ
andibular Condyle, Active
Perforation Meniscus, TMJ
Perforation Pseudodisc, TMJ
Psoriatic Arthritis TMJ
Rheumatoid Arthritis Sero Negative TMJ

2. Muscles of the TMJ

Occlusal Muscle Disharmony

Muscle Bracing TMJ stabilization
Muscle Bracing Airway **Patency** (with Tongue)
Muscle Contracture Fibrosis Lateral Pterygoid
Muscle Contracture Fibrosis Masseter, Medial Pterygoid, Temporalis
Muscle Fatigue Overuse
Muscle Hypertrophy TMJ Muscles

3. Cranial Alignment/Occlusion

Mandible shifts: Inadequate Anterior Guidance
Uneven Occlusion, CR≠MaxIC

Malocclusion Posterior Openbite Bilateral
Malocclusion Posterior Openbite Unilateral
Malocclusion unspecified

Tooth Supereruption

4. Cervical Damage

Cervical Vertebrae Alignment Dysfunction
Cervicocranial Syndrome
Muscle Guarding due Neck Instability
Trigger Point Neck Muscle with Referred Pain
Trigger Point Neck Muscle, Localized Pain

5. Parafunction

Excessive Tooth Wear, Damage
Hypersensitive Occlusion
Parafunction clech/grind wiggle
Parafunctional Clenching Teeth, Awake
Parafunctional Clenching Teeth, Sleep
Parafunctional Grinding Teeth, Awake
Parafunctional Grinding Teeth, Sleep
Parafunctional Tongue Bracing avoiding uncomfortable tooth contact
Parafunctional Tongue Bracing Neck stabilization
Parafunctional Tongue Bracing to maintain Airway
Parafunctional Tongue Bracing unknown cause

6. Whole Body / Systemic

Lyme Disease Arthritis
Magnesium Deficiency
Obstructive Sleep Apnea
Osteoporosis without current pathological fracture
Pathological Habitual Movement Pattern
Postural Disharmony Standing

Other
Otitis Ear Infection
Pain disorder exclusively related to psychological factors. Somatoform pain disorder
Pain disorder with related psychological factors

Stomatognathic System Interrelationship

A change in any one area
will affect the others

"Adaptation"

This is a **dynamic**
orthopedic System

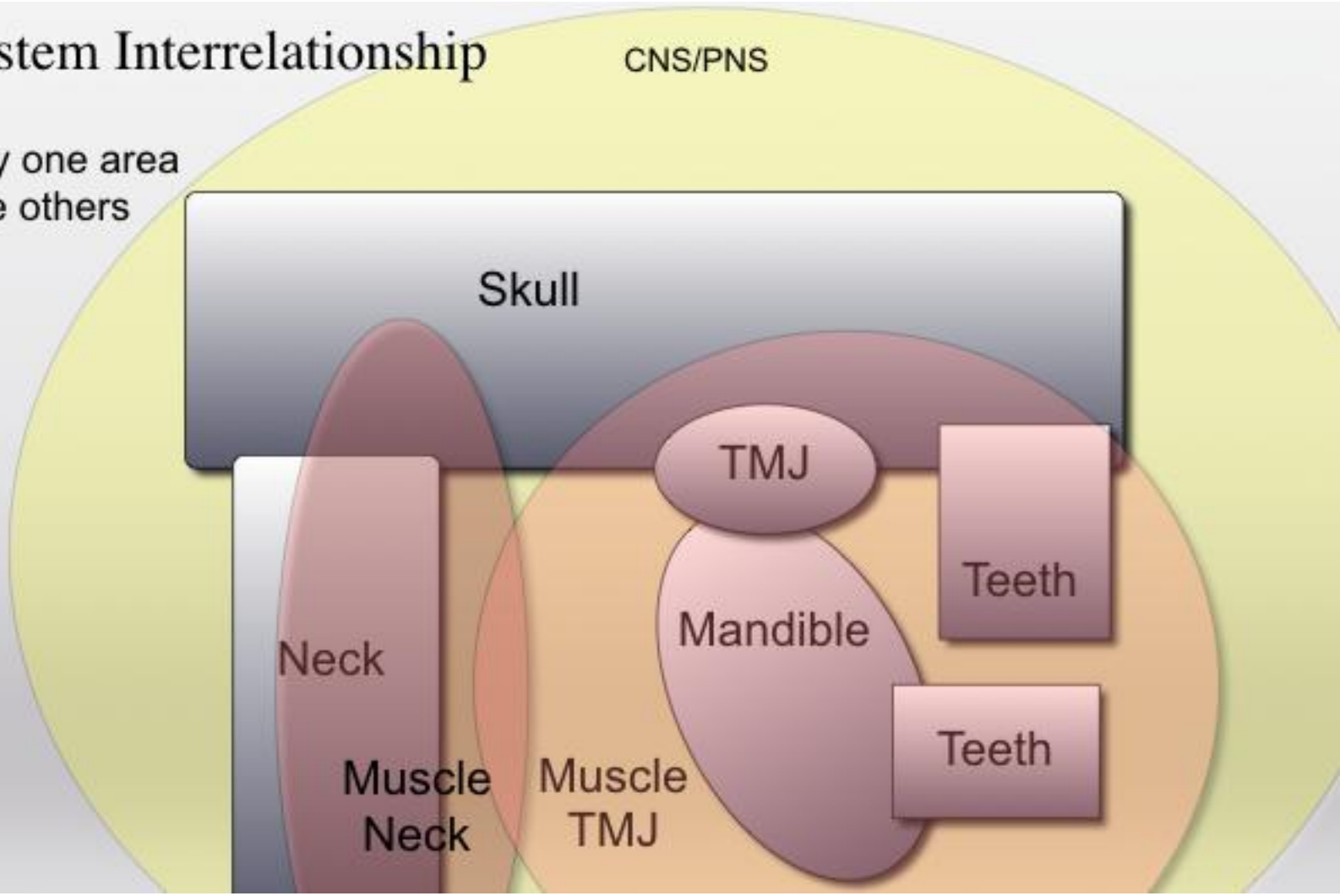

venn diagram

The Jenga Game- Big Version

How many crowns can you make out of occlusion before……

Exam and Diagnostic Tests

John R Droter DDS
Annapolis, Maryland

Short

www.jrdroter.com

Need to know which specific diagnosis goes to which specific treatments

Facial Pain- What are the choices?

TMD Myalgia as primary source of pain
Muscle Hyperactivity
Occlusal Muscle Disharmony (OMD)
Parafunction- Grinding of Teeth
Muscle Bracing, Stabilizing, Tonic Contracture
Clenching Teeth
Mechanically UnstableTMJ: Deep Temporalis, Deep Masseter
Pain Avoidance: Painful TMJ, Muscle or Teeth: Temporalis, Digastric
Tongue: Stabilize Neck, Stabilize TMJ, Occlusal Cushion
Muscle Dysfunction, Disharmony, Incoordination in movement
Muscle Weakness
Muscle Hypertrophy
Overuse Myalgia
Triggerpoints/Myofasc
Muscle Spasm

TMD other
Cervical Damage- Atlas Misalignment
Referred pain from neck muscles
Migraine Headaches- cervical/trigeminal mediated
CRPS/RSD
Neuroma
Trigeminal Neuralgia
Dystonia
Bell's Palsy

TMD Arthralgia as primary source of pain
Physical Damage to Disc & Ligaments
Osteoarthritis
Avascular Necrosis
Inflammatory Tissue Bone Resorption
Rheumatoid Arthritis
Lyme Disease
Joint Infection- Staph, Strep, Syphilis
Compromised Condylar Perfusion
Osteochondritis Dissecans
Fracture/Crush condylar head and fossa
Psoriatic Arthritis
Crystalline Deposition Diseases
Cancer TM Joint/ TM Bones
Scleroderma
Synovial Cyst

n TMD Facial Pain
cer; Head, Neck, Central
onary Artery Disease
Centrally Mediated Pain
Migraine Headaches histamine mediated
Infection: Sinuses, Ear, Teeth, Periodontal
Pulpitis
Fibromyalgia
Temporal Arteritis
Other

* This is not a complete listing of all the possibilities

Specific Diagnosis

TMD Tx- What are the choices?

TMD Myalgia as primary source of pain
Occlusal therapies
Orthodontics
Protective full coverage night guard
Anterior Stop night guard
TMJ re-adaptive appliance, 24/7 wear
Pain medication
Muscle relaxants
Triggerpoint injections
Botox
Cold Laser
Thermal Therapy
Jaw Exercises
Active Stretching
Massage

TMD other
Cervical Re-alignment
Trigger point therapies- Injections, Cold Laser
Migraine medications
Stellate ganglion block
Surgical excision nerve ending
Trigeminal Neuralgia medications
Botox block lateral pterygoid

TMD Arthralgia as primary
TMJ re-adaptive appliance, 24/7 w
NSAIDs
Doxycycline
Condylar distraction
Methotrexate
Antibiotics
TMJ surgery

Specific Treatment

* This is not a complete listing of all the possibilities

TMDs- What are the choices? (190 Diagnoses, 7 Categories)

1. TMJ Damage

Adhesions and ankylosis of temporomandibular joint
Avascular Necrosis Mandibular Condyle
Cartilage Fibrillation, Mandibular Condyle, Fossa
Closed Lock, Jaw Cartilage, Acute
Closed Lock, Jaw Cartilage, Chronic
Closed Lock, Jaw Cartilage, Intermittent, Mechanically dysfunctional
Crush Injury Mandibular Condyle
Crystal arthropathy, unspecified, TMJ
Dislocation jaw cartilage due to injury, Sequela
Dislocation jaw cartilage with reduction, favorable adaptation, TMJ
Dislocation jaw cartilage without reduction, favorable adaptation, TMJ
Effusion, TMJ
Impingement Retrodiscal Tissue
Inflammatory Tissue Bone Resorption, TMJ Condyle
Loose Body (Joint Mice), TMJ
Malignant neoplasm of bones of skull and face
Open Lock TMJ, Recurring
Osteoarthritis TMJ, active degeneration
Osteoarthrosis- Inactive
Osteochondritis Dissecans TMJ
Osteolysis Mandibular Condyle, Active
Perforation Meniscus, TMJ
Perforation Pseudodisc, TMJ
Psoriatic Arthritis TMJ
Rheumatoid Arthritis Sero Negative TMJ

2. Muscles of the TMJ

Dystonia
Habitual posture forward mandible
Hemifacial Muscle spasm
Inhibitory Reflex Dysfunction, Periodontal Ligament Masseter Muscle
Muscle Atrophy, TMJ
Muscle Bracing Neck Stabilization
Muscle Bracing Pain Avoidance
Muscle Bracing TMJ stabilization
Muscle Bracing Airway **Patentcy** (with Tongue)
Muscle Contracture Fibrosis Lateral Pterygoid
Muscle Contracture Fibrosis Masseter, Medial Pterygoid, Temporalis
Muscle Fatigue Overuse
Muscle Hypertrophy TMJ Muscles

3. Cranial Alignment/Occlusion

Cranial Distortion / Misalignment
Hemifacial Hypoplasia
Hyper Occlusal Awareness
Iatrogenic Orthotic Damage
Malocclusion Anterior Open Bite
Malocclusion Centric occlusion MaxIC discrepancy
Malocclusion Deep Bite
Malocclusion due to mouth breathing
Malocclusion due to TMJ bone loss
Malocclusion due to tongue, lip or finger habits
Malocclusion Insufficient anterior occlusal guidance
Malocclusion lack of posterior occlusal support
Malocclusion Posterior Openbite Bilateral
Malocclusion Posterior Openbite Unilateral
Malocclusion unspecified
Malposition /Misalignment: Maxilla, Temporal Bone, Mandible
Mandibular asymmetry
Mandibular hyperplasia
Mandibular hypoplasia
Mandibular Retrognathia
Maxillary asymmetry
Maxillary hyperplasia
Maxillary hypoplasia
Maxillary Retrognathia
Occlusal Adaptation, Favorable
Occlusal Dependency for Joint Stabilization/ Proprioception
Tooth Intrusion
Tooth Supereruption

4. Cervical Damage

Cervical Vertebrae Alignment Dysfunction
Cervicocranial Syndrome
Muscle Guarding due Neck Instability
Trigger Point Neck Muscle with Referred Pain
Trigger Point Neck Muscle, Localized Pain

5. Parafunction

Excessive Tooth Wear, Damage
Hypersensitive Occlusion
Parafunction clech/grind wiggle
Parafunctional Clenching Teeth, Awake
Parafunctional Clenching Teeth, Sleep
Parafunctional Grinding Teeth, Awake
Parafunctional Grinding Teeth, Sleep
Parafunctional Tongue Bracing avoiding uncomfortable tooth contact
Parafunctional Tongue Bracing Neck stabilization
Parafunctional Tongue Bracing to maintain Airway
Parafunctional Tongue Bracing unknown cause

6. Whole Body / Systemic

Lyme Disease Arthritis
Magnesium Deficiency
Obstructive Sleep Apnea
Osteoporosis without current pathological fracture
Pathological Habitual Movement Pattern
Postural Disharmony Standing
Postural Disharmony Walking
Postural Forward Head Position
Upper Airway Resistance, UARS

7. Other

Nerve Entrapment Masseteric Nerve due to Masseteric hypertonicity
Neuroma Trigeminal Nerve
Obsessive-Compulsive Personality Disorder
Other
Otitis Ear Infection
Pain disorder exclusively related to psychological factors. Somatoform pain disorder
Pain disorder with related psychological factors
Retrohead Scarification

Diagnostic Boxes:
Diagnosis is Pattern Recognition

Other

The Patterns come from:

History, Observations, Exam and Diagnostic Tests

The Diagnostic Process

When diagnosing and treating facial pain, we have entered the world of medicine.

Think!!

Differential Diagnosis
All the choices

Diagnostic tests (Observations)
Narrow down the choices

Working Diagnosis
Treating as if

Not completely resolved

Final Diagnosis
Only after problem resolved

Always make a differential diagnostic list
Ask, " It appears to be this, but what else could it be?
Be aware you are blinded by your beliefs

Facial Pain Diagnosis

Diagnostic Tools

1 Written and Oral History
2 Observation
3 Physical Exam
   Muscle Palpation
   Joint Palpation
   Joint Auscultation
   Joint Motion
4 Dx Orthotic- D-PAS
5 Sleep Airway Screening
6 CT Scan
7 MRI

Occlusion: CR Mounted Study Models
Complete Dental Exam
Clinical Photographs
Dx Blocks
Blood test
Dx Orthotics- Brux Checker, CR Orthotic

<u>Biometrics</u>
Joint Vibration
Jaw Tracker
Electromyography
T-Scan

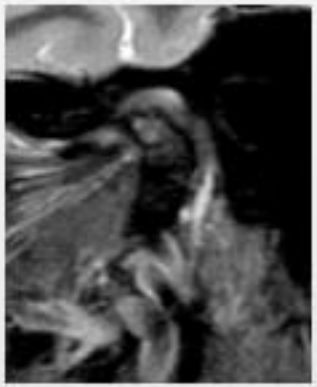

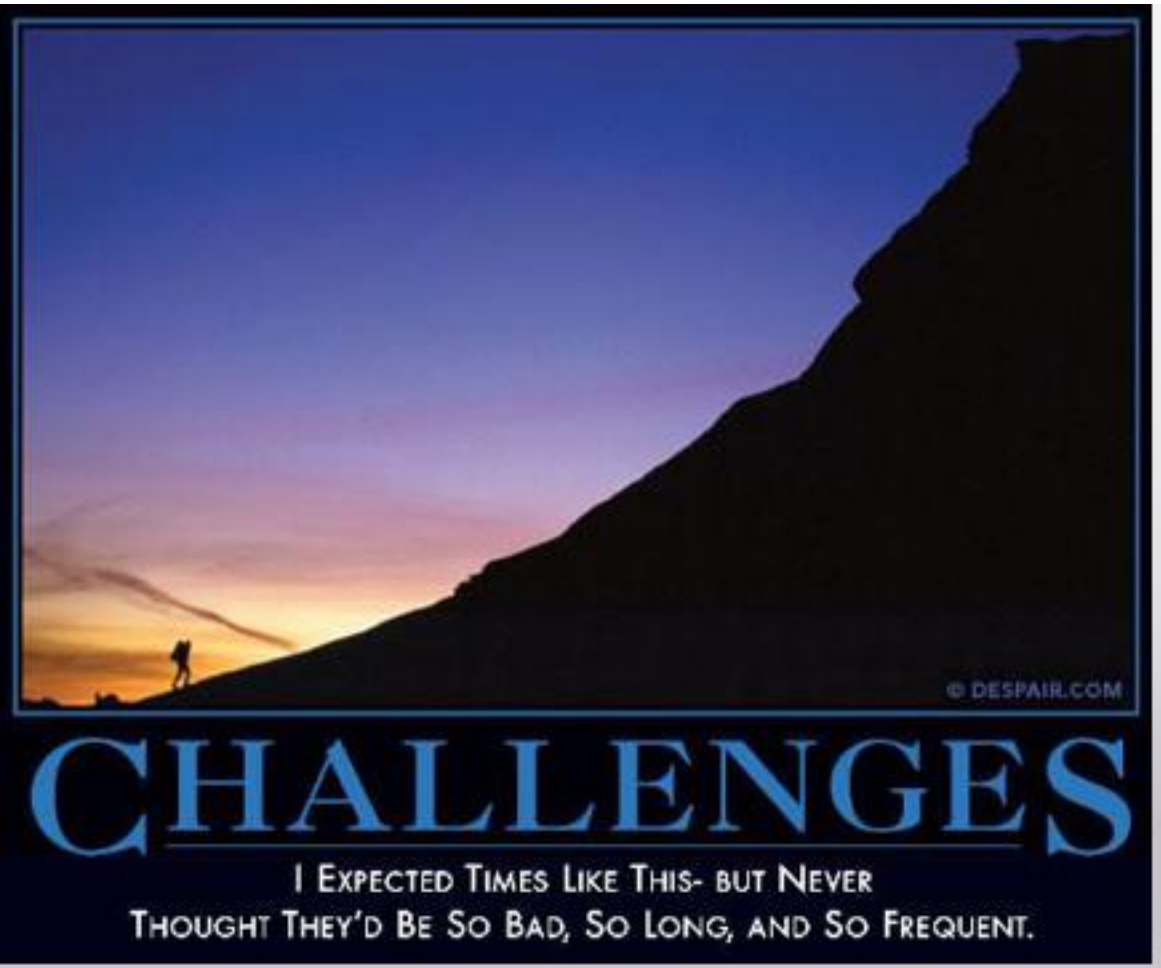

despair.com

Don't **Despair**, you have choices:

Pretend is does not matter
or
Begin to learn a few new exam skills, a few diagnostic patterns, a few new treatments. Have a box called other.

Sleep Clenching

Osteoarthritis

Acute Sprain of TMJ

Occlusal Muscle Disharmony

Upper Airway Resistance

Other

Facial Pain Diagnosis

Diagnostic Tools

1 Written and Oral History
2 Observation
3 Physical Exam
   Muscle Palpation
   Joint Palpation
   Joint Auscultation
   Joint Motion
4 Dx Orthotic- D-PAS
5 Sleep Airway Screening
6 CT Scan
7 MRI

Occlusion: CR Mounted Study Models
Complete Dental Exam
Clinical Photographs
Dx Blocks
Blood test
Dx Orthotics- Brux Checker, CR Orthotic

<u>Biometrics</u>
Joint Vibration
Jaw Tracker
Electromyography
T-Scan

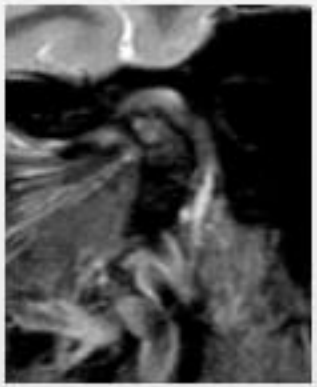

Facial Pain Diagnosis

Diagnostic Tools

1. **Written and Oral History**
2. **Observation**
3. Physical Exam
   - Muscle Palpation
   - Joint Palpation
   - Joint Auscultation
   - Joint Motion
4. Dx Orthotic- D-PAS
5. Sleep Airway Screening
6. CT Scan
7. MRI

Most Important is the history. You have a good idea of what is going from this alone.

You can also observe speech, jaw movements, neck movements, demeanor, body posture during the oral history.


Facial Problem Questionnaire

Need to resist the temptation to zero in on one diagnosis.

Still need make a Differential Diagnosis.
It appears to be ……., but what else could it be?



Facial Pain Diagnosis

While I palpate many muscles, the ones I find key are:

Diagnostic Tools

1. Written and Oral History
2. Observation
3. **Physical Exam**
   - **Muscle Palpation**
   - Joint Palpation
   - Joint Auscultation
   - Joint Motion
4. Dx Orthotic- D-PAS
5. Sleep Airway Screening
6. CT Scan
7. MRI

Anterior Temporalis
Masseter
Posterior Digastric
Superior Oblique Capitus
Deep Temporalis
Lateral Pterygoid

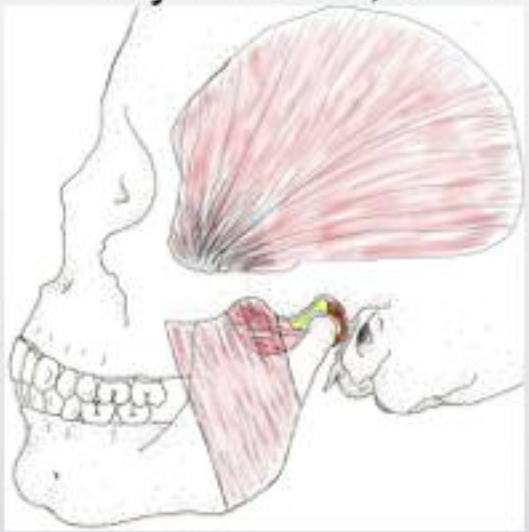

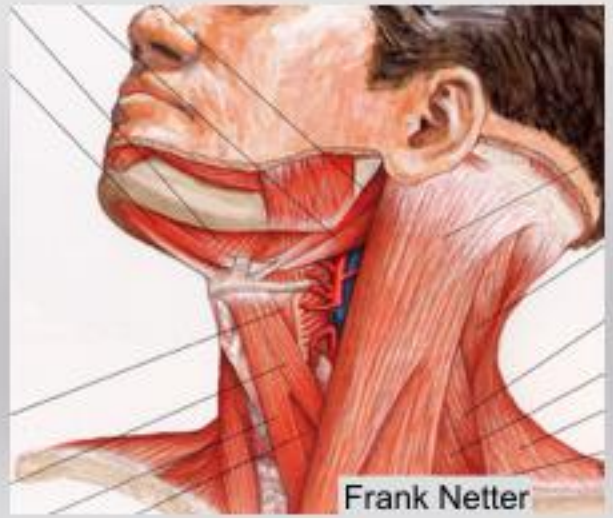

Frank Netter

Posterior view

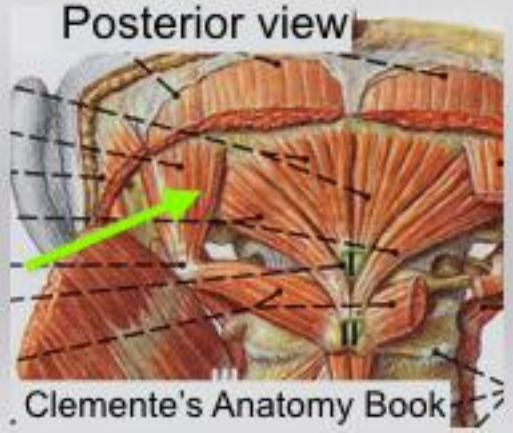

Clemente's Anatomy Book

Anatomy TV

Facial Pain Diagnosis

Diagnostic Tools

1. Written and Oral History
2. Observation
3. Physical Exam
   - Muscle Palpation
   - **Joint Palpation**
   - Joint Auscultation
   - Joint Motion
4. Dx Orthotic- D-PAS
5. Sleep Airway Screening
6. CT Scan
7. MRI

Palpation and Load

Load in CR- gradual increase pressure
Load In Excursions if negative in CR
No pain does not mean stable

Anterior Lateral Pole

Posterior Lateral Pole

Indirect through Ear

Key Question: What is sore?
Is it the joint, or is it muscle,
or both, or neither?

Facial Pain Diagnosis

Diagnostic Tools

1 Written and Oral History
2 Observation
3 Physical Exam
   Muscle Palpation
   Joint Palpation
   Joint Auscultation
   Joint Motion
4 Dx Orthotic- D-PAS
5 Sleep Airway Screening
6 CT Scan
7 MRI

A healthy joint is quiet,
A damage joint is not.
A joint that does not move is also quiet.

Sounds/ Vibrations

Stethoscope

Doppler - Landmark Healthcare 800-334-5618
Huntleigh Mini Dopplex 5hz
Great Lakes Orthodontics 800-828-7626

Joint Vibration Analysis/Jaw Tracker
BioResearch 800-251-2315

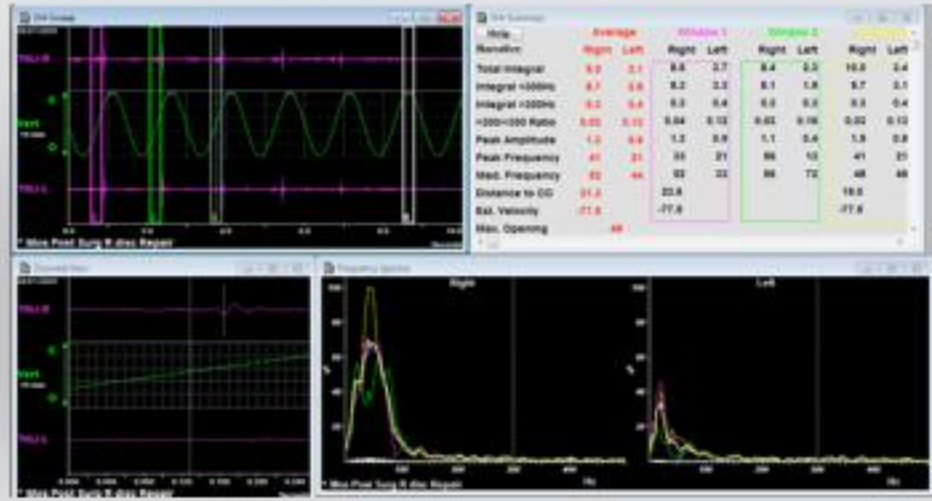

Sounds/ Vibrations
Stethoscope

Use Bell side, not Diaphragm side, over the TMJ

3M Littmann Classic II S.E. Stethoscope

My Subjective Description of Joint Sounds

smooth	fine	crackle	<u>Click</u>
paper	med	crunchy	soft
sand	coarse	squeaky	crisp
pebbles		scratch	squishy
rocks			early
glass			late
			100%
			75%
			50%
			25%
			sporadic
			??

negative joint movement
minimal joint movement

Sounds/ Vibrations
Doppler

Doppler measures motion toward or away from the source

A Health Joint is Quiet

Find Superficial Temporal Artery
Listen for Retrodiscal Expansion
  Cavernous Vein Expansion
Pin back Tragus, Aim for eye
Rapid velocity to find best location
Diagnostic velocity jaw movement

Skin Movement causes errors

Doppler only hears what occurs at lateral portion of condyle.
Small degenerated condyles are quiet.

All dopplers generate different sounds for different motions

Landmark Medical, Inc. 800-334-5618
Huntleigh Mini Dopplex 5hz
Great Lakes Orthodontics 800-828-7626

Joint Vibration Analysis

Objectively measures and quantifies joint vibrations during motion which is an indication of cartilage health

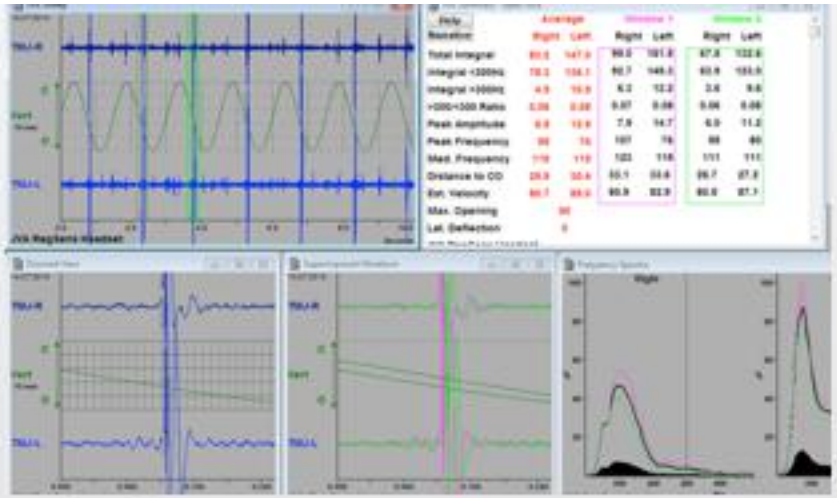

Based on Sonar.
It is not a microphone

Three main types of sounds

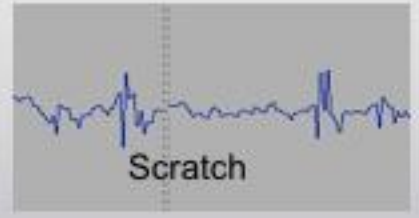

Disc Reduction
Disc Dislocation
Adhesion crackle
tooth tap

Osteoarthritis
Pseudo Disc
Damaged Cartilage

Disc Subluxation
Joint Subluxation
Disc Reduction
Disc Dislocation

JVA measures the health of the cartilage

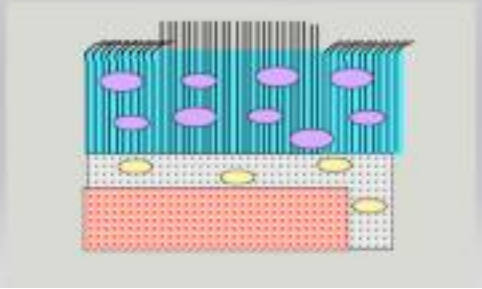

Healthy or Damaged?

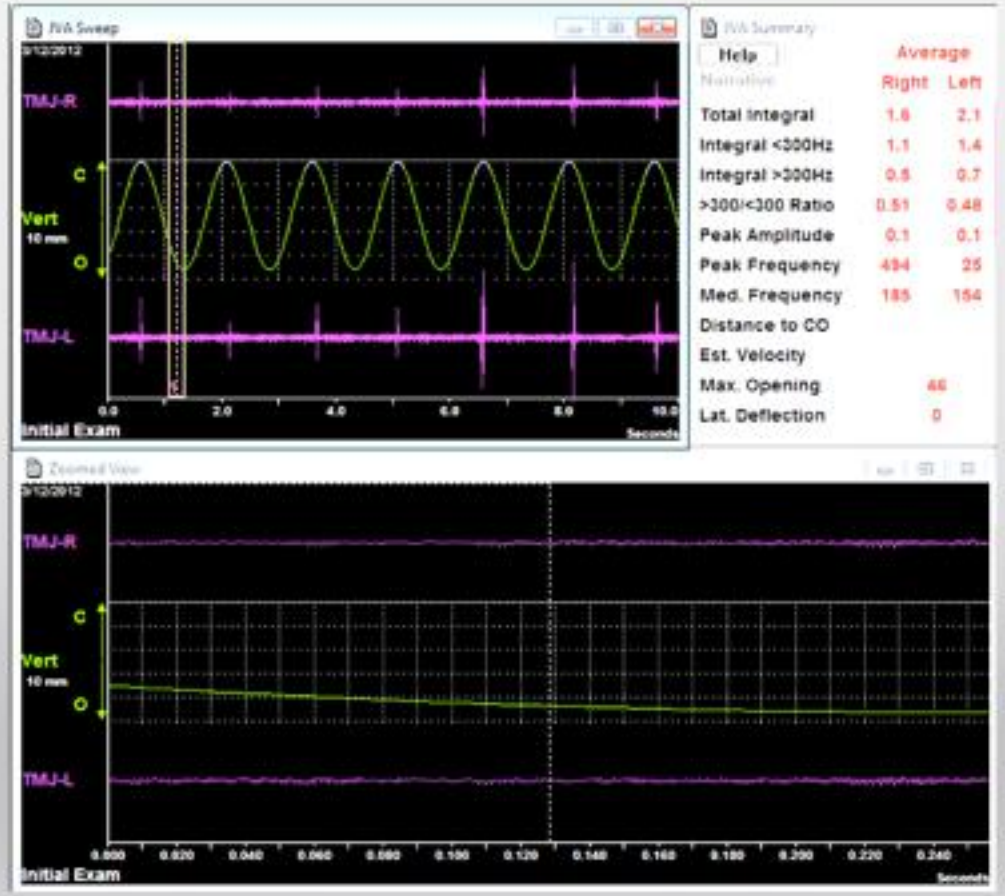

Healthy or Damaged?

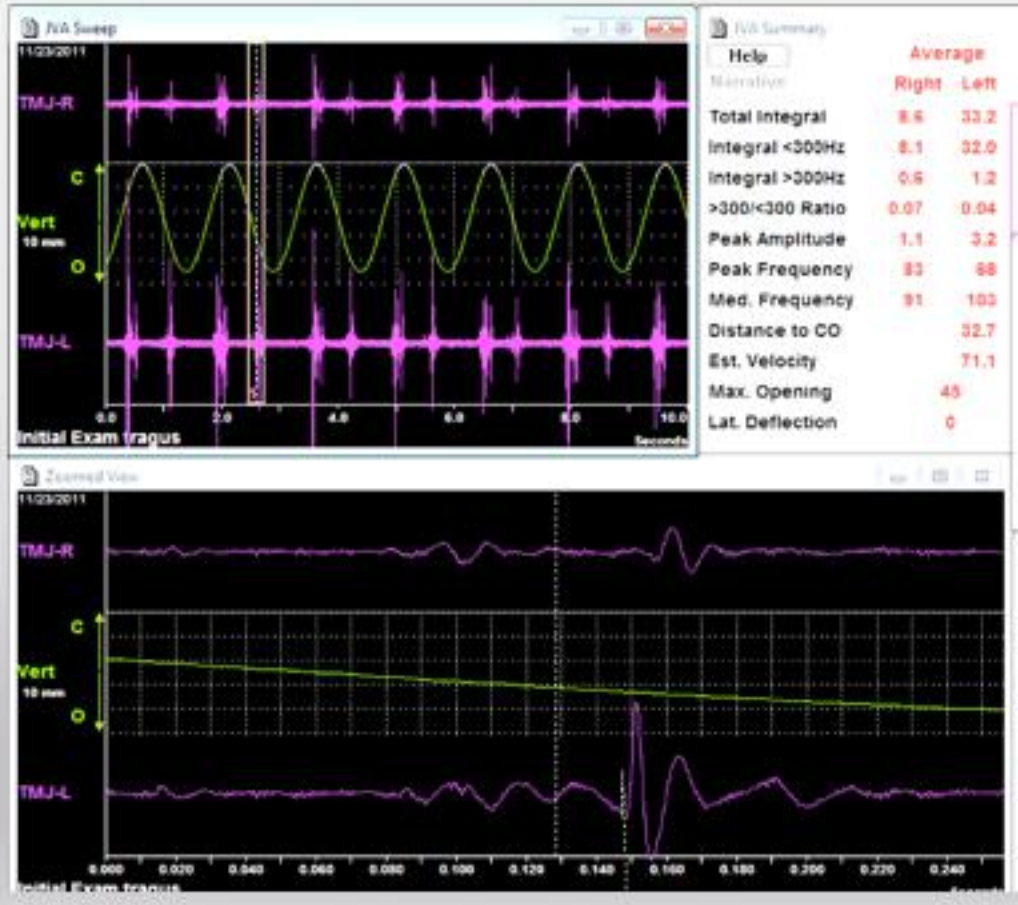

Facial Pain Diagnosis

Diagnostic Tools

1. Written and Oral History
2. Observation
3. Physical Exam
   - Muscle Palpation
   - Joint Palpation
   - Joint Auscultation
   - **Joint Motion**
4. Dx Orthotic- D-PAS
5. Sleep Airway Screening
6. CT Scan
7. MRI

Evaluate for Full, Smooth Range of Motion

40-55 mm, 300mm/sec velocity, straight path, consistent arc

Take 4 Measurements:

Maximum Opening	40-55mm
Right Lateral	10-12mm
Left Lateral	10-12mm
Protrusive	10-12mm

38+4 indicates 38mm edge to edge plus 4mm overbite for a total of 42mm

Normal excursion are 25% of the max open

Evaluate Smoothness:
Light hold on chin as patient moves jaw

Therabite, 1-800-217-0025
www.therabite.com

Facial Pain Diagnosis

Diagnostic Tools

1. Written and Oral History
2. Observation
3. Physical Exam
   - Muscle Palpation
   - Joint Palpation
   - Joint Auscultation
   - Joint Motion
4. **Dx Orthotic- D-PAS**
5. Sleep Airway Screening
6. CT Scan
7. MRI

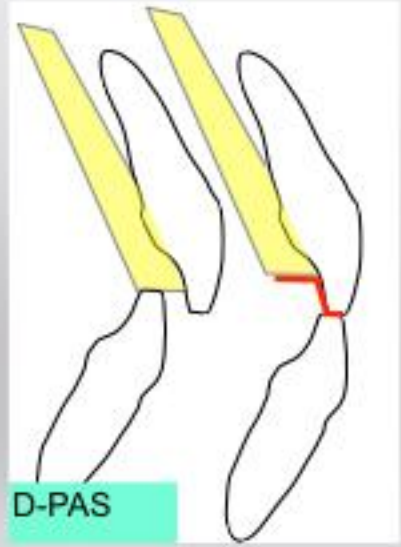

Biomechanics of Anterior Stop Orthotic

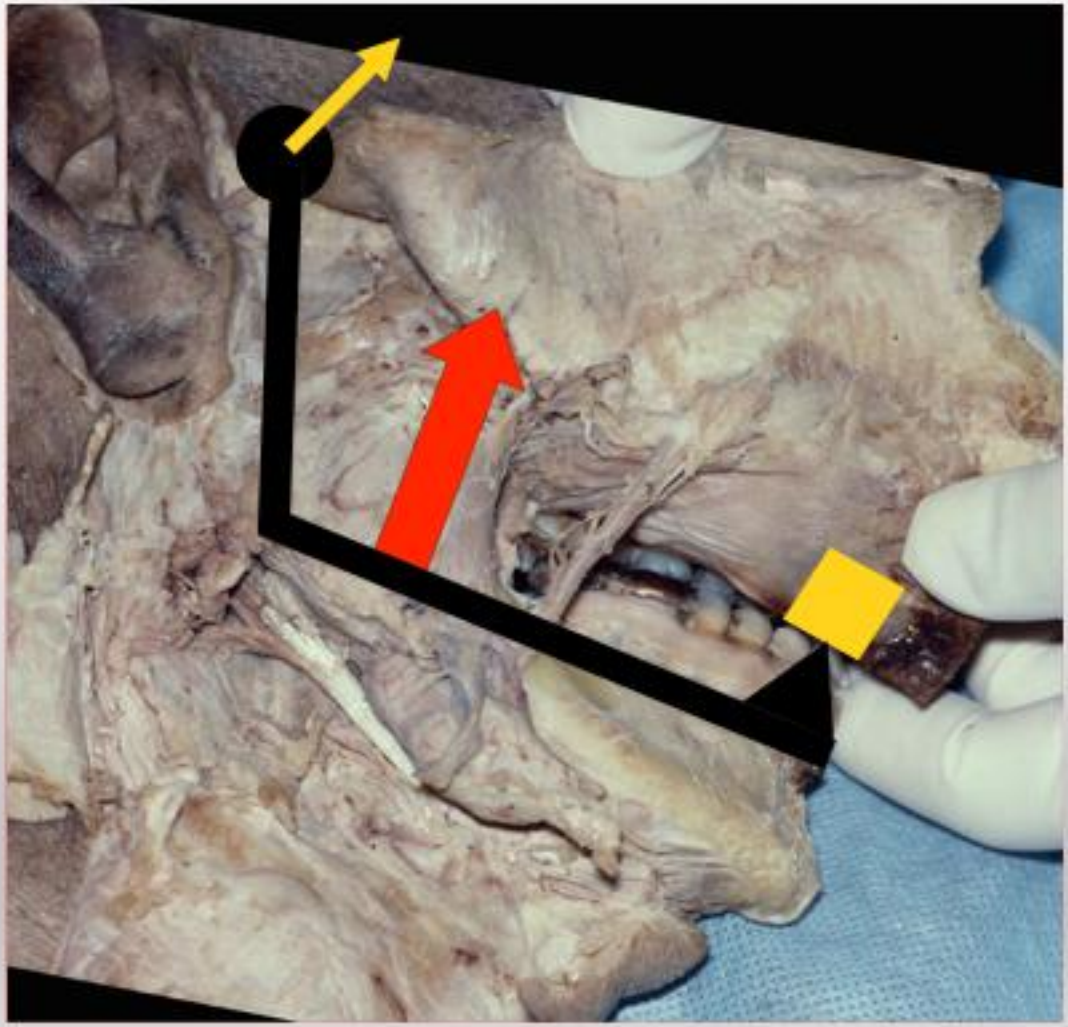

Are the TMJ muscles inhibited from full contraction with anterior only tooth contact?

Detect with EMG or muscle palpation- Clench full power on posterior teeth and then with D-PAS orthotic.

Diagnostic
Palatal Anterior Stop
Orthotic

Patient with muscles
<u>inhibited by anterior only contact</u>

	Clench MaxIC	Anterior Stop D-PAS
	µV	µV
TA-R	100.6	15.7
TA-L	108.9	25.3
MM-R	115.4	25.5
MM-L	70.5	6.8

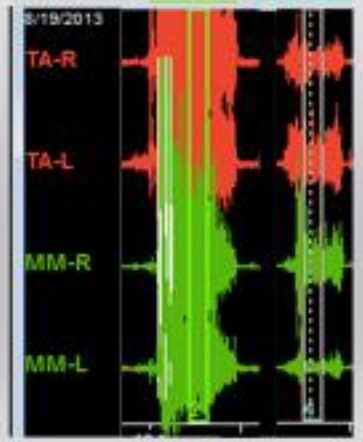

Major decrease in muscle power with D-PAS

Another Patient with muscles NOT
<u>inhibited by anterior only contact</u>

	Clench MaxIC	Anterior Stop D-PAS
	µV	µV
TA-R	82.2	77.9
TA-L	124.6	103.6
MM-R	185.0	169.0
MM-L	79.9	86.6

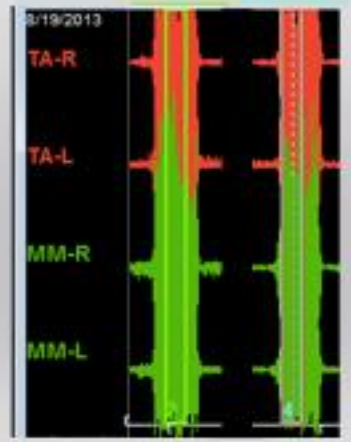

Muscle power same with D-PAS

Anterior Deprogrammer
Anterior Stop Orthotic

Common Actions to all Anterior Deprogrammers:
- Only anterior teeth contact in MaxIC
- Load/seat condyles
- Eliminate immediate posterior interferences

Wear 10- 15 min in Office

Wear Nighttime

Can wear Nighttime and Daytime
24 hour wear no longer than 1 week

Upper Anterior Deprogrammer

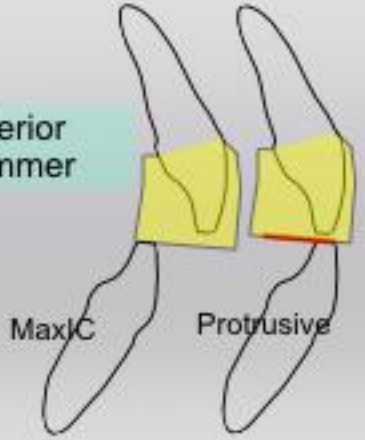

Lower Anterior Deprogrammer

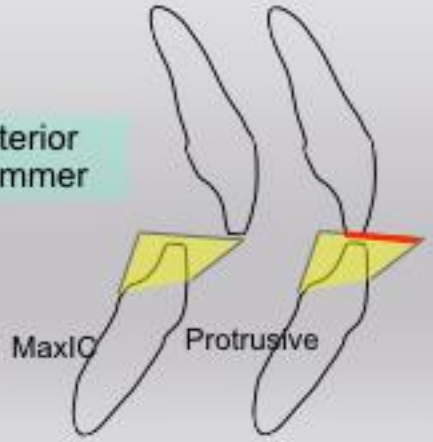

My Top Choice
"D-PAS"

Palatal Anterior Stop Orthotic

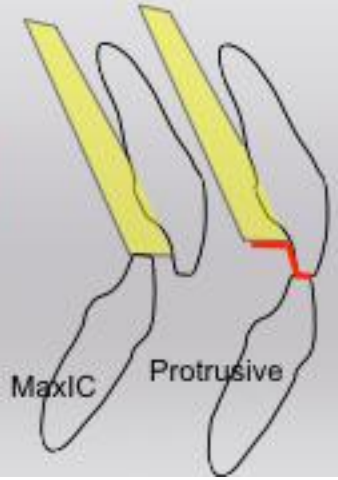

This is a diagnostic test first and foremost

D-PAS: Diagnostic Palatal Anterior Stop Orthotic

Sleep Clenching: Wear during sleep for 1 week,
Decrease muscle pain.

Occlusal Muscle Disharmony: Wear 24/7 for 2 days,
Further decrease muscle pain.

Mechanically Unstable TMJ: Wear during sleep or day,
Increase muscle pain.

Intracapsular Problem TMJ: Wear during sleep,
Increase joint pain.

Lack of Masseter Muscle Inhibition:
Full power on clenching.

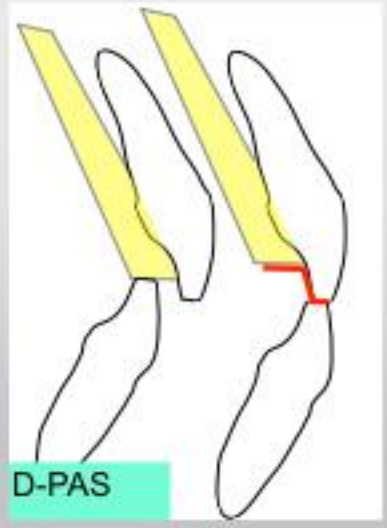

Quick to make, no mounted models.

Very Esthetic. Not Visible. Good Compliance

Facial Pain Diagnosis

Diagnostic Tools

1. Written and Oral History
2. Observation
3. Physical Exam
   - Muscle Palpation
   - Joint Palpation
   - Joint Auscultation
   - Joint Motion
4. Dx Orthotic- D-PAS
5. **Sleep Airway Screening**
6. CT Scan
7. MRI

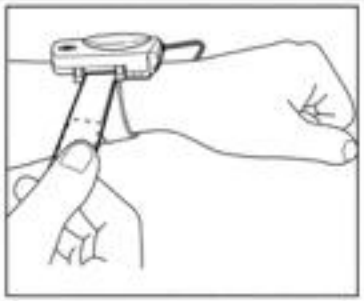

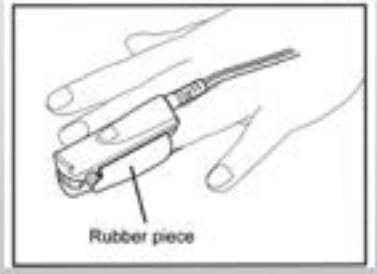

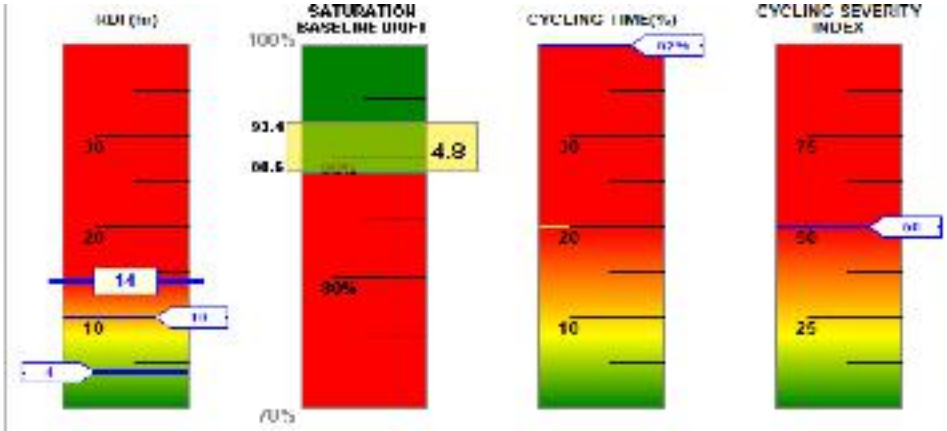

–Desaturations associated with Early Motion are Excluded in these calculations.
–Physician should review the waveform and consider reviewing the report without the above exclusions.

PATTERN BASED REPORT

OXYGEN SATURATION BASELINE ANALYSIS	
Oxygen Saturation Baseline Drift(OSBG) [normal <= 3]	3
Initial Saturation Baseline	93
Lowest Saturation Baseline	89
Highest Saturation Baseline	93

Baseline is determined by the Mean Spo2 during 3 Minute window without Artifact and without Events.

SPO2 CYCLING		
% Time in Cycling (Duration)	32%	(02:50:14)
Cycling Frequency	45	
96% - Lowest Sat	12	
Cycling Severity Index	50	

The total time oxygen saturation was <= 88% was 00:13:39

TRADITIONAL REPORT

ODI4:	11
Total ODI4 Events:	58
Time in ODI4 Events:	00:29:26
Avg ODI4 Event Duration:	00:00:28
<=88% ODI4 Events:	25
<=88% Longest Duration:	00:01:21
Minimum SpO2:	84
Avg Low 10% SpO2:	86
Avg Low SpO2:	89
Avg Low SpO2 <=88%:	87

Definition of ODI4 Event: a fall in oxygen saturation of at least 4% and persisting greater than 5 seconds.

%SpO2	DURATION	%TOTAL
94-100	00:16:37	5%
88-94	04:57:26	91%
80-88	00:13:39	4%
70-80	00:00:00	0%
<= 70	00:00:00	0%
Total	05:27:42	100%
Motion Artifact	00:00:07	0.04%
Error Signal	00:00:05	0.03%

4. If sleep grinding, is there an airway issue?
(Upper Airway Resistance or Obstructive Sleep Apnea)

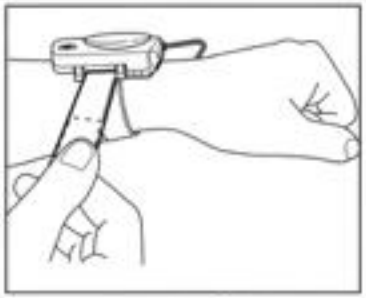

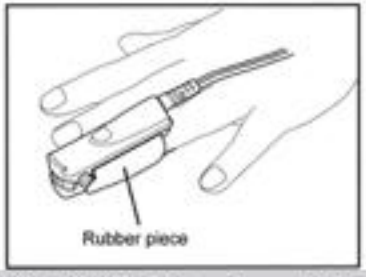

High Resolution
Pulse Oximetry

Data every 1
second average
over 3 seconds

PULSOX 300i, Konica Minolta
with data analysis Patient Safety, Inc.

Order PULSOX: Go to my website
jrdroter.com ….. Doctor Links

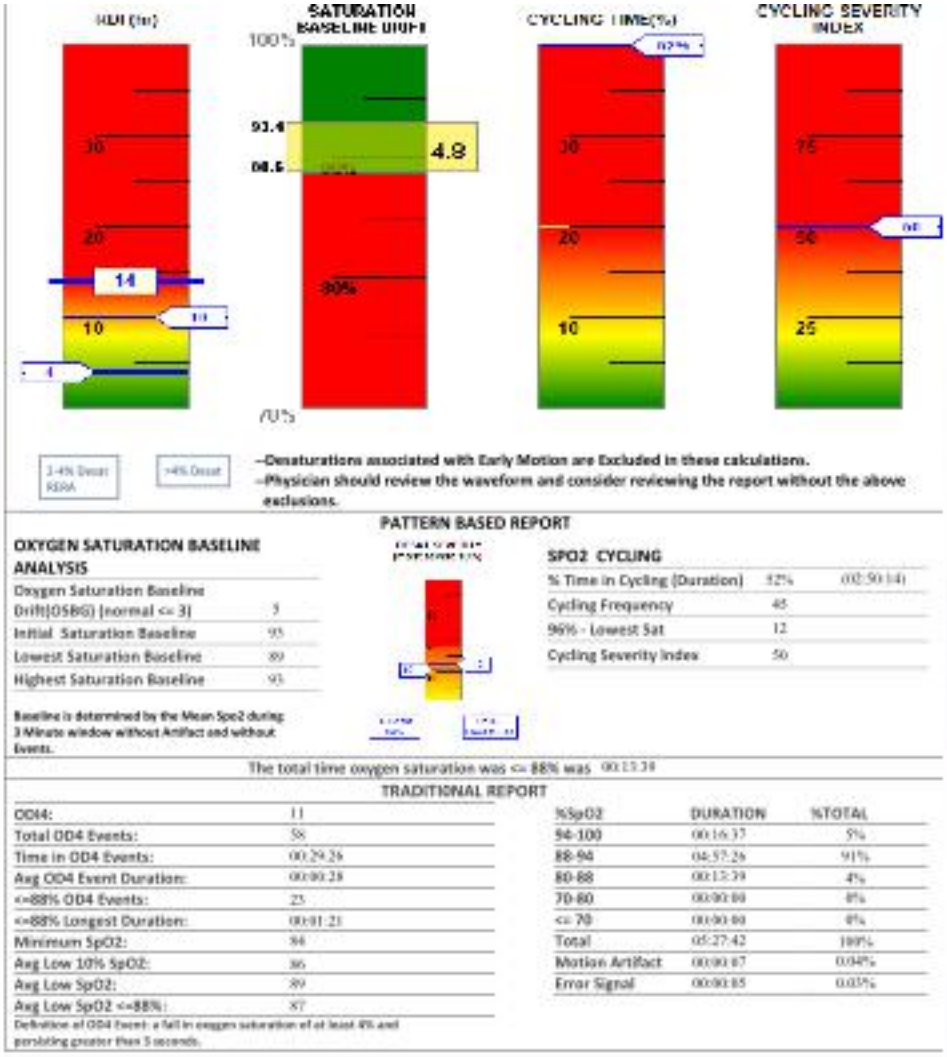

5. Does the dental orthotic make the airway better or worse?

RDI= Respiratory Distress Index

Sometimes D-PAS makes airway better, sometimes worse

No dental orthotic
RDI = 3

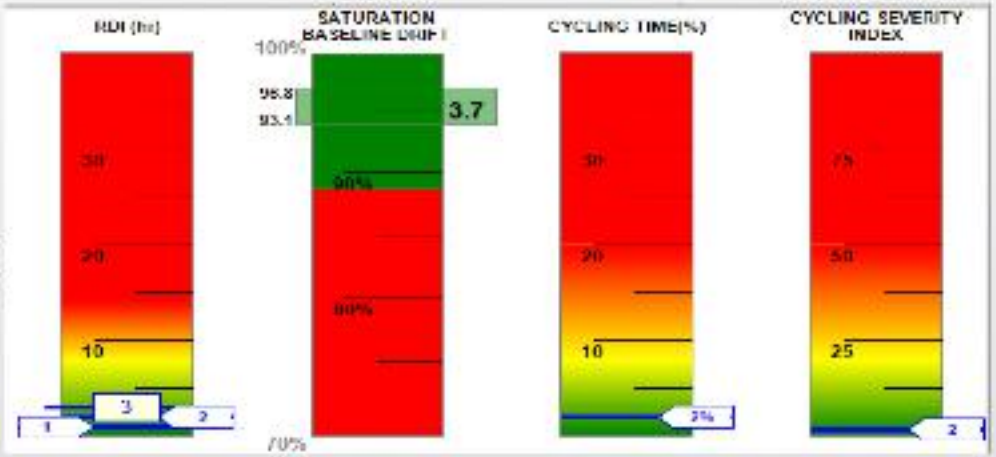

Dental Orthotic:
Anterior Stop: D-PAS
RDI =10

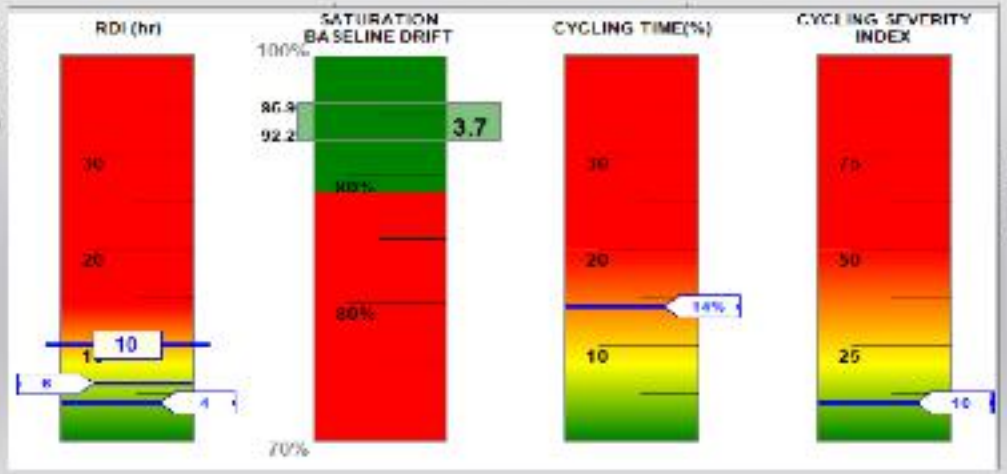

High Resolution Pulse Oximetry

PULSOX 300i, Konica Minolta with data analysis Patient Safety, Inc.

Facial Pain Diagnosis

Diagnostic Tools

1. Written and Oral History
2. Observation
3. Physical Exam
   - Muscle Palpation
   - Joint Palpation
   - Joint Auscultation
   - Joint Motion
4. Dx Orthotic- D-PAS
5. Sleep Airway Screening
6. **CT Scan**
7. MRI

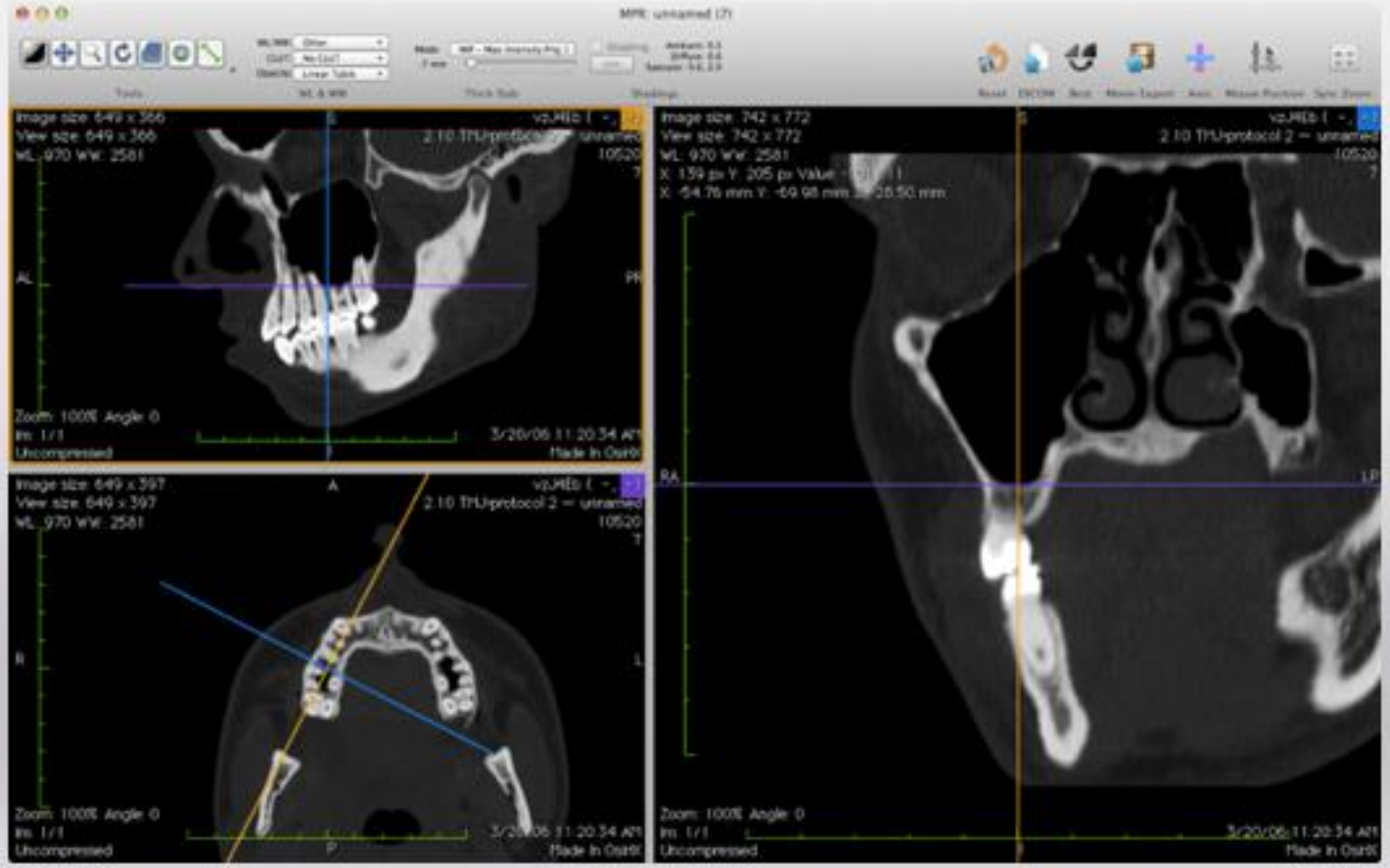

Normal TMJ- Bone

CT Scan
Coronal View

Bone Density

- Intact Cortex
- Even pattern Trabecular bone

Normal Size/Shape Condyle/Fossa

- Ovoid Condylar Shape
- Non-Congruent Condyle/Fossa
- Condyle 70% Size Fossa

Condyle Centered in Fossa

- Coronal and Sagittal
- Room for Disc

Stable CR load Zone

- Condyle closest to fossa

CT Scan
Sagittal View

Would you do full mouth rehabilitation with only a set of bitewing radiographs?

If you need to see all of the tooth surfaces,
why would you not want to see all of the TMJ surfaces?

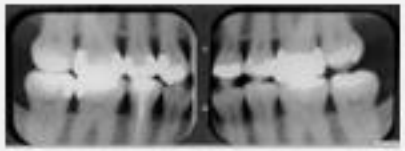

FMX, PanX

FMX, CBCT

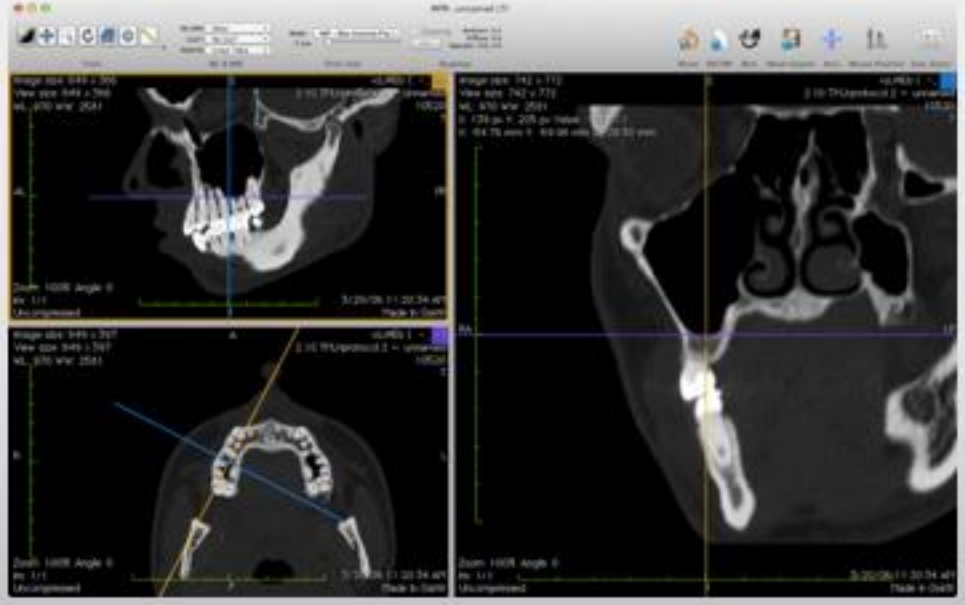

CBCT, 7 vertical BW

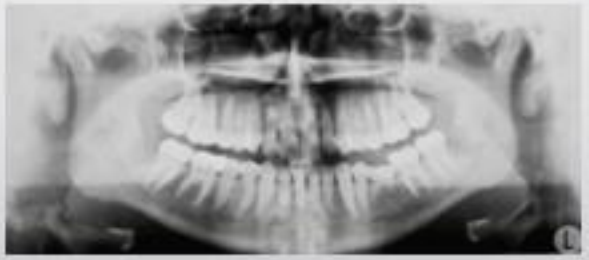



2.5x more PAP found With CBCT

Patel S, Wilson R, Dawood A, Mannocci F., Detection of periapical pathology using intraoral radiography and cone beam computed tomography - a clinical study. Int Endod J. 2011 Dec 21

Differential Diagnosis: Changes in Joint Height

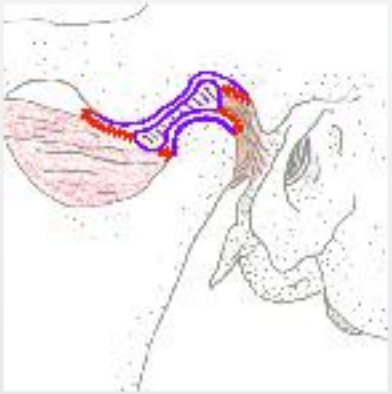

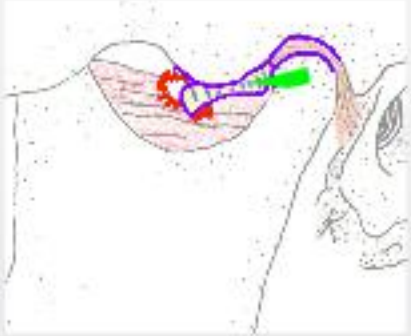

Lose of Bone**
- Osteoarthritis
- AVN
- TIBR
- RhA
- Lyme Arthritis
- Psoriatic Arthritis

Decrease Tissue Thickness
- Acute Piper 4

Bone Growth
- Condylar Hyperplasia

Tissue Growth
- Synovial Hyperplasia

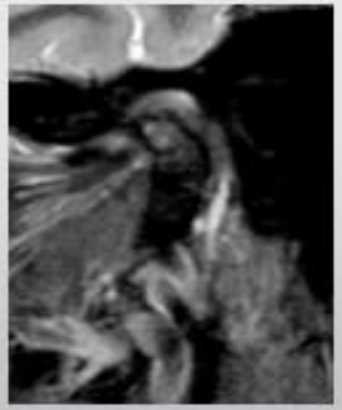

Inflamed tissue in joint

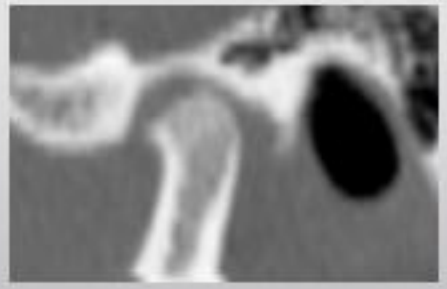

Missing cortex

OA cyst

**Notice that loss of bone and sore TMJs have similar diseases

Facial Pain Diagnosis

Diagnostic Tools

1. Written and Oral History
2. Observation
3. Physical Exam
   - Muscle Palpation
   - Joint Palpation
   - Joint Auscultation
   - Joint Motion
4. Dx Orthotic- D-PAS
5. Sleep Airway Screening
6. CT Scan
7. **MRI**

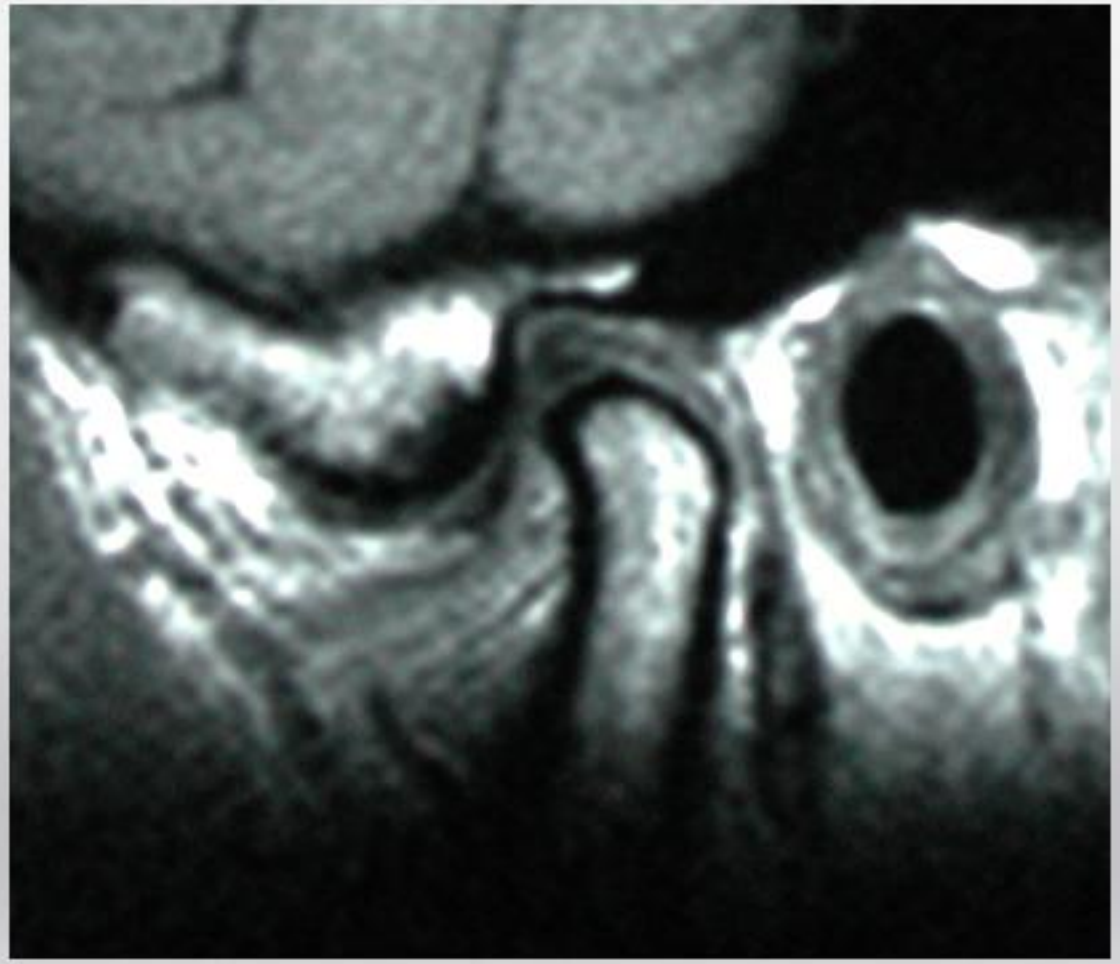

T1 Inverted

T1 Sagittal Closed

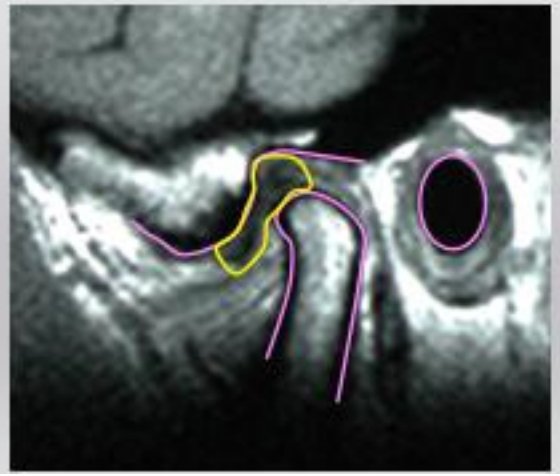

MRI STIR Image

STIR- Short T1 Inversion Recovery

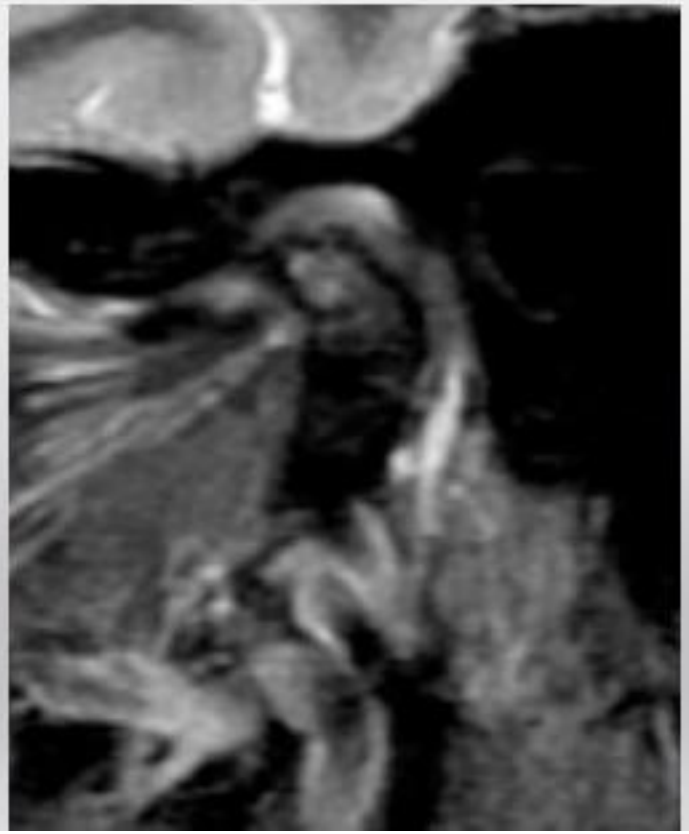

STIR- "Supercharged" T2

Retrodiscal Inflammation

Marrow Edema

Diff Dx is active AVN, Osteoarthritis, Lyme Ds, RhA, Hypoxic Progressive Condylar Resorption

STIR and T2 shows water as white

Facial Pain Diagnosis

Diagnostic Tools

1 Written and Oral History
2 Observation
3 Physical Exam
   Muscle Palpation
   Joint Palpation
   Joint Auscultation
   Joint Motion
4 Dx Orthotic- D-PAS
5 Sleep Airway Screening
6 CT Scan
7 MRI

Occlusion: CR Mounted Study Models
Complete Dental Exam
Clinical Photographs
Dx Blocks
Blood test
Dx Orthotics- Brux Checker, CR Orthotic

<u>Biometrics</u>
Joint Vibration
Jaw Tracker
Electromyography
T-Scan

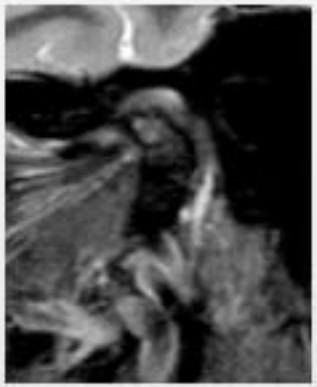

You should now be able to answer:

What is sore?

What is dysfunctional?

Does this fit any diagnostic patterns I recognize and can treat?

Note: You do not have to do all 7 dx steps. Once you have a good differential diagnosis you can develop your working diagnosis and start treatment.

Diagnosis and Treating Common TMDs in a GP

John R Droter DDS
Annapolis, Maryland

Short

www.jrdroter.com

Treating Common TMDs

Diagnosis	Pattern	Treatment
Sleep Clenching with anterior tooth contact inhibition	Sore masseters on waking Morning TMJ clicking that resolves Sleep D-PAS Relieves Symptoms	D-PAS Night Guard Time Release Vitamin C hs
Sleep Grinding , Airway Related	Worn Teeth Upper Airway Resistance	Mandibular Advancement Appliance
Occlusal Muscle Disharmony	Sore muscles on chewing Sore Lateral Pterygoid Day D-PAS Relieves Symptoms	Occlusal Adjustment
Osteoarthritis of TMJ	Arthralgia CBCT shows worn bone loss MRI T2, STIR ++	NSAID for 6-12 weeks Occlusal Adjustment Do not put in a night guard
Sprain Discal Ligament TMJ, Acute	Sudden onset pain TMJ Pain palpation TMJ Limited opening	Cold Laser, Ice 15 min 3x a day Rest, Soft diet, NSAID 7 days Anterior Reposition Orthotic 7 days
Hypoxia Induced Progressive Condylar Resorption	Progressive anterior open bite Missing condylar cortex on CT	Condylar distraction for 6 months Meloxicam, Doxycycline

TMDs- What are the choices? (190 Diagnoses, 7 Categories)

1. TMJ Damage

Adhesions and ankylosis of temporomandibular joint
Avascular Necrosis Mandibular Condyle
Cartilage Fibrillation, Mandibular Condyle, Fossa
Closed Lock, Jaw Cartilage, Acute
Closed Lock, Jaw Cartilage, Chronic
Closed Lock, Jaw Cartilage, Intermittent, Mechanically dysfunctional
Crush Injury Mandibular Condyle
Crystal arthropathy, unspecified, TMJ
Dislocation jaw cartilage due to injury, Sequela
Dislocation jaw cartilage with reduction, favorable adaptation, TMJ
Dislocation jaw cartilage without reduction, favorable adaptation, TMJ
Effusion, TMJ
Impingement Retrodiscal Tissue
Inflammatory Tissue Bone Resorption, TMJ Condyle
Loose Body (Joint Mice), TMJ
Malignant neoplasm of bones of skull and face
Open Lock TMJ, Recurring
Osteoarthritis TMJ, active degeneration
Osteoarthrosis- Inactive
Osteochondritis Dissecans TMJ
Osteolysis Mandibular Condyle, Active
Perforation Meniscus, TMJ
Perforation Pseudodisc, TMJ
Psoriatic Arthritis TMJ
Rheumatoid Arthritis Sero Negative TMJ

2. Muscles of the TMJ

Dystonia
Habitual posture forward mandible
Hemifacial Muscle spasm
Inhibitory Reflex Dysfunction, Periodontal Ligament Masseter Muscle
Muscle Atrophy, TMJ
Muscle Bracing Neck Stabilization
Muscle Bracing Pain Avoidance
Muscle Bracing TMJ stabilization
Muscle Bracing Airway **Patency** (with Tongue)
Muscle Contracture Fibrosis Lateral Pterygoid
Muscle Contracture Fibrosis Masseter, Medial Pterygoid, Temporalis
Muscle Fatigue Overuse
Muscle Hypertrophy TMJ Muscles

3. Cranial Alignment/Occlusion

Cranial Distortion / Misalignment
Hemifacial Hypoplasia
Hyper Occlusal Awareness
Iatrogenic Orthotic Damage
Malocclusion Anterior Open Bite
Malocclusion Centric occlusion MaxIC discrepancy
Malocclusion Deep Bite
Malocclusion due to mouth breathing
Malocclusion due to TMJ bone loss
Malocclusion due to tongue, lip or finger habits
Malocclusion Insufficient anterior occlusal guidance
Malocclusion lack of posterior occlusal support
Malocclusion Posterior Openbite Bilateral
Malocclusion Posterior Openbite Unilateral
Malocclusion unspecified
Malposition /Misalignment: Maxilla, Temporal Bone, Mandible
Mandibular asymmetry
Mandibular hyperplasia
Mandibular hypoplasia
Mandibular Retrognathia
Maxillary asymmetry
Maxillary hyperplasia
Maxillary hypoplasia
Maxillary Retrognathia
Occlusal Adaptation, Favorable
Occlusal Dependency for Joint Stabilization/ Proprioception
Tooth Intrusion
Tooth Supereruption

4. Cervical Damage

Cervical Vertebrae Alignment Dysfunction
Cervicocranial Syndrome
Muscle Guarding due Neck Instability
Trigger Point Neck Muscle with Referred Pain
Trigger Point Neck Muscle, Localized Pain

5. Parafunction

Parafunctional Clenching Teeth

Parafunctional Grinding Teeth, Sleep
Parafunctional Tongue Bracing avoiding uncomfortable tooth contact
Parafunctional Tongue Bracing Neck stabilization
Parafunctional Tongue Bracing to maintain Airway
Parafunctional Tongue Bracing unknown cause

6. Whole Body / Systemic

Lyme Disease Arthritis
Magnesium Deficiency
Obstructive Sleep Apnea
Osteoporosis without current pathological fracture
Pathological Habitual Movement Pattern
Postural Disharmony Standing
Postural Disharmony Walking
Postural Forward Head Position
Upper Airway Resistance, UARS

7. Other

Nerve Entrapment Masseteric Nerve due to Masseteric hypertonicity
Neuroma Trigeminal Nerve
Obsessive-Compulsive Personality Disorder
Other
Otitis Ear Infection
Pain disorder exclusively related to psychological factors. Somatoform pain disorder
Pain disorder with related psychological factors
Retrohyoid Sensitization

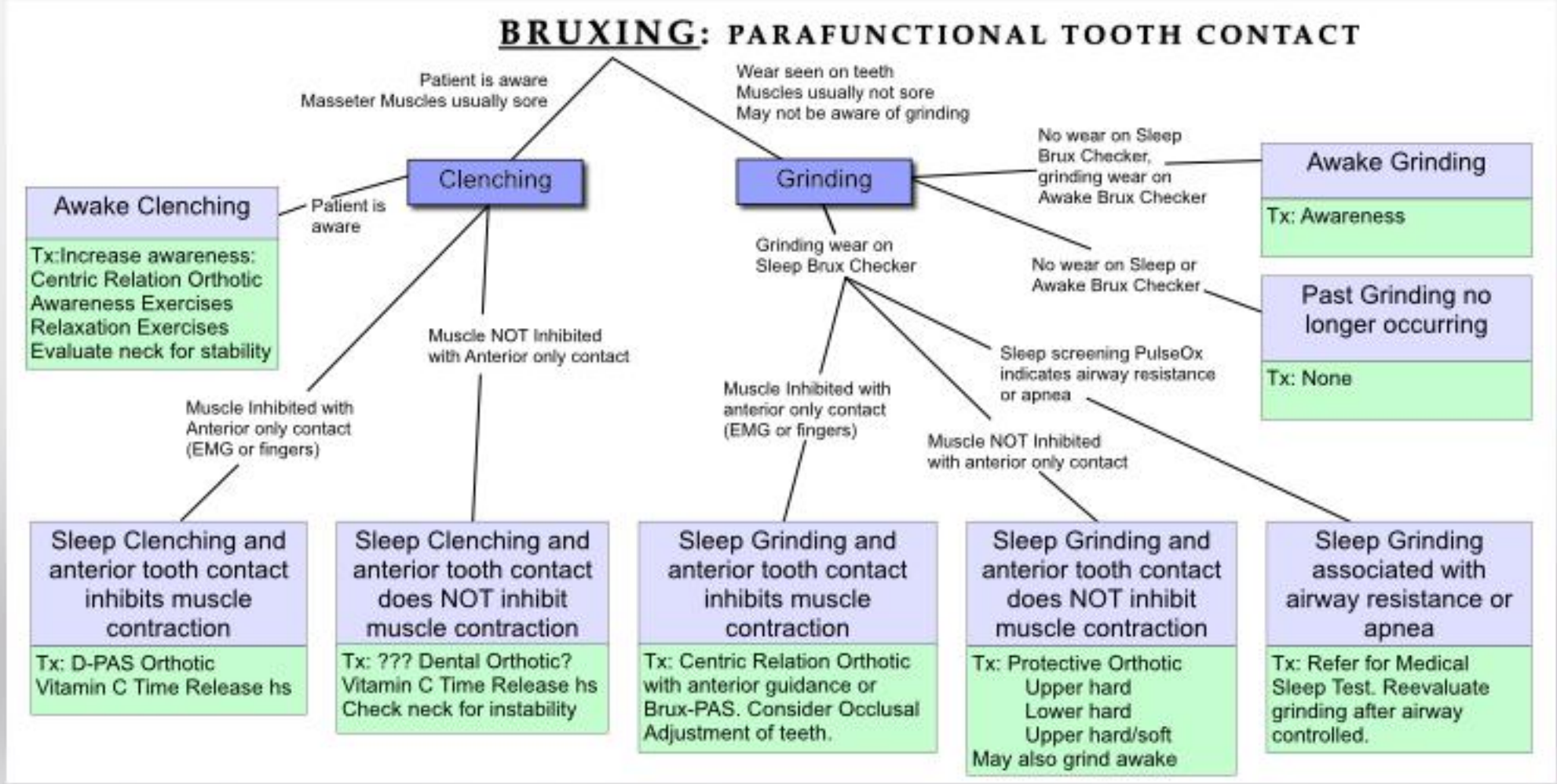
BRUXING: PARAFUNCTIONAL TOOTH CONTACT
Patient is aware
Masseter Muscles usually sore
Wear seen on teeth
Muscles usually not sore
May not be aware of grinding
Clenching
Grinding
Awake Clenching
Tx:Increase awareness:
Centric Relation Orthotic
Awareness Exercises
Relaxation Exercises
Evaluate neck for stability
Patient is aware
No wear on Sleep Brux Checker, grinding wear on Awake Brux Checker
Awake Grinding
Tx: Awareness
Grinding wear on Sleep Brux Checker
No wear on Sleep or Awake Brux Checker
Past Grinding no longer occurring
Tx: None
Muscle NOT Inhibited with Anterior only contact
Sleep screening PulseOx indicates airway resistance or apnea
Muscle Inhibited with Anterior only contact (EMG or fingers)
Muscle Inhibited with anterior only contact (EMG or fingers)
Muscle NOT Inhibited with anterior only contact
Sleep Clenching and anterior tooth contact inhibits muscle contraction
Tx: D-PAS Orthotic
Vitamin C Time Release hs
Sleep Clenching and anterior tooth contact does NOT inhibit muscle contraction
Tx: ??? Dental Orthotic?
Vitamin C Time Release hs
Check neck for instability
Sleep Grinding and anterior tooth contact inhibits muscle contraction
Tx: Centric Relation Orthotic with anterior guidance or Brux-PAS. Consider Occlusal Adjustment of teeth.
Sleep Grinding and anterior tooth contact does NOT inhibit muscle contraction
Tx: Protective Orthotic
Upper hard
Lower hard
Upper hard/soft
May also grind awake
Sleep Grinding associated with airway resistance or apnea
Tx: Refer for Medical Sleep Test. Reevaluate grinding after airway controlled.

More Information on Bruxing:

www.JRDroter.com

Seminar Downloads
Bruxing SuperSheet

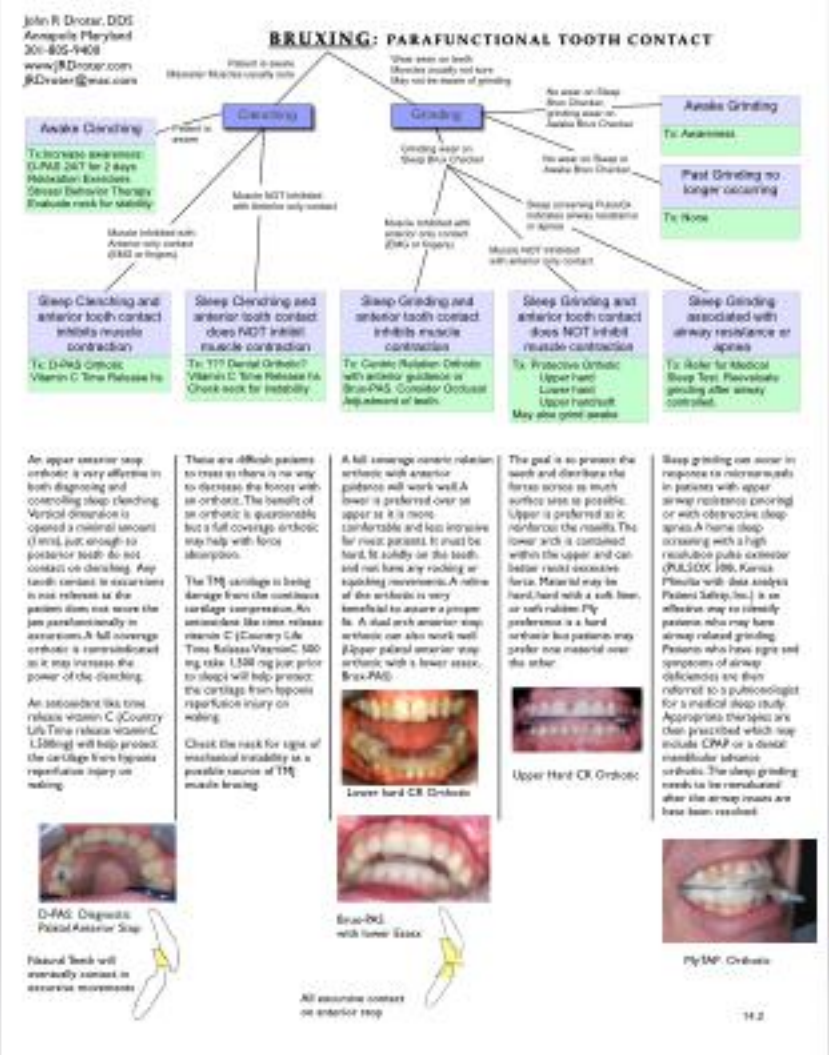

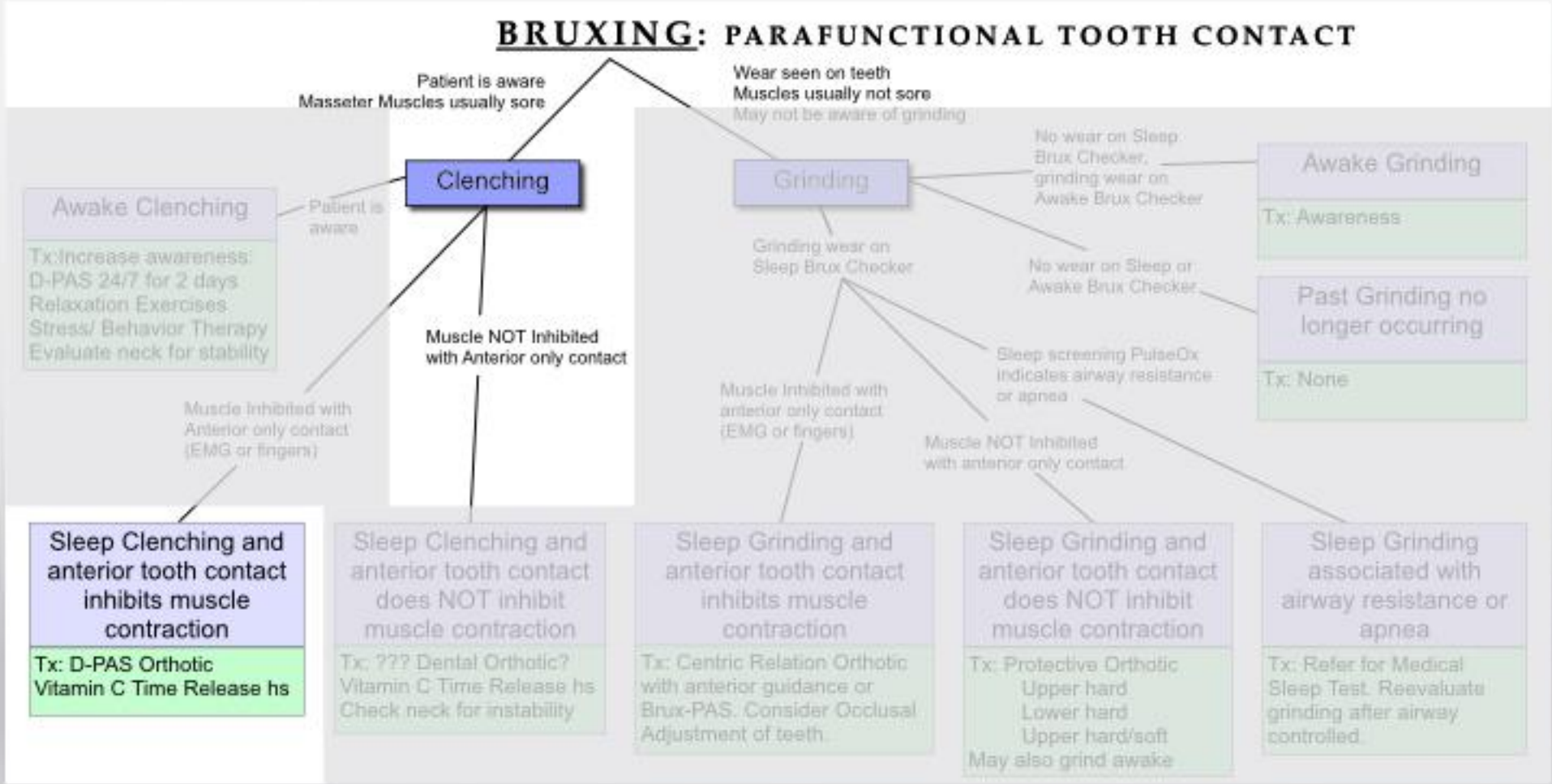
BRUXING: PARAFUNCTIONAL TOOTH CONTACT
Patient is aware
Masseter Muscles usually sore
Wear seen on teeth
Muscles usually not sore
May not be aware of grinding
Clenching
Grinding
Awake Clenching
Patient is aware
Tx:Increase awareness:
D-PAS 24/7 for 2 days
Relaxation Exercises
Stress/ Behavior Therapy
Evaluate neck for stability
Muscle NOT Inhibited with Anterior only contact
Muscle Inhibited with Anterior only contact (EMG or fingers)
Sleep Clenching and anterior tooth contact inhibits muscle contraction
Tx: D-PAS Orthotic
Vitamin C Time Release hs
Sleep Clenching and anterior tooth contact does NOT inhibit muscle contraction
Tx: ??? Dental Orthotic?
Vitamin C Time Release hs
Check neck for instability
Grinding wear on Sleep Brux Checker
Muscle Inhibited with anterior only contact (EMG or fingers)
Sleep Grinding and anterior tooth contact inhibits muscle contraction
Tx: Centric Relation Orthotic with anterior guidance or Brux-PAS. Consider Occlusal Adjustment of teeth.
No wear on Sleep Brux Checker, grinding wear on Awake Brux Checker
Awake Grinding
Tx: Awareness
No wear on Sleep or Awake Brux Checker
Past Grinding no longer occurring
Tx: None
Sleep screening PulseOx indicates airway resistance or apnea
Muscle NOT Inhibited with anterior only contact
Sleep Grinding and anterior tooth contact does NOT inhibit muscle contraction
Tx: Protective Orthotic
Upper hard
Lower hard
Upper hard/soft
May also grind awake
Sleep Grinding associated with airway resistance or apnea
Tx: Refer for Medical Sleep Test. Reevaluate grinding after airway controlled.

Clenching can cause disc subluxation

Chronic Micro Trauma from clenching

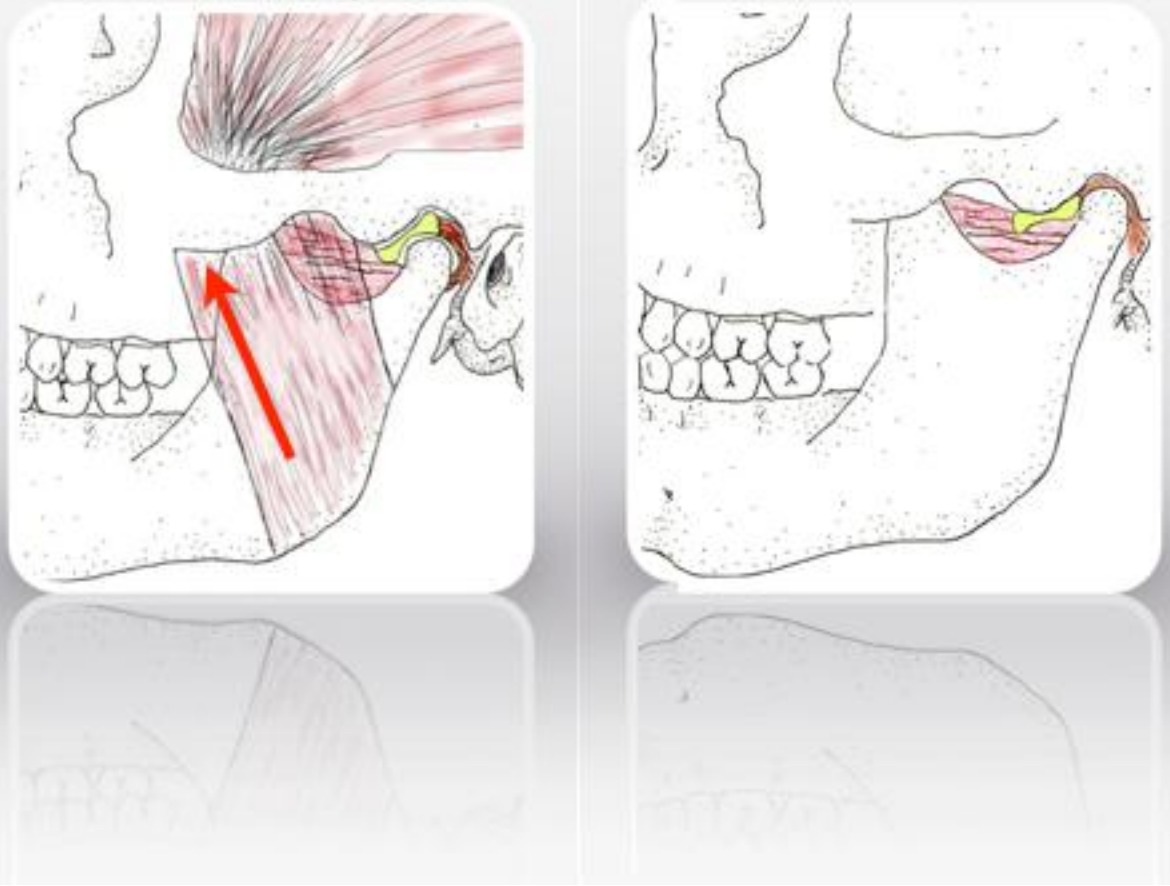

Clenching can lead to disc dislocation

Normal

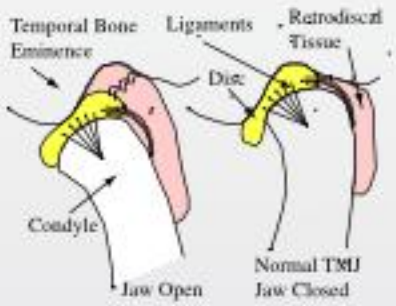

"Sticky Disc" - Clenching causes disc to stick in upper joint compartment. As condyle moves forward, disc distorts and eventually releases, making a clicking sound. On closing disc is slow to return, stretching discal ligaments.

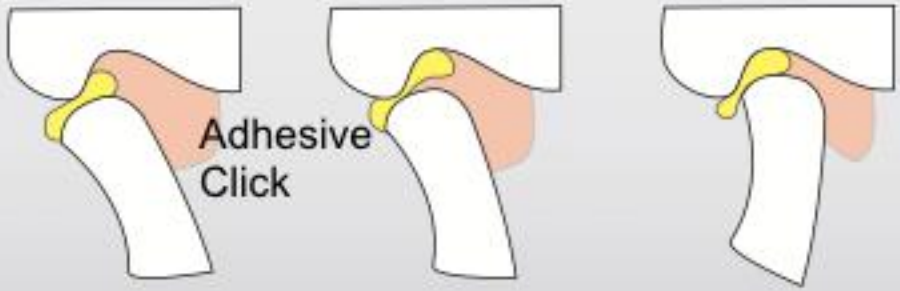

Over time can lead to Anterior Disc Dislocation with Reduction

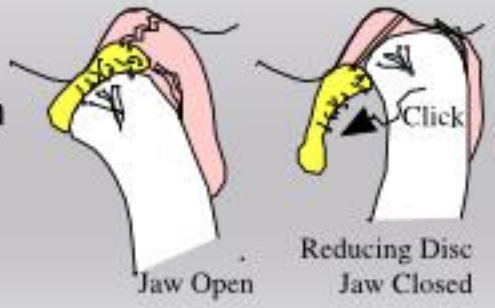

Nitzan, DW, The Process of lubrication impairment and its involvement in temporomandibular joint disc displacement: a theoretical concept, J Oral Maxillofac Surg. 59:36-45, 2001

Treating Common TMDs in a General Practice

Diagnosis	Pattern	~~Treatment~~ Management
Sleep Clenching with anterior tooth contact inhibition	Sore masseters on waking Morning TMJ clicking that resolves Sleep D-PAS Relieves Symptoms	D-PAS Night Guard Time Release Vitamin C hs

Patient is usually aware of clenching
Strong Masseters, Sore Masseters
See slight wear around tooth contacts
Damage TMJ cartilage

If sleep D-PAS eliminates sore masseters, this becomes this becomes their sleep orthotic.

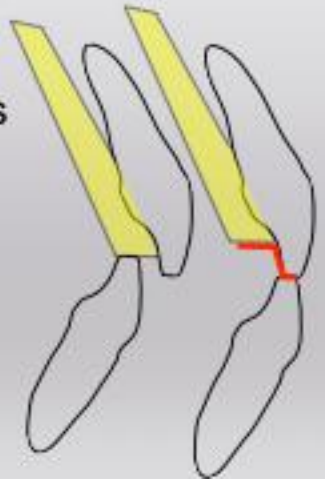

Palatal Anterior Stop Orthotic

Caution:
Make sure power muscles are inhibited with D-PAS in place.
If no inhibition, do not use D-PAS as treatment.

Hypoxia Re-perfusion Injury

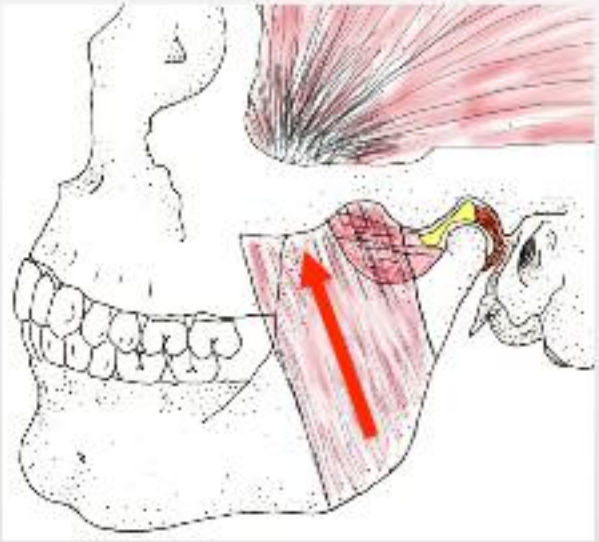

Clenching: Static Loading No Oxygen/Hypoxia
On waking with joint motion get re-perfusion of Oxygen
Oxygen Free Radicals cause Oxidative Damage

If antioxidants (Vitamin A, C, E) around:
- Protects tissue from damage
- Vitamin C 1000 mg at dinner with other vitamins
  - NOW Vitamin C Sustained Release 1000 mg
  - Shaklee Vitamin C Sustained Release 500 mg x2

Tx for Clenchers: Vitamin C at dinner, possible add Mg++ at 8pm , D-PAS

Blake DR, Merry P, Unsworth J, Kidd BL, Outhwaite JM, Ballard R, Morris CJ, Gray L, Lunec J. Hypoxic-reperfusion injury in the inflamed human joint. Lancet. 1989 Feb 11;1(8633):289-93.

McAlindon TE, Jacques P, Zhang Y, Hannan MT, Do antioxidant micronutrients protect against the development and progression of knee osteoarthritis?, Arthritis Rheum. 1996 Apr;39(4):648-56.

Magnesium Nutritional Supplementation

Magnesium is the "Muscle Relaxation" mineral- used in ER and Obstetrics
Magnesium deficiency may increase clenching
Most Magnesium is intracellular so blood test may not detect deficiency

Supplemental Magnesium
- Take 2h before bed (8pm).
- Too much will cause Diarrhea. Right amount will loosen stools.
- Need to be sure kidneys are healthy

Natural Calm Magnesium Citrate- 1 teaspoon (162mg)
Mother Earth Ionic Angstrom Magnesium- 0.5 teaspoon sublingual (5mg)

www.naturalvitality.com

www.meminerals.com

Muscle Nerve. 2014 Apr 8. doi: 10.1002/mus.24260. Extracellular magnesium and calcium reduce myotonia in isolated ClC-1 inhibited human muscle. Skov M1, de Paoli FV, Lausten J, Nielsen OB.

Gynecol Endocrinol. 2007 Jul;23(7):368-72. Magnesium ion inhibits spontaneous and induced contractions of isolated uterine muscle. Tica VI1, Tica AA, Carlig V, Banica OS.

Studies on magnesium deficiency in animals: i. symptomatology resulting from magnesium deprivation. H. D. Kruse, Elsa R. Orent and E. V. McCollum. J. Biol. Chem. 1932, 96:519-539.

TMDs- What are the choices? (190 Diagnoses, 7 Categories)

1. TMJ Damage

Adhesions and ankylosis of temporomandibular joint
Avascular Necrosis Mandibular Condyle
Cartilage Fibrillation, Mandibular Condyle, Fossa
Closed Lock, Jaw Cartilage, Acute
Closed Lock, Jaw Cartilage, Chronic
Closed Lock, Jaw Cartilage, Intermittent, Mechanically dysfunctional
Crush Injury Mandibular Condyle
Crystal arthropathy, unspecified, TMJ
Dislocation jaw cartilage due to injury, Sequela
Dislocation jaw cartilage with reduction, favorable adaptation, TMJ
Dislocation jaw cartilage without reduction, favorable adaptation, TMJ
Effusion, TMJ
Impingement Retrodiscal Tissue
Inflammatory Tissue Bone Resorption, TMJ Condyle
Loose Body (Joint Mice), TMJ
Malignant neoplasm of bones of skull and face
Open Lock TMJ, Recurring
Osteoarthritis TMJ, active degeneration
Osteoarthrosis- Inactive
Osteochondritis Dissecans TMJ
Osteolysis Mandibular Condyle, Active
Perforation Meniscus, TMJ
Perforation Pseudodisc, TMJ
Psoriatic Arthritis TMJ
Rheumatoid Arthritis Sero Negative TMJ

2. Muscles of the TMJ

Occlusal Muscle Disharmony

Muscle Bracing TMJ stabilization
Muscle Bracing Airway **Patency** (with Tongue)
Muscle Contracture Fibrosis Lateral Pterygoid
Muscle Contracture Fibrosis Masseter, Medial Pterygoid, Temporalis
Muscle Fatigue Overuse
Muscle Hypertrophy TMJ Muscles

3. Cranial Alignment/Occlusion

Cranial Distortion / Misalignment
Hemifacial Hypoplasia
Hyper Occlusal Awareness
Iatrogenic Orthotic Damage
Malocclusion Anterior Open Bite
Malocclusion Centric occlusion MaxIC discrepancy
Malocclusion Deep Bite
Malocclusion due to mouth breathing
Malocclusion due to TMJ bone loss
Malocclusion due to tongue, lip or finger habits
Malocclusion Insufficient anterior occlusal guidance
Malocclusion lack of posterior occlusal support
Malocclusion Posterior Openbite Bilateral
Malocclusion Posterior Openbite Unilateral
Malocclusion unspecified
Malposition /Misalignment: Maxilla, Temporal Bone, Mandible
Mandibular asymmetry
Mandibular hyperplasia
Mandibular hypoplasia
Mandibular Retrognathia
Maxillary asymmetry
Maxillary hyperplasia
Maxillary hypoplasia
Maxillary Retrognathia
Occlusal Adaptation, Favorable
Occlusal Dependency for Joint Stabilization/ Proprioception
Tooth Intrusion
Tooth Supereruption

4. Cervical Damage

Cervical Vertebrae Alignment Dysfunction
Cervicocranial Syndrome
Muscle Guarding due Neck Instability
Trigger Point Neck Muscle with Referred Pain
Trigger Point Neck Muscle, Localized Pain

5. Parafunction

Excessive Tooth Wear, Damage
Hypersensitive Occlusion
Parafunction clech/grind wiggle
Parafunctional Clenching Teeth, Awake
Parafunctional Clenching Teeth, Sleep
Parafunctional Grinding Teeth, Awake
Parafunctional Grinding Teeth, Sleep
Parafunctional Tongue Bracing avoiding uncomfortable tooth contact
Parafunctional Tongue Bracing Neck stabilization
Parafunctional Tongue Bracing to maintain Airway
Parafunctional Tongue Bracing unknown cause

6. Whole Body / Systemic

Lyme Disease Arthritis
Magnesium Deficiency
Obstructive Sleep Apnea
Osteoporosis without current pathological fracture
Pathological Habitual Movement Pattern
Postural Disharmony Standing
Postural Disharmony Walking
Postural Forward Head Position
Upper Airway Resistance, UARS

7. Other

Nerve Entrapment Masseteric Nerve due to Masseteric hypertonicity
Neuroma Trigeminal Nerve
Obsessive-Compulsive Personality Disorder
Other
Otitis Ear Infection
Pain disorder exclusively related to psychological factors. Somatoform pain disorder
Pain disorder with related psychological factors

Orthopedic Medicine- Optimal Load Bearing Position

Every joint has an optimal load bearing position-
Most Bone Support/ Least Muscle Bracing when Loaded

Centric Relation- Optimal Load bearing position of the TMJ-
Most Bone Support/ Least Muscle Bracing when Loaded

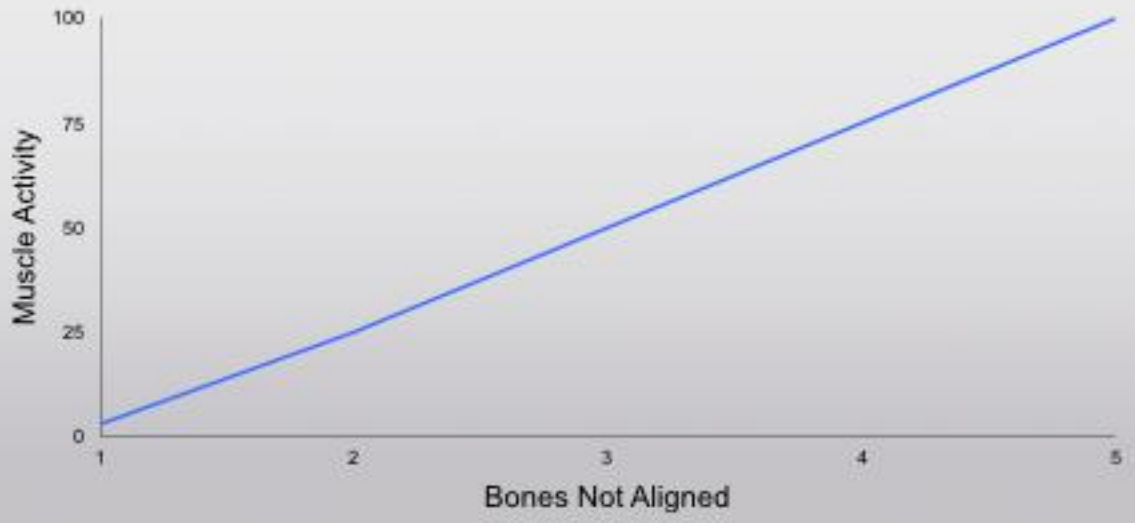

Nemeth G, On hip and lumbar biomechanics. A study of joint load and muscular activity, Scand J Rehabil Med Suppl. 1984;10:1-35.

Occlusal Muscle Disharmony

Uneven tooth contact with condyles fully seated triggers muscle activity

Lateral pterygoid fires out of sequence to create even tooth contact on closure

Disharmony in all muscles: Splinting/Bracing

Muscles sore from overuse

Muscles do not think- CNS input

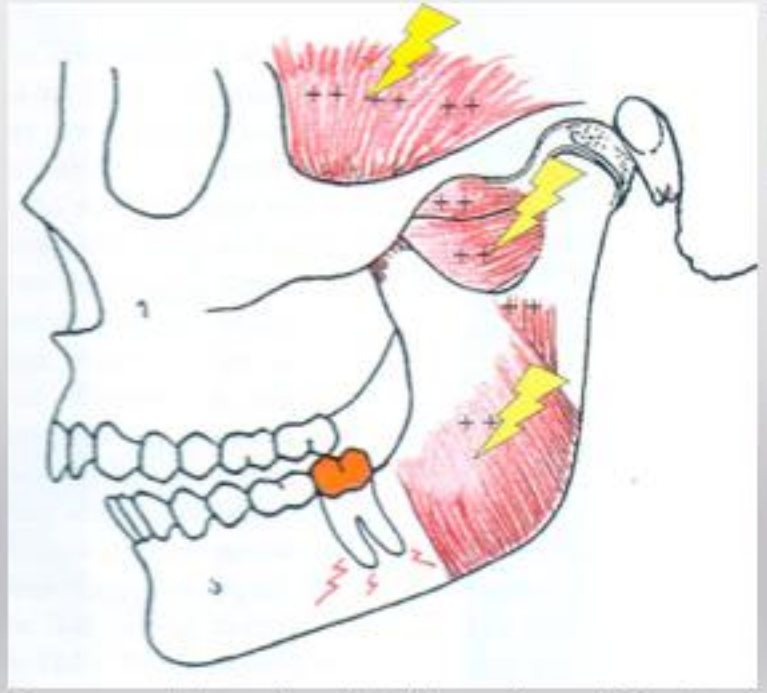

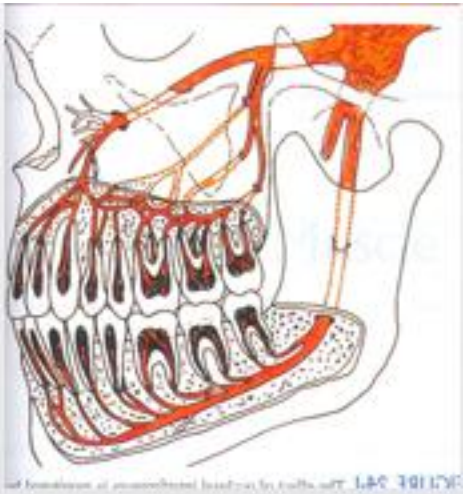

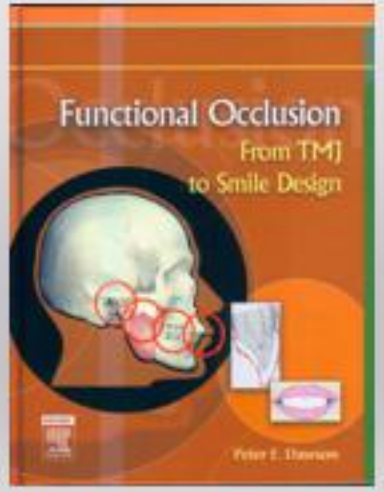

from Dawson's Textbook, "Functional Occlusion"

LD Pankey's 3 Rules of Occlusion

(Clyde Schuyler)

1. With the condyles fully seated in the fossa, all the posterior teeth touch simultaneously and even, with the anterior teeth lightly touching.
2. When you squeeze, neither a tooth nor the mandible moves (in a lateral direction).
3. When you move the mandible in any excursion, no back tooth hits before, harder than, or after a front tooth.

Bonus Rule- Harmonious Anterior Guidance. Cuspid guidance directs the mandible slightly forward, not backward, with smooth cross over from cuspid to anterior teeth. Protrusive contact even on both central incisors.

Bonus Observation- All the above work much better the closer the teeth are to being on the curve of Spee and Curve of Wilson

Why LD Never wrote a text book

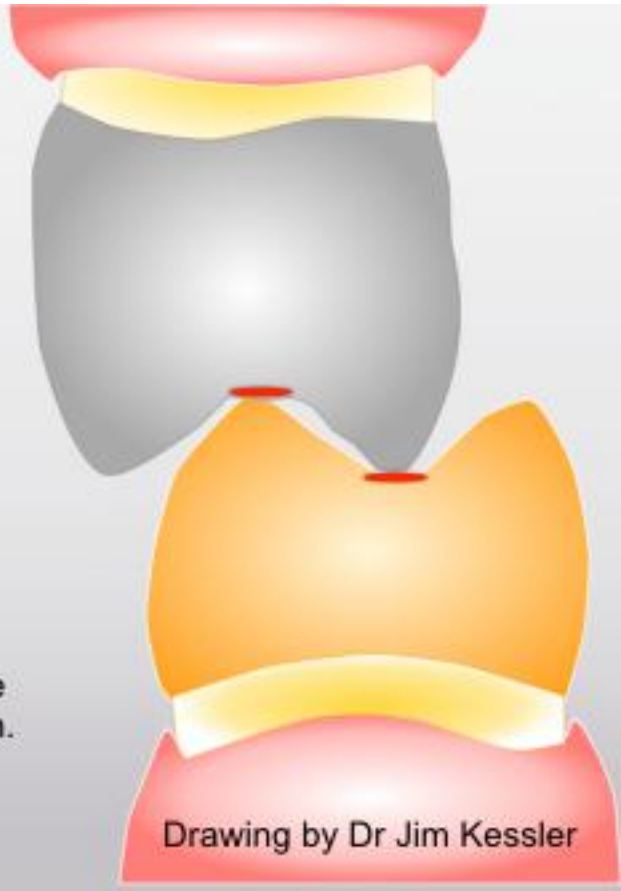

Drawing by Dr Jim Kessler

Slide by Dr John R Droter

LD Pankey's 3 Rules of Occlusion Literature

(Clyde Schuyler)

Schuyler CH. J Florida Dent Soc, 1938.
Occlusal disharmony and its relation to oral discomfort.

Schuyler CH. J Am Dent Assoc. 1958 Aug;57(2):221-31.
Factors of occlusion to be observed in everyday practice.

Schuyler CH. J Pros Dent. 1963 Nov: 13(6): 1011-29.
The function and importance of incisal guidance in oral rehabilitation.

Kerstein, R. B., & Radke, J. (2012). Cranio 30(4), 243–254.
Masseter and temporalis excursive hyperactivity decreased by measured anterior guidance development.

Kerstein, R. B., & Radke, J. (2016). Cranio pp1–17.
Average chewing pattern improvements following Disclusion Time reduction.

LD Pankey's 3 Rules of Occlusion (Clyde Schuyler)

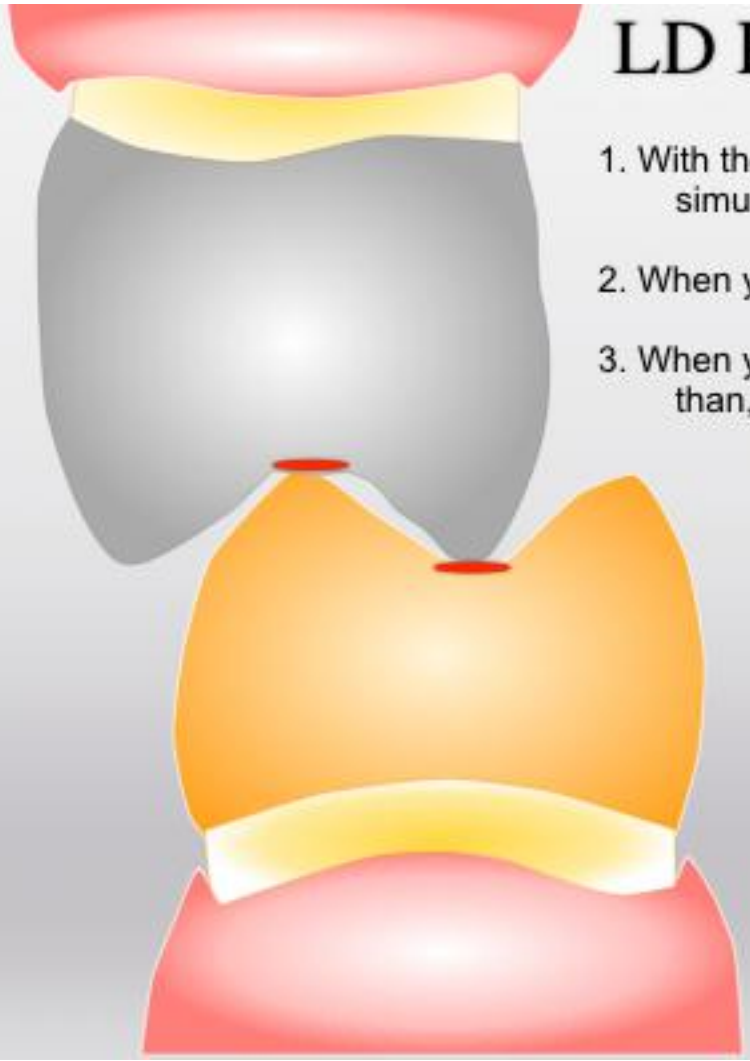

1. With the condyles fully seated in the fossa, all the posterior teeth touch simultaneously and even, with the anterior teeth lightly touching.

2. When you squeeze, neither a tooth nor the mandible moves (in a lateral direction).

3. When you move the mandible in any excursion, no back tooth hits before, harder than, or after a front tooth.

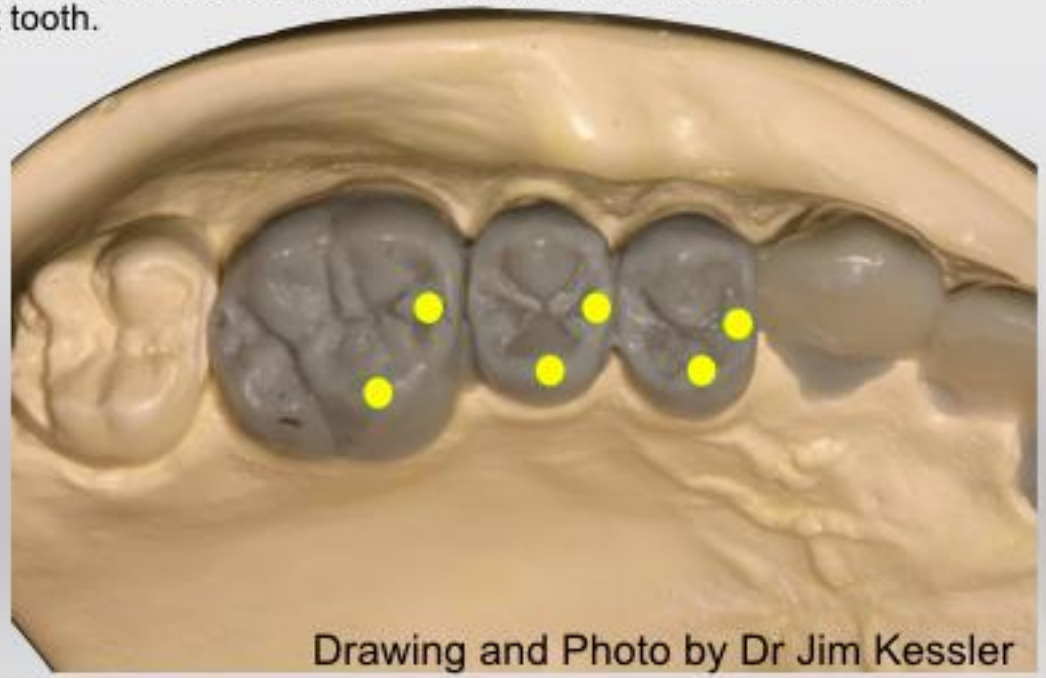

Drawing and Photo by Dr Jim Kessler

Curve of Spee and Curve of Wilson

From Dawson Text Book "Functional Occlusion"

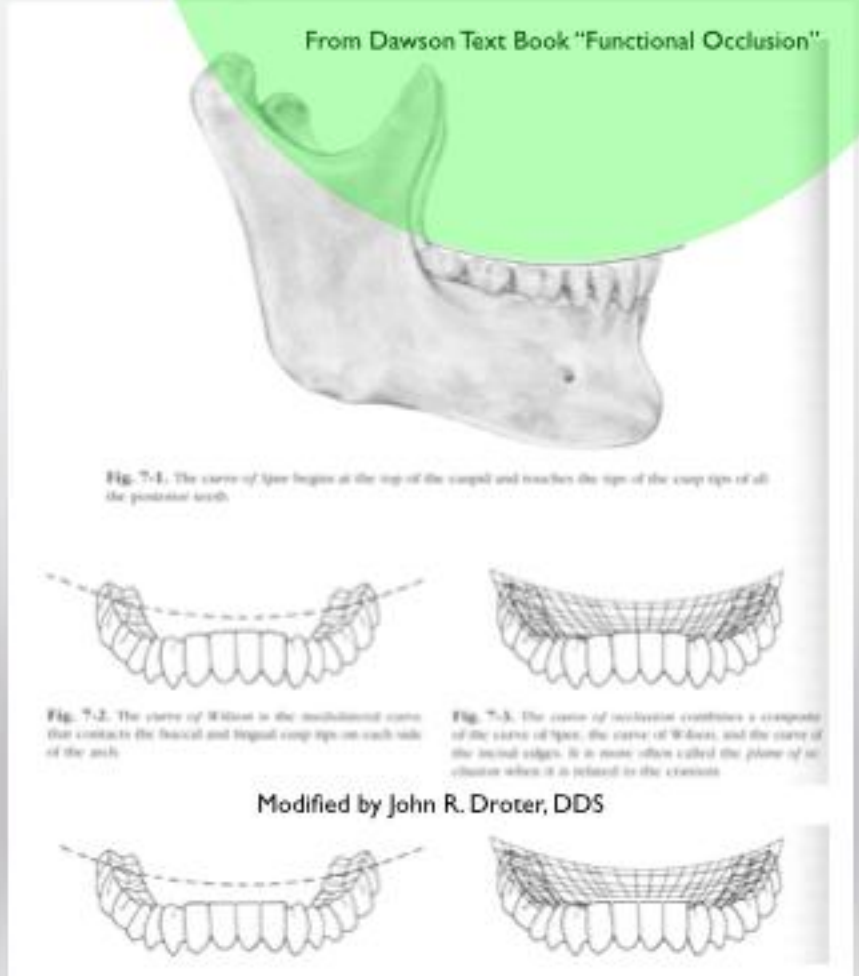

Modified by John R. Droter, DDS

Occlusal Muscle Dysfunction

Something Happened.
Most Common Causes:

- TMJ Damage, adapted joint
- Iatrogenic Dentistry
- Iatrogenic Orthodontics
- Neck Damage

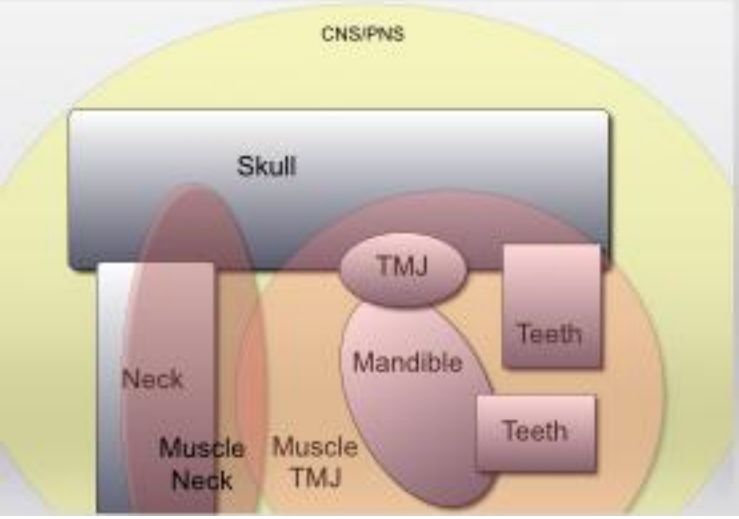

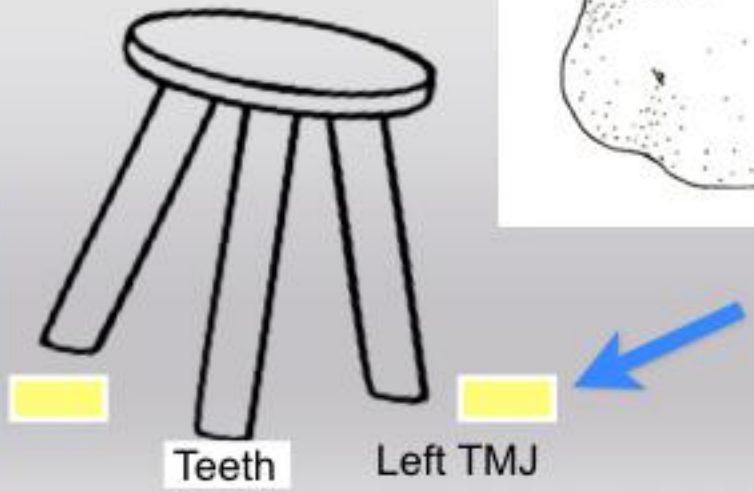

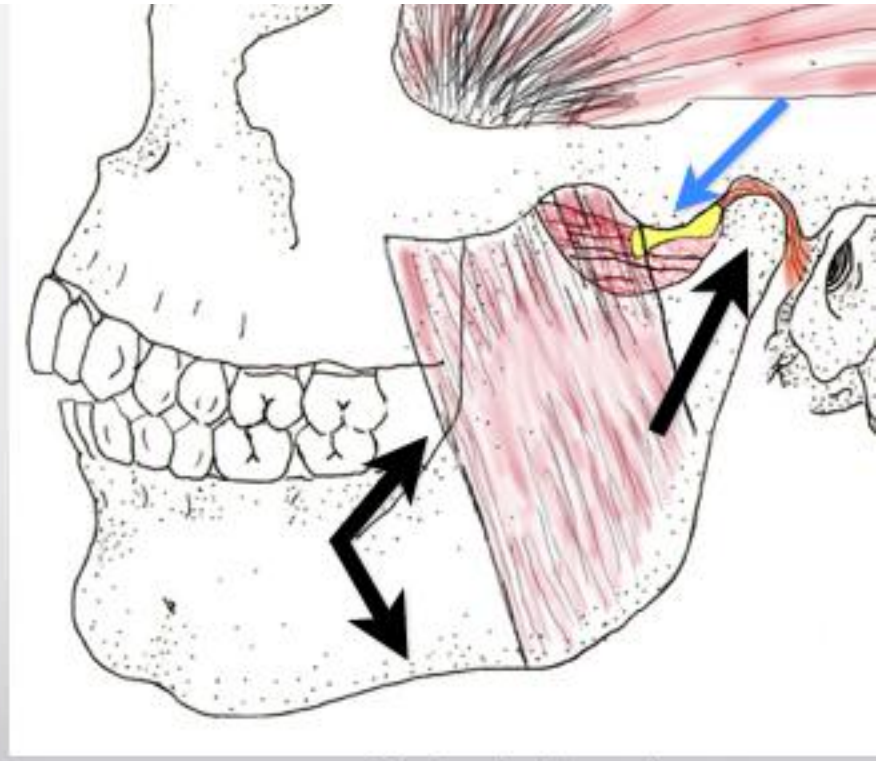

Contact of most posterior tooth

Occlusal Muscle Dysfunction Diagnosis and Treatment

Finding Occlusal Muscle Disharmony Patients (OMD)- Ask do you have headaches?

1. Exam/Differential Diagnosis:
   What is sore- Is it joint, muscle or neck?
   Take History, Palpate TM Joints, Palpate TM muscles, Palpate Neck
   Sore TMJ muscles, no TMJ pain, suspect Occlusal Muscle Disharmony
   Lateral Pterygoid is sore

2. Diagnostic Tests:
   D-PAS Orthotic for 4 days, Night wear only. Test for Clenching.
   D-PAS Orthotic for 2 days, 24 hr wear except to eat. Test for OMD
   Brux Checker (Great Lakes Orthodontics) for 1 night
   Sleep Airway Screening with and with D-PAS
   Rules out other…..

3. Repeat Step 1. If all the pain has gone away then step 4.

4. Occlusal Analysis. Alter Occlusion- See LD Pankey 3 Rules of Occlusion
   Two days before adjust occlusion, use D-PAS 24/7 to verify joint stability.

At any point if pain increases, or if the pain has not fully resolved after 6 weeks of therapy, a full facial pain diagnostic work up is needed including TMJ imaging.

D-PAS Test Interpretation

Decrease Muscle Pain Sleep Wear
Sleep Clenching: Wear D-PAS as night guard

Decrease Muscle Pain Day Wear
Occlusal Muscle Disharmony: Occlusal Adjust

Increase Muscle Pain
Mechanically Unstable TMJ, joint subluxation

Increase Joint Pain
Intracapsular Problem TMJ

No Change in Pain
Damaged TMJ are mechanically stable
Pain not related to occlusion

Masseter Muscle/ tooth contact Inhibition:
Has Inhibition: Can use anterior disclusion
Lacks Inhibition:Full power on clenching

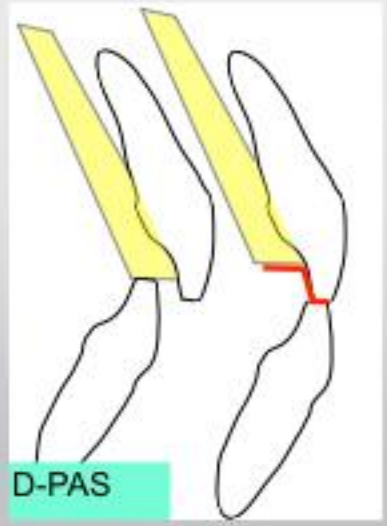

If grinding or airway issue need to address those problems

Treatment (Management) Uses

D-PAS

Diagnostic Palatal Anterior Stop Orthotic

If not Occlusal Muscle Disharmony may be:

Sleep Clenching with muscle inhibition:
D-PAS wear during sleep

Sleep Grinding with muscle inhibition:
Brux-PAS wear during sleep.
Increase vertical of D-PAS,
Add lower essex

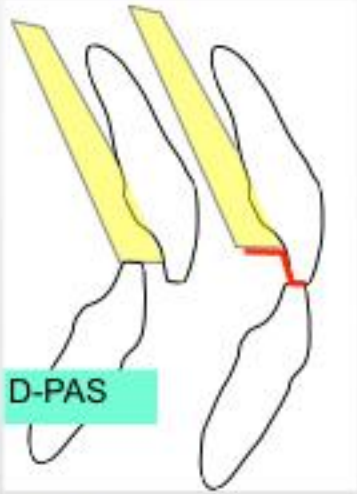

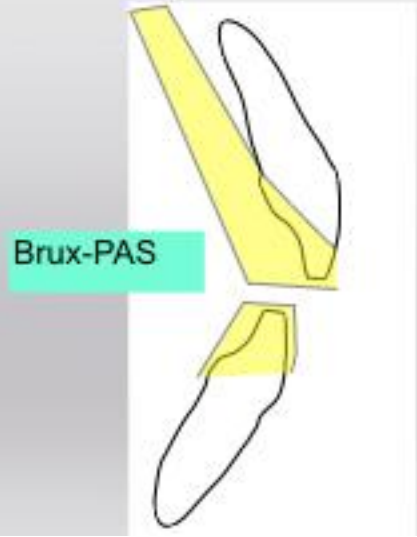

Treating Common TMDs

Diagnosis	Pattern	Treatment
Occlusal Muscle Disharmony	Sore muscles on chewing Sore Lateral Pterygoid Day D-PAS Relieves Symptoms	Occlusal Adjustment

Occlusal Adjusting is an Esthetic Procedure
Form Follows Function

Before

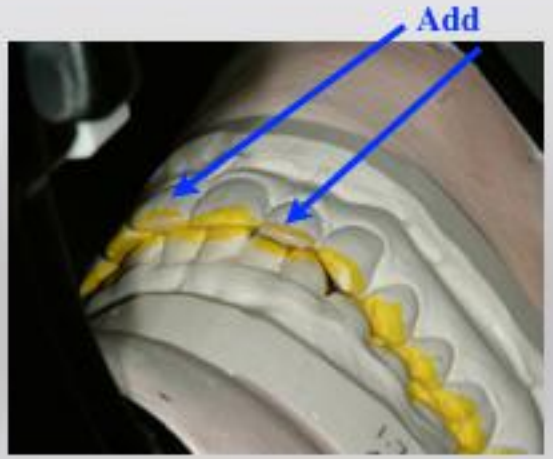

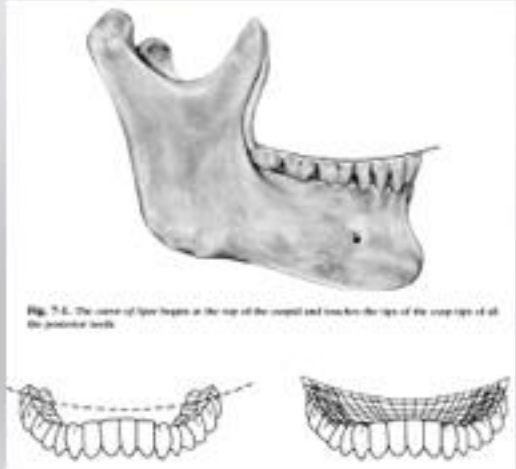

After

Occlusal Sculpting Tools

Wheel
- Create Cusp Landing Zone
- Flatten Incisal edges
- Bulk reduction of inclines

Green Stone Bullet
- Move and Shape Cusps
- Inclines

White Stone Bullet
- Uses same as Green stone
- Use toward end

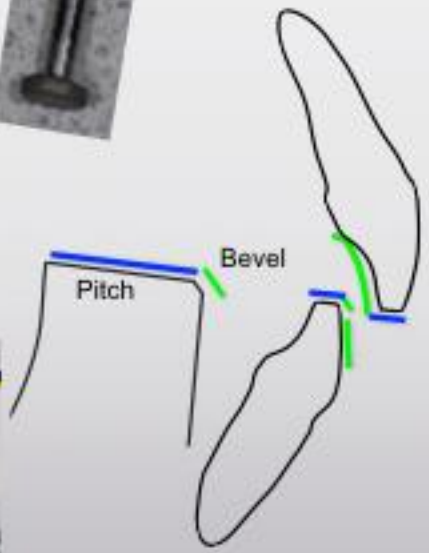

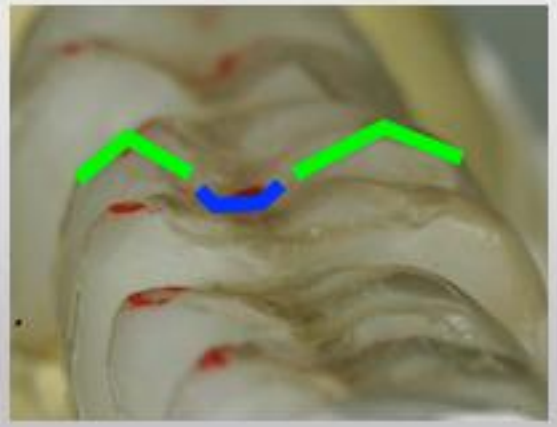

Pogo Disc- Dentsply
Polish all surfaces
Tooth and Porcelain

Premier 860.9 Wheel Fine Diamond
Dedco Green Stone
White Arkansas stone

LD Pankey's 3 Rules of Occlusion (Clyde Schuyler)

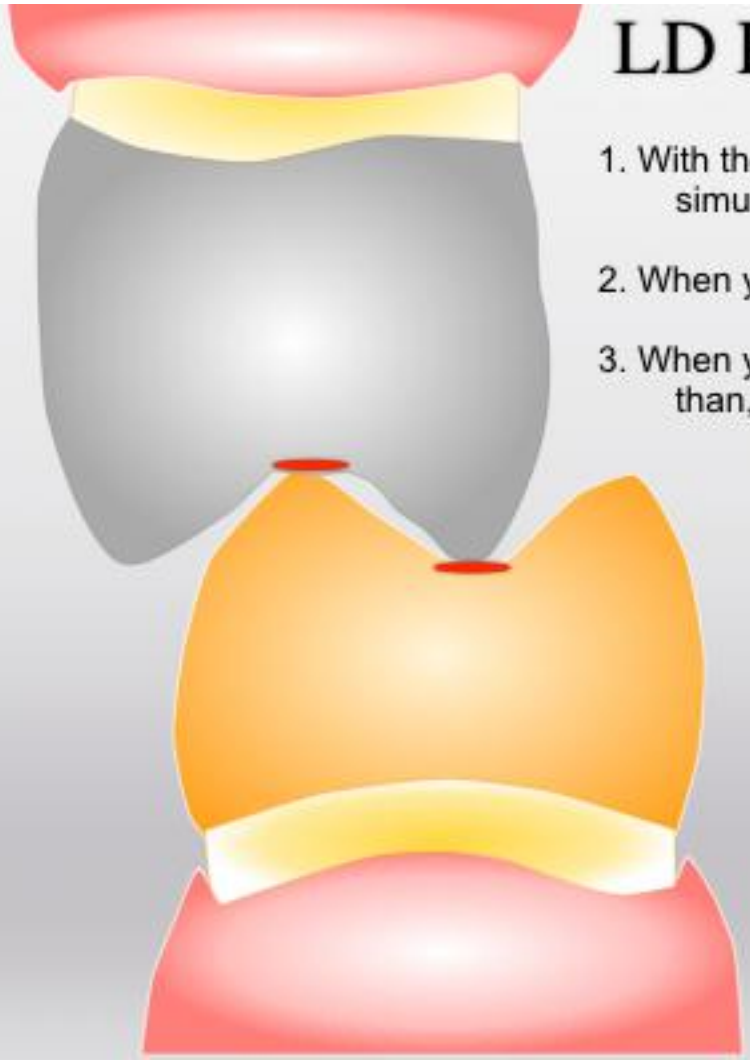

1. With the condyles fully seated in the fossa, all the posterior teeth touch simultaneously and even, with the anterior teeth lightly touching.

2. When you squeeze, neither a tooth nor the mandible moves (in a lateral direction).

3. When you move the mandible in any excursion, no back tooth hits before, harder than, or after a front tooth.

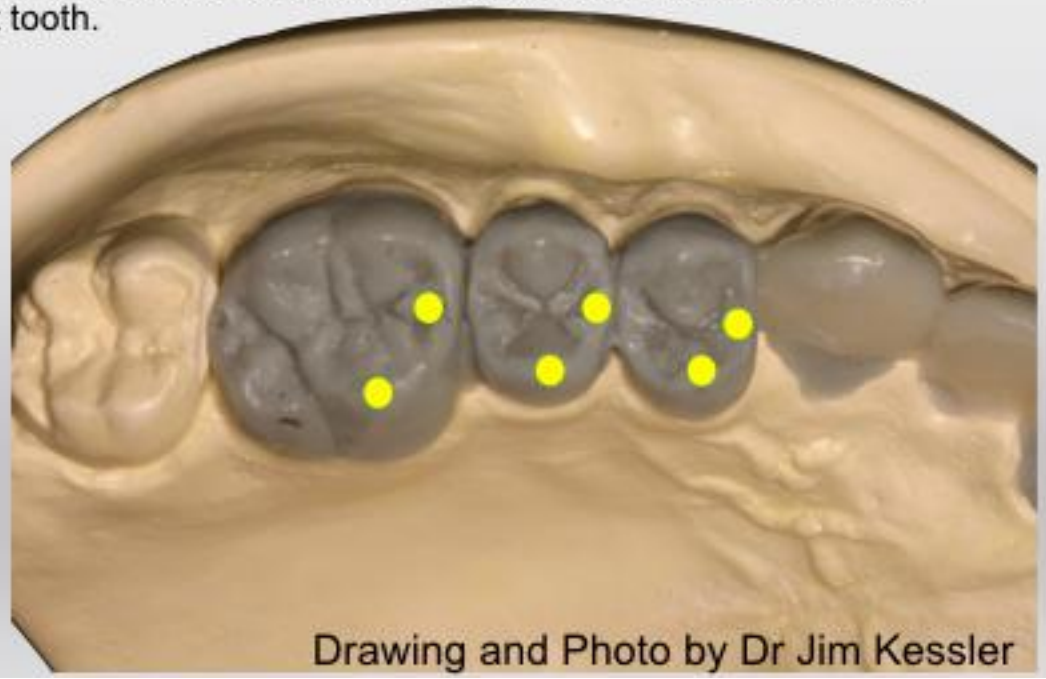

Drawing and Photo by Dr Jim Kessler

Occlusal Adjustment Treatment Assist Orthotic Deprograms throughout the occlusal adjustment

Triad Light Shade
Remove and refine
Solid flat anterior stop
Glue in with Triad clear gel
Adjust in with teeth
Remove once solid posterior stops

Learning the skill of occlusal adjusting to treat occlusal pathology is the doorway into a world of dentistry most do not even imagine. Creating a more harmonious occlusion is a wonderful service to provide for your patients.

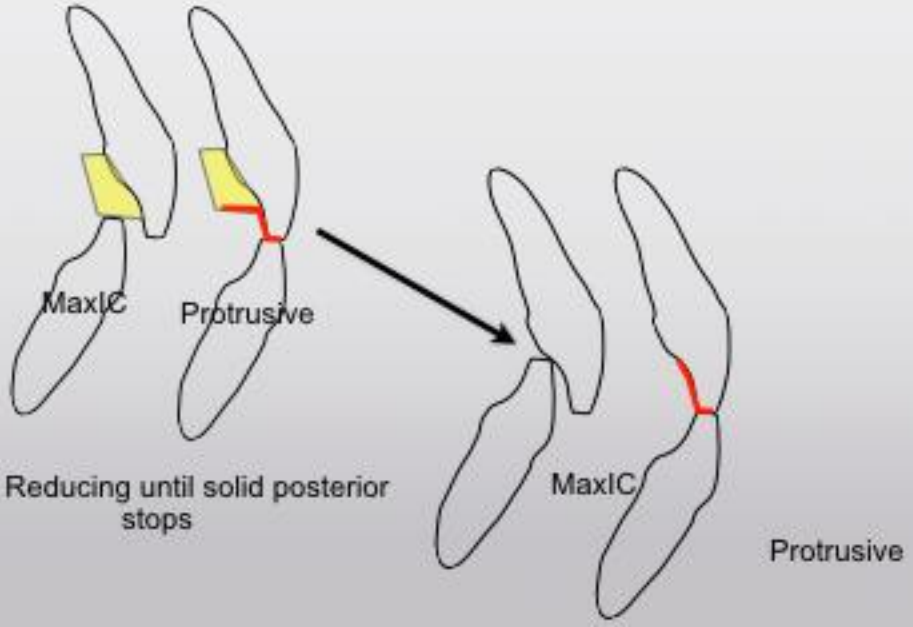

More Harmonious Occlusion ≠ Perfect

T-Scan Computerized Occlusion

Occlusion Live and in Slow Motion

Articulating Paper leaves evidence after the events
- Not Live
- All events lumped together

Using Since1999

Time Force Graphic Representation of the Occlusion

T-Scan Gives you:

Timing
Intensity
Location
Distribution

"Occlusion in Slow Motion"
Regular 10 msec intervals
Turbo 2.5 msec

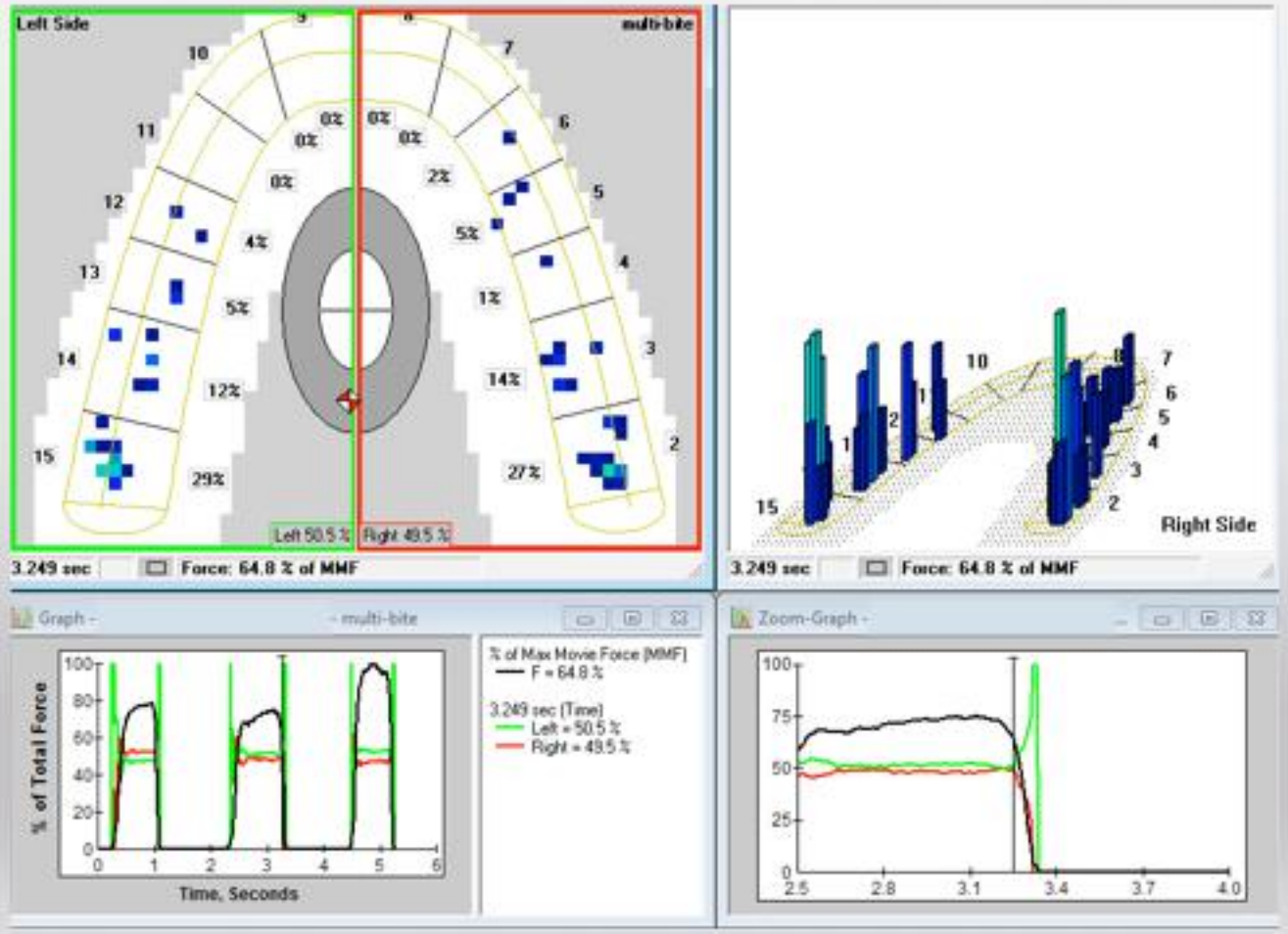

Which dot on temps is heavy?

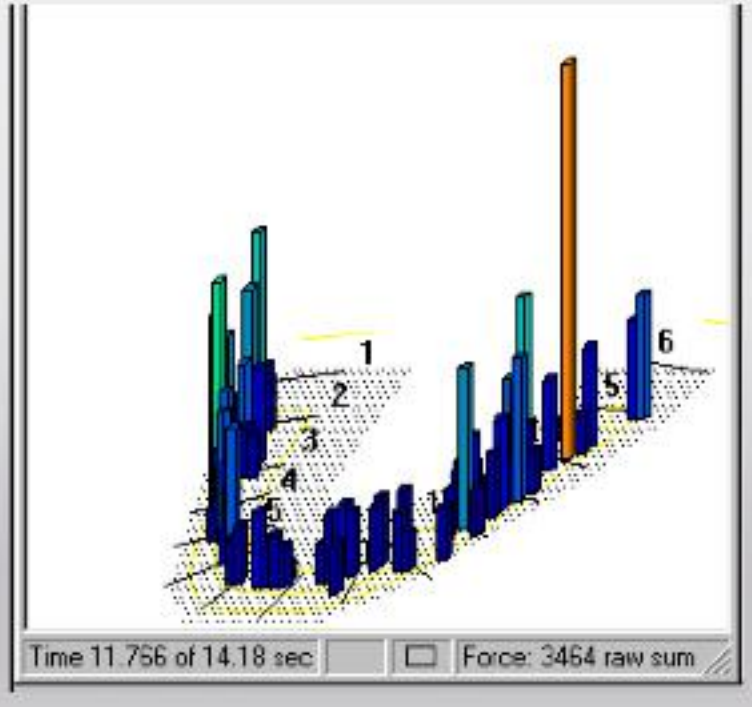

Implant Occlusion

Implants not moving in occlusion is incorrect

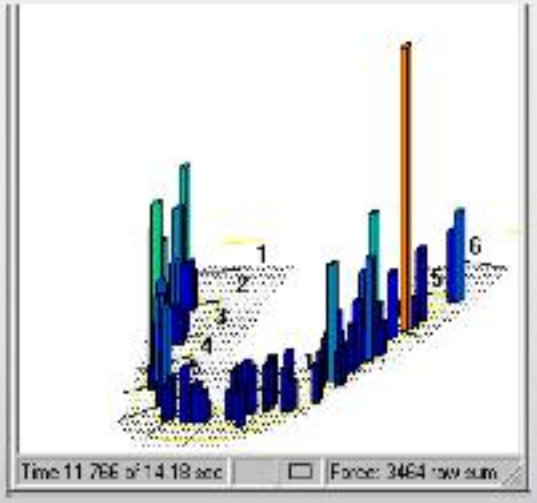

Implants and teeth will both compress bone.
Implants need to come into contact after the PDL compression phase and then they will behave the same as teeth in the bone compression phase.

The indispensable value of T-Scan is not in finding heavy CR contacts, but working and nonworking interferences.

Is that a smudge or a muscle activating interference?

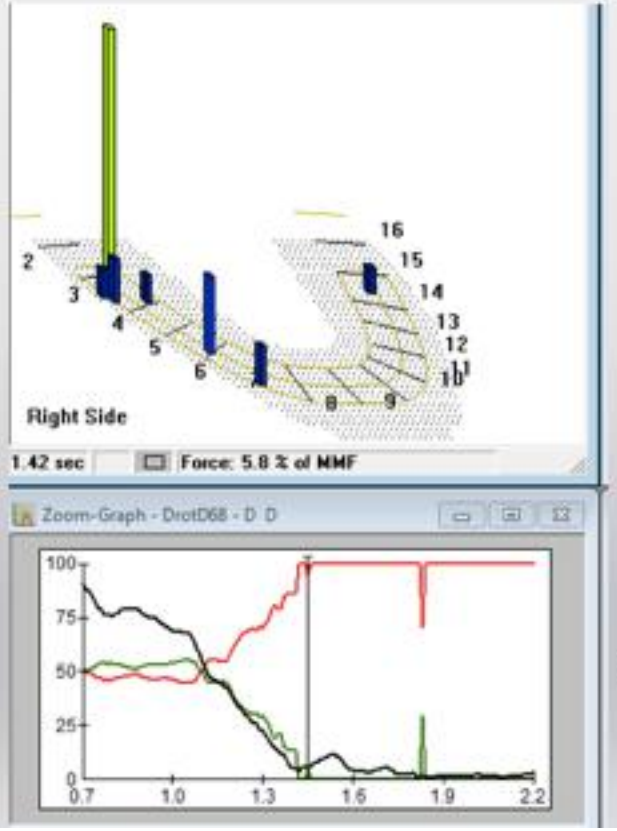

Remove too much and you decrease the ability to chew, especially lettuce. Chewing lettuce requires posterior inclines coming close enough to chew, but far enough apart to not touch and activate muscle.

T-Scan is excellent for Patient Education of Occlusal Pathology

Occlusal disease is under treated by most practitioners due to the difficulty in getting patients to understand the the disease process and the benefits of treatment

The 3D graph is a great teaching tool. Patients understand the 3D Graph.

T scan is an independent , non biased 3rd party verification of the disease.

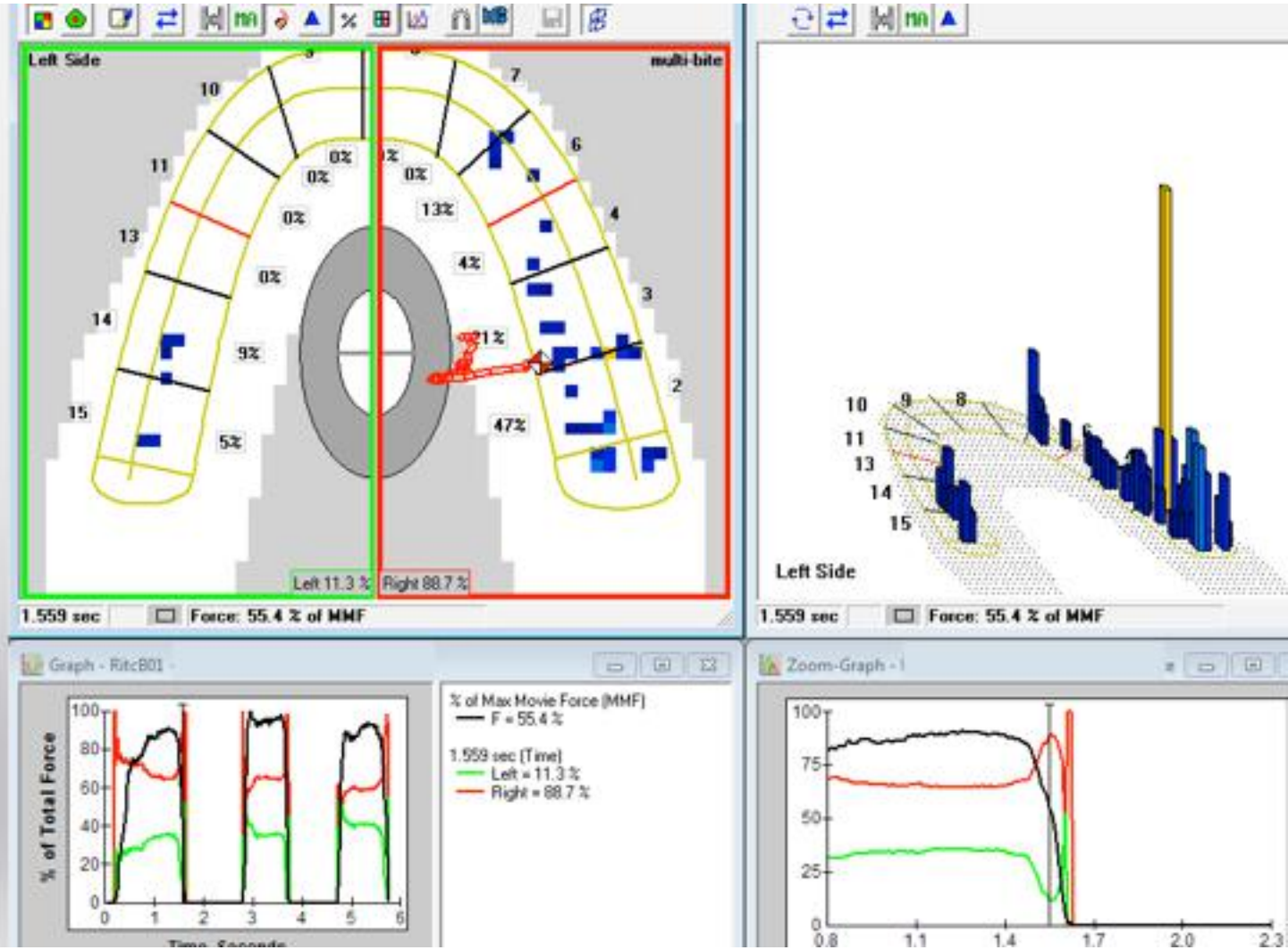

Chapter 15

T-Scan as a Patient Education Tool

John R. Droter, DDS
The Pankey Institute, USA

ABSTRACT

The T-Scan is an effective patient education tool for illustrating existing occlusal pathology. It presents complex occlusal information in a visual format that is easily understood. The T-Scan applies to all stages of the teaching/learning process because its recorded data forms the framework upon which a doctor/patient discussion can begin regarding the patient's occlusal disease manifestations, the potential benefit of treatments, and the risks of not undergoing corrective treatment. When used as part of an educational strategy, the T-Scan can lead the patient to accept procedures that would benefit their long-term dental health. This chapter outlines the four stages of creating optimum dental health, the steps required to perform effective teaching and learning, the differing styles of teaching and learning utilized in educational forums, and how to best employ the technique of Feature, Function, and Benefit. A case study illustrates how T-Scan data can educate a patient about their own occlusal problems.

INTRODUCTION

One of a doctor's many roles is to educate patients with regards to their health (ADA, 2010). The three most prevalent diseases dentists regularly treat are caries, periodontal disease and occlusal disease (Christensen, 2001). Occlusal disease is under treated by many practitioners (Christensen, 1995), which is partially due to the difficulty of having a patient understand the benefits that occlusal therapies offer in the treatment of occlusal pathologies. Utilizing the T-Scan Computerized Occlusal Analysis System (T-Scan 8, Tekscan, Inc. S. Boston, MA, USA) in combination with a well-planned strategy for patient education, can improve the number of patients who accept occlusal therapies that likely would benefit them.

The Four Stages of Health Creation

There are four stages the patient and the clinician must go through, to create health from a diseased state:

Stage 1: Identifying the etiologic factors that cause the disease.

DOI: 10.4018/978-1-4666-6587-3.ch015

IGI Global Website

Chapter 15
T-Scan as a Patient Education Tool

Can buy my chapter individually

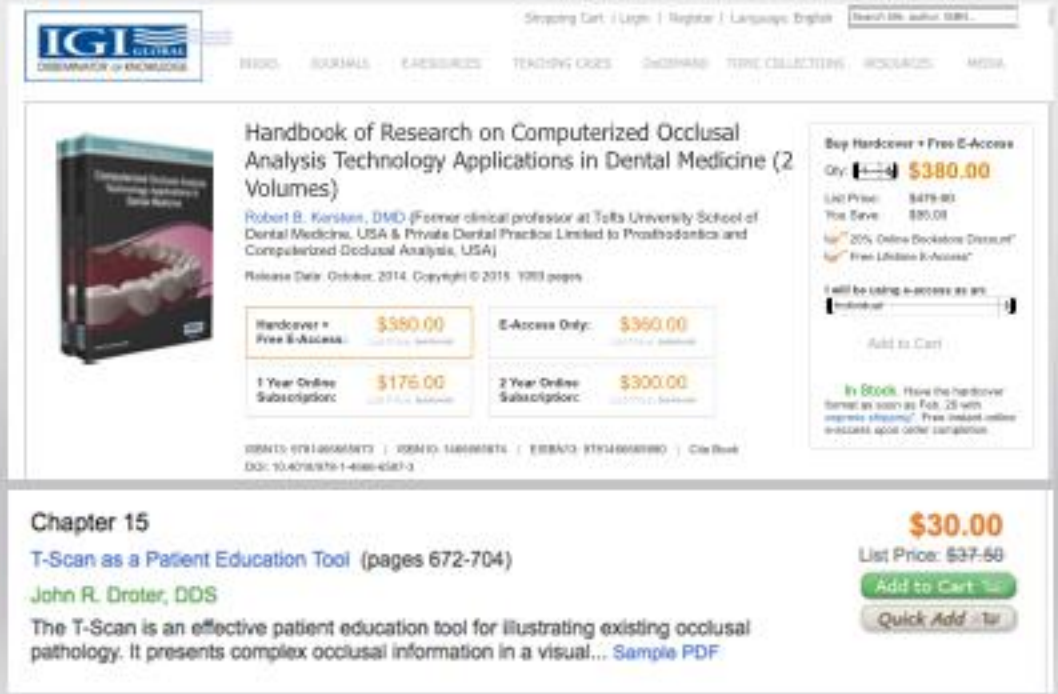

TMDs- What are the choices? (190 Diagnoses, 7 Categories)

1. TMJ Damage

Adhesions and ankylosis of temporomandibular joint
Avascular Necrosis Mandibular Condyle
Cartilage Fibrillation, Mandibular Condyle, Fossa
Closed Lock, Jaw Cartilage, Acute
Closed Lock, Jaw Cartilage, Chronic
Closed Lock, Jaw Cartilage, Intermittent, Mechanically dysfunctional
Crush Injury Mandibular Condyle
Crystal arthropathy, unspecified, TMJ
Dislocation jaw cartilage due to injury, Sequela
Dislocation jaw cartilage with reduction, favorable adaptation, TMJ
Dislocation jaw cartilage without reduction, favorable adaptation, TMJ
Effusion, TMJ
Impingement Retrodiscal Tissue
Inflammatory Tissue Bone Resorption, TMJ Condyle
Loose Body (Joint Mice), TMJ
Malignant neoplasm of bones of skull and face
Open Lock TMJ, Recurring
Osteoarthritis TMJ, active degeneration
Osteoarthrosis- Inactive
Osteochondritis Dissecans TMJ
Osteolysis Mandibular Condyle, Active
Perforation Meniscus, TMJ
Perforation Pseudodisc, TMJ
Psoriatic Arthritis TMJ
Rheumatoid Arthritis Sero Negative TMJ

2. Muscles of the TMJ

Dystonia
Habitual posture forward mandible
Hemifacial Muscle spasm
Inhibitory Reflex Dysfunction, Periodontal Ligament Masseter Muscle
Muscle Atrophy, TMJ
Muscle Bracing Neck Stabilization
Muscle Bracing Pain Avoidance
Muscle Bracing TMJ stabilization
Muscle Bracing Airway **Patency** (with Tongue)
Muscle Contracture Fibrosis Lateral Pterygoid
Muscle Contracture Fibrosis Masseter, Medial Pterygoid, Temporalis
Muscle Fatigue Overuse
Muscle Hypertrophy TMJ Muscles

3. Cranial Alignment/Occlusion

Cranial Distortion / Misalignment
Hemifacial Hypoplasia
Hyper Occlusal Awareness
Iatrogenic Orthotic Damage
Malocclusion Anterior Open Bite
Malocclusion Centric occlusion MaxIC discrepancy
Malocclusion Deep Bite
Malocclusion due to mouth breathing
Malocclusion due to TMJ bone loss
Malocclusion due to tongue, lip or finger habits
Malocclusion Insufficient anterior occlusal guidance
Malocclusion lack of posterior occlusal support
Malocclusion Posterior Openbite Bilateral
Malocclusion Posterior Openbite Unilateral
Malocclusion unspecified
Malposition /Misalignment: Maxilla, Temporal Bone, Mandible
Mandibular asymmetry
Mandibular hyperplasia
Mandibular hypoplasia
Mandibular Retrognathia
Maxillary asymmetry
Maxillary hyperplasia
Maxillary hypoplasia
Maxillary Retrognathia
Occlusal Adaptation, Favorable
Occlusal Dependency for Joint Stabilization/ Proprioception
Tooth Intrusion
Tooth Supereruption

4. Cervical Damage

Cervical Vertebrae Alignment Dysfunction
Cervicocranial Syndrome
Muscle Guarding due Neck Instability
Trigger Point Neck Muscle with Referred Pain
Trigger Point Neck Muscle, Localized Pain

5. Parafunction

Excessive Tooth Wear, Damage
Hypersensitive Occlusion
Parafunction clech/grind wiggle
Parafunctional Clenching Teeth, Awake
Parafunctional Clenching Teeth, Sleep
Parafunctional Grinding Teeth, Awake
Parafunctional Grinding Teeth, Sleep
Parafunctional Tongue Bracing avoiding uncomfortable tooth contact
Parafunctional Tongue Bracing Neck stabilization
Parafunctional Tongue Bracing to maintain Airway
Parafunctional Tongue Bracing unknown cause

6. Whole Body / Systemic

Lyme Disease Arthritis
Magnesium Deficiency
Obstructive Sleep Apnea
Osteoporosis without current pathological fracture
Pathological Habitual Movement Pattern
Postural Disharmony Standing
Postural Disharmony Walking
Postural Forward Head Position
Upper Airway Resistance, UARS

7. Other

Parotid Cancer

[illegible] pain disorder
Pain disorder with related psychological factors
[illegible]

Facial Pain: Not always OMD

CC: Sharp Shooting Nerve Pain Right Face
Dx: Class 2 Malocclusion
Tx: Orthognathic Surgery. Still Facial Pain.
Dx: OMD
Tx: Multiple Occlusal Adjustment over a year
Still Pain
Dx: CT scan reveals Parotid Cancer, Stage 4.

7 Rules for Dx Facial Pain:

1. Listen to the patient, oral and written
2. Patients can have more than one disease
3. Develop a Differential Diagnosis
4. Run tests that increase or decrease the pain
5. Develop a Working Diagnosis
6. Diagnosis Confirmed after Tx
7. Do not chase a diagnosis too long before you rule out cancer.

Rule cancer out early, rule it out often.

TMDs- What are the choices? (190 Diagnoses, 7 Categories)

1. TMJ Damage

Adhesions and ankylosis of temporomandibular joint
Avascular Necrosis Mandibular Condyle
Cartilage Fibrillation, Mandibular Condyle, Fossa
Closed Lock, Jaw Cartilage, Acute
Closed Lock, Jaw Cartilage, Chronic
Closed Lock, Jaw Cartilage, Intermittent, Mechanically dysfunctional
Crush Injury Mandibular Condyle
Crystal arthropathy, unspecified, TMJ
Dislocation jaw cartilage due to injury, Sequela
Dislocation jaw cartilage with reduction, favorable adaptation, TMJ
Dislocation jaw cartilage without reduction, favorable adaptation, TMJ

Impingement Retrodiscal Tissue
Inflammatory Tissue Bone Resorption, TMJ Condyle
Loose Body (Joint Mice), TMJ
Malignant neoplasm of bones of skull and face
Open Lock TMJ, Recurring
Osteoarthritis TMJ, active degeneration
Osteoarthrosis- Inactive
Osteochondritis Dissecans TMJ
Osteolysis Mandibular Condyle, Active
Perforation Meniscus, TMJ
Perforation Pseudodisc, TMJ
Psoriatic Arthritis TMJ
Rheumatoid Arthritis Sero Negative TMJ

4. Cervical Damage

Cervical Vertebrae Alignment Dysfunction
Cervicocranial Syndrome
Muscle Guarding due Neck Instability
Trigger Point Neck Muscle with Referred Pain
Trigger Point Neck Muscle, Localized Pain

5. Parafunction

Without ruling out occlusal problems and parafunction it is hard to figure out the rest.

Muscle Bracing Pain Avoidance
Muscle Bracing TMJ stabilization
Muscle Bracing Airway **Patency** (with Tongue)
Muscle Contracture Fibrosis Lateral Pterygoid
Muscle Contracture Fibrosis Masseter, Medial Pterygoid, Temporalis
Muscle Fatigue Overuse
Muscle Hypertrophy TMJ Muscles

3. Cranial Alignment/Occlusion

Cranial Distortion / Misalignment
Hemifacial Hypoplasia
Hyper Occlusal Awareness
Iatrogenic Orthotic Damage
Malocclusion Anterior Open Bite
Malocclusion Centric occlusion MaxIC discrepancy
Malocclusion Deep Bite
Malocclusion due to mouth breathing
Malocclusion due to TMJ bone loss
Malocclusion due to tongue, lip or finger habits
Malocclusion Insufficient anterior occlusal guidance
Malocclusion lack of posterior occlusal support
Malocclusion Posterior Openbite Bilateral
Malocclusion Posterior Openbite Unilateral
Malocclusion unspecified

Malposition /Misalignment: Maxilla, Temporal Bone, Mandible
Mandibular asymmetry
Mandibular hyperplasia
Mandibular hypoplasia
Mandibular Retrognathia
Maxillary asymmetry
Maxillary hyperplasia
Maxillary hypoplasia
Maxillary Retrognathia
Occlusal Adaptation, Favorable
Occlusal Dependency for Joint Stabilization/ Proprioception
Tooth Intrusion
Tooth Supereruption

6. Whole Body / Systemic

Lyme Disease Arthritis
Magnesium Deficiency
Obstructive Sleep Apnea
Osteoporosis without current pathological fracture
Pathological Habitual Movement Pattern
Postural Disharmony Standing
Postural Disharmony Walking
Postural Forward Head Position
Upper Airway Resistance, UARS

7. Other

Nerve Entrapment Masseteric Nerve due to Masseteric hypertonicity
Neuroma Trigeminal Nerve
Obsessive-Compulsive Personality Disorder
Other
Otitis Ear Infection
Pain disorder exclusively related to psychological factors. Somatoform pain disorder
Pain disorder with related psychological factors

TMDs- What are the choices? (190 Diagnoses, 7 Categories)

1. TMJ Damage

Osteoarthritis

Crystal arthropathy, unspecified, TMJ
Dislocation jaw cartilage due to injury, Sequela
Dislocation jaw cartilage with reduction, favorable adaptation, TMJ
Dislocation jaw cartilage without reduction, favorable adaptation, TMJ
Effusion, TMJ

Impingement Retrodiscal Tissue
Inflammatory Tissue Bone Resorption, TMJ Condyle
Loose Body (Joint Mice), TMJ
Malignant neoplasm of bones of skull and face
Open Lock TMJ, Recurring
Osteoarthritis TMJ, active degeneration
Osteoarthrosis- Inactive
Osteochondritis Dissecans TMJ
Osteolysis Mandibular Condyle, Active
Perforation Meniscus, TMJ
Perforation Pseudodisc, TMJ
Psoriatic Arthritis TMJ
Rheumatoid Arthritis Sero Negative TMJ

2. Muscles of the TMJ

Dystonia
Habitual posture forward mandible
Hemifacial Muscle spasm
Inhibitory Reflex Dysfunction, Periodontal Ligament Masseter Muscle
Muscle Atrophy, TMJ
Muscle Bracing Neck Stabilization
Muscle Bracing Pain Avoidance
Muscle Bracing TMJ stabilization
Muscle Bracing Airway **Patentcy** (with Tongue)
Muscle Contracture Fibrosis Lateral Pterygoid
Muscle Contracture Fibrosis Masseter, Medial Pterygoid, Temporalis
Muscle Fatigue Overuse
Muscle Hypertrophy TMJ Muscles

3. Cranial Alignment/Occlusion

Cranial Distortion / Misalignment
Hemifacial Hypoplasia
Hyper Occlusal Awareness
Iatrogenic Orthotic Damage
Malocclusion Anterior Open Bite
Malocclusion Centric occlusion MaxIC discrepancy
Malocclusion Deep Bite
Malocclusion due to mouth breathing
Malocclusion due to TMJ bone loss
Malocclusion due to tongue, lip or finger habits
Malocclusion Insufficient anterior occlusal guidance
Malocclusion lack of posterior occlusal support
Malocclusion Posterior Openbite Bilateral
Malocclusion Posterior Openbite Unilateral
Malocclusion unspecified

Malposition /Misalignment: Maxilla, Temporal Bone, Mandible
Mandibular asymmetry
Mandibular hyperplasia
Mandibular hypoplasia
Mandibular Retrognathia
Maxillary asymmetry
Maxillary hyperplasia
Maxillary hypoplasia
Maxillary Retrognathia
Occlusal Adaptation, Favorable
Occlusal Dependency for Joint Stabilization/ Proprioception
Tooth Intrusion
Tooth Supereruption

4. Cervical Damage

Cervical Vertebrae Alignment Dysfunction
Cervicocranial Syndrome
Muscle Guarding due Neck Instability
Trigger Point Neck Muscle with Referred Pain
Trigger Point Neck Muscle, Localized Pain

5. Parafunction

Excessive Tooth Wear, Damage
Hypersensitive Occlusion
Parafunction clech/grind wiggle
Parafunctional Clenching Teeth, Awake
Parafunctional Clenching Teeth, Sleep
Parafunctional Grinding Teeth, Awake
Parafunctional Grinding Teeth, Sleep
Parafunctional Tongue Bracing avoiding uncomfortable tooth contact
Parafunctional Tongue Bracing Neck stabilization
Parafunctional Tongue Bracing to maintain Airway
Parafunctional Tongue Bracing unknown cause

6. Whole Body / Systemic

Lyme Disease Arthritis
Magnesium Deficiency
Obstructive Sleep Apnea
Osteoporosis without current pathological fracture
Pathological Habitual Movement Pattern
Postural Disharmony Standing
Postural Disharmony Walking
Postural Forward Head Position
Upper Airway Resistance, UARS

7. Other

Nerve Entrapment Masseteric Nerve due to Masseteric hypertonicity
Neuroma Trigeminal Nerve
Obsessive-Compulsive Personality Disorder
Other
Otitis Ear Infection
Pain disorder exclusively related to psychological factors. Somatoform pain disorder
Pain disorder with related psychological factors
Retrohead Syndrome

Normal TMJ- Synovium, Cartilage

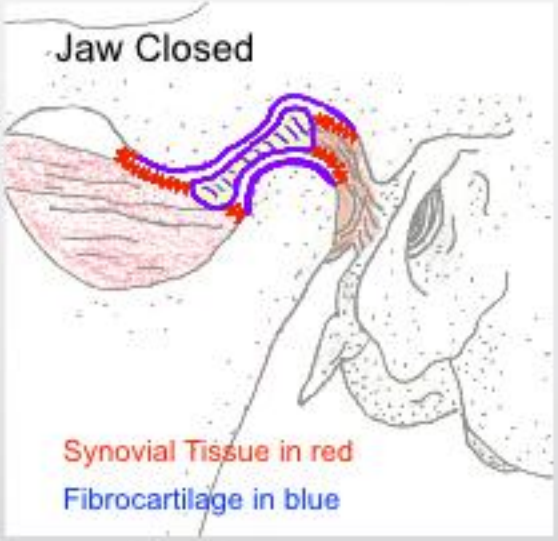

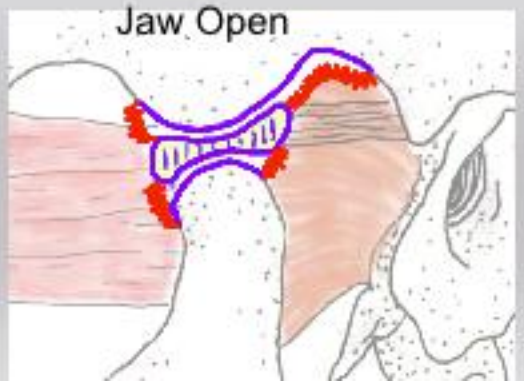

Fibrocartilage-
- Slope of Eminence
- Disc
- Top of Condyle

Synovial Tissue makes Synovial Fluid
- No blood vessels in a health joint
- Nutrition to the cartilage cells
- Lubrication- Hyaluronic Acid and Lubricin

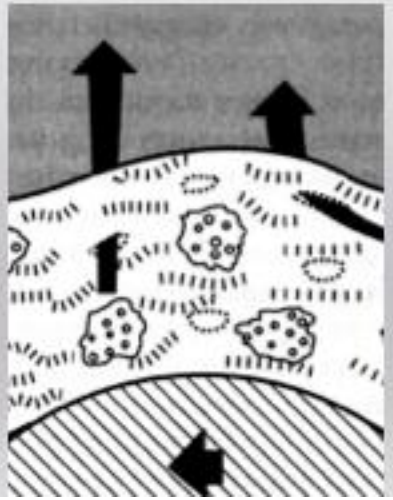

Fibrocartilage surface covered in fluid
- Cartilage is hydrophilic
- Proteoglycan negative charge
- Surface Active Phospholipids
- Fluid slides against fluid
- 5x slipperier than ice

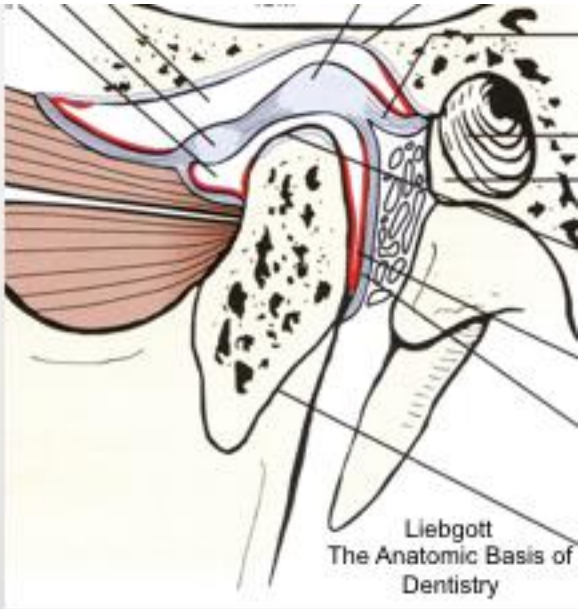

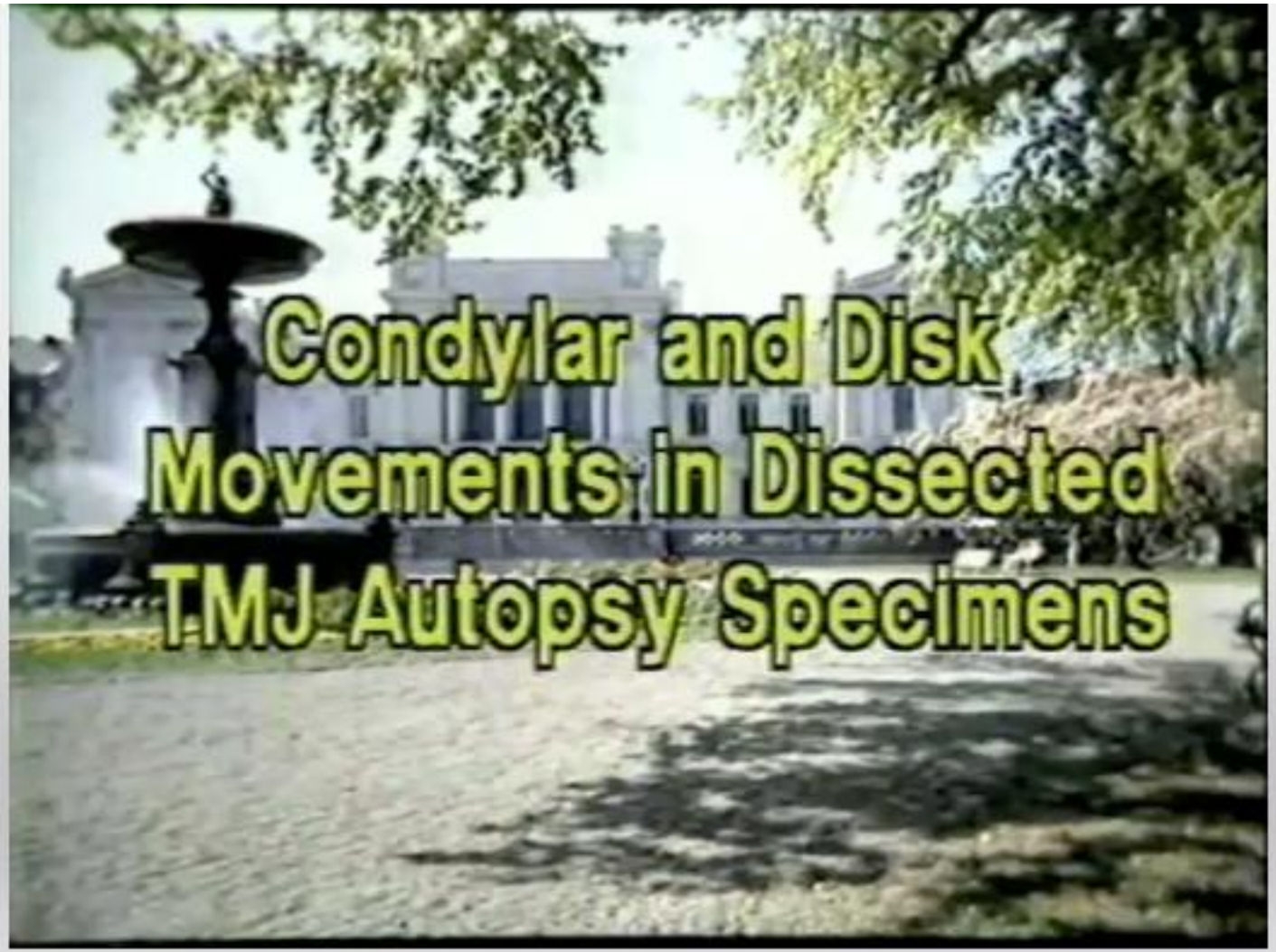
Condylar and Disk
Movements in Dissected
TMJ Autopsy Specimens

Left TMJ Sagittal View

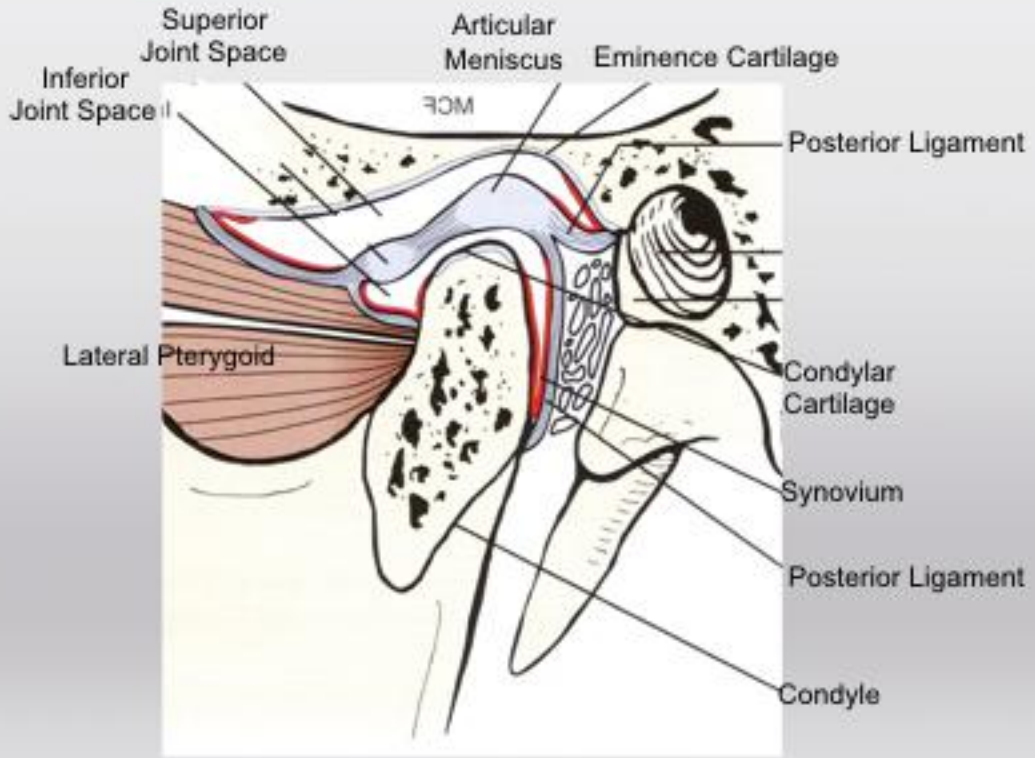

Left TMJ Coronal View

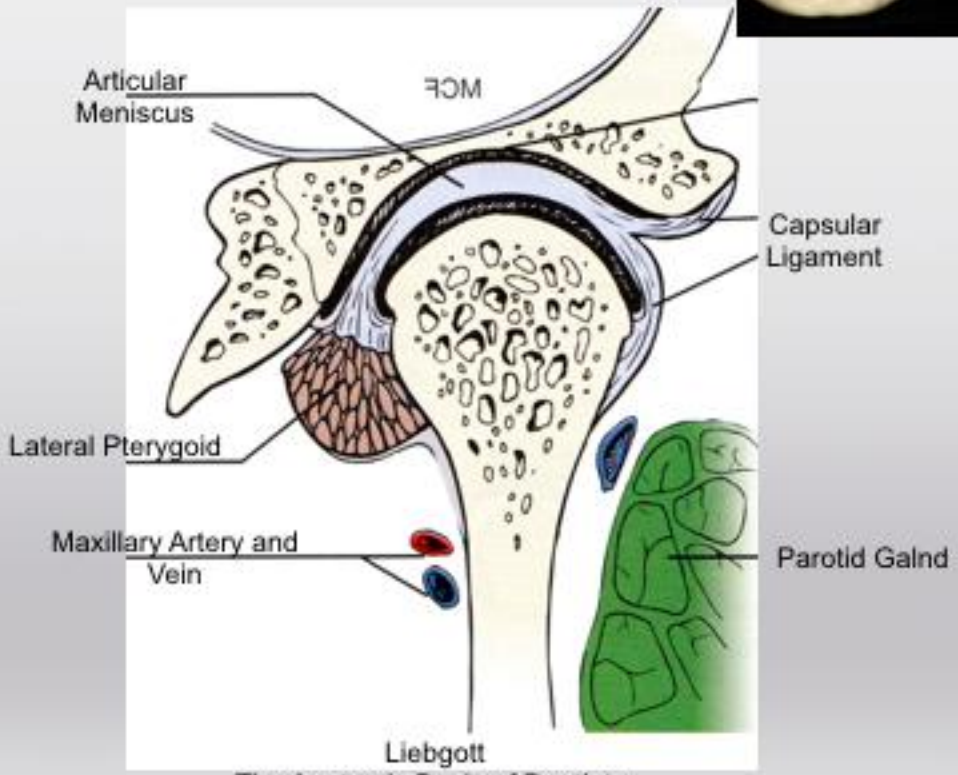

Liebgott
The Anatomic Basis of Dentistry

Normal TMJ

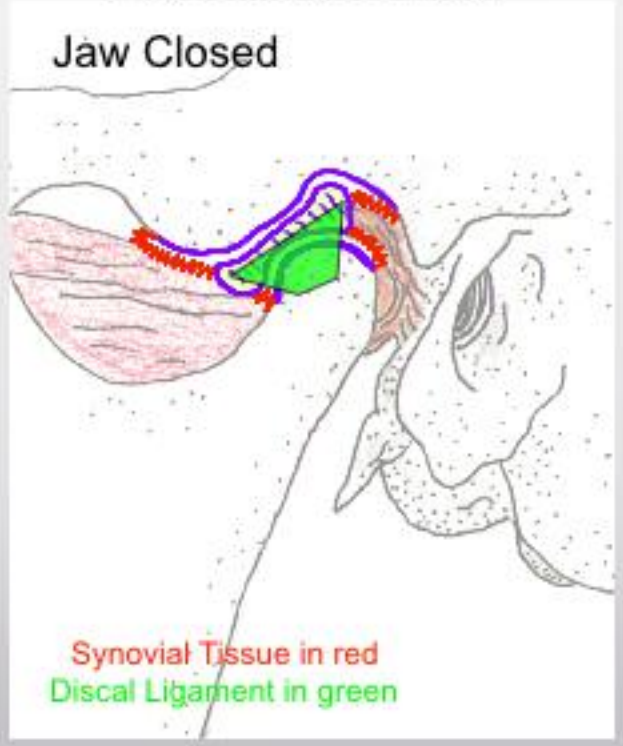

Discal Ligaments attach Disc to Condyle

Synovial Tissue
- Covers Front , Back and Sides
- Collapsed due to negative joint pressure

Disc viewed from above

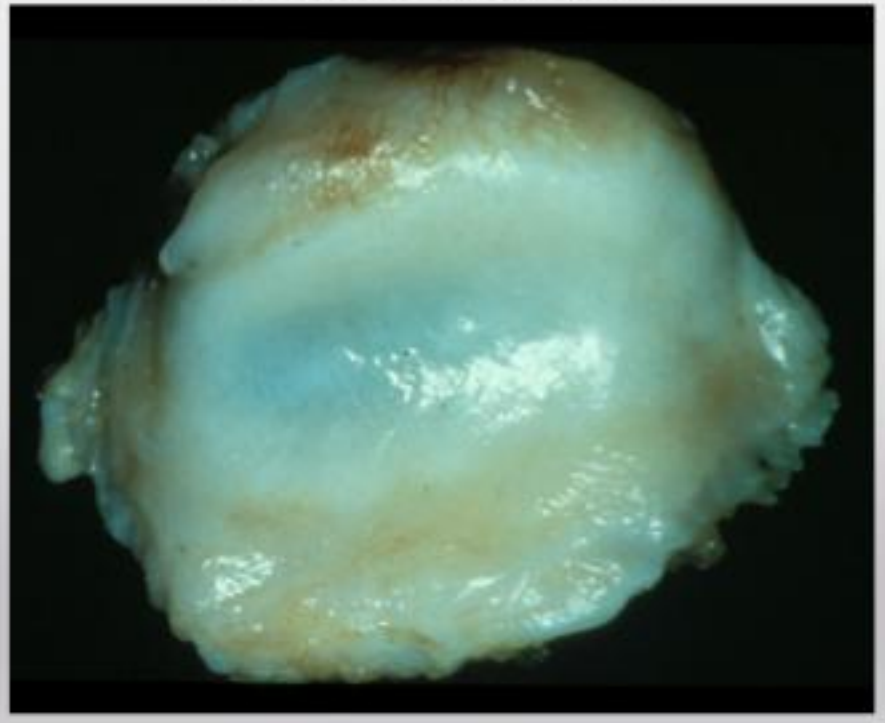

Photo Courtesy of Dr Henry Gremillion

Damaged TMJ- Anteriorly Dislocated Disc

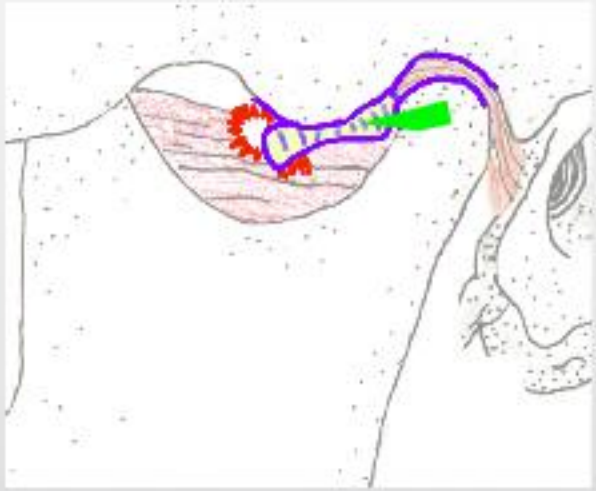

Torn or stretched Meniscal ligaments

Anterior Dislocated Disc

Damaged Synovium

Retrodiscal Tissue pulled up and over the condyle
- Retrodiscal tissue in direct contact with fibrocartilage
- Major Increase in friction
- Retrodiscal tissue adapts into fibrous "pseudodisc"

85% of all damaged joints adapt favorably without treatment

Cartilage sliding on tissue creates vibrations that can be detected

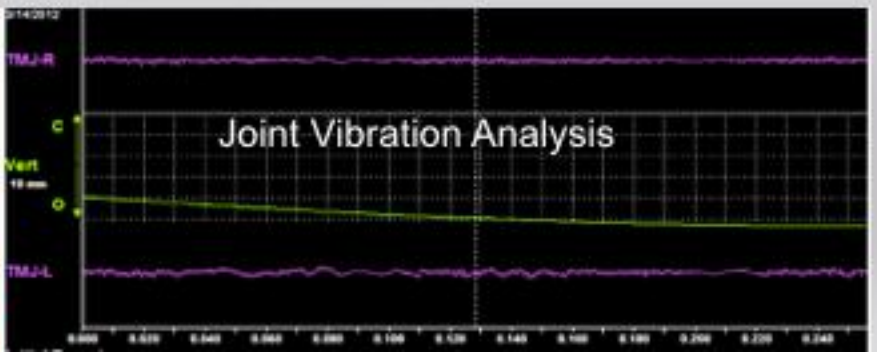

Dr. Mark Piper's Classification

Left TMJ

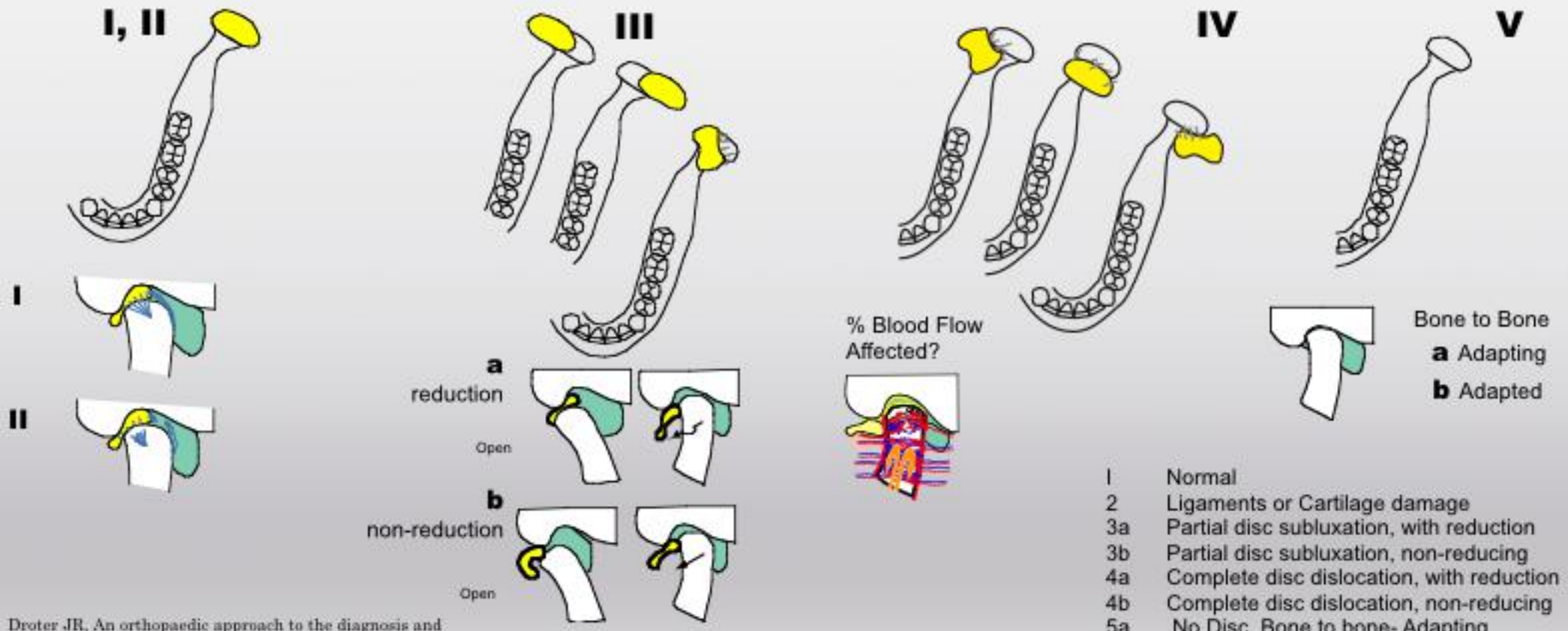

I	Normal
2	Ligaments or Cartilage damage
3a	Partial disc subluxation, with reduction
3b	Partial disc subluxation, non-reducing
4a	Complete disc dislocation, with reduction
4b	Complete disc dislocation, non-reducing
5a	No Disc, Bone to bone- Adapting
5b	No Disc, Bone to bone- Adapted

Droter JR, An orthopaedic approach to the diagnosis and treatment of disorders of the temporomandibular joint. Dent Today 2005 Nov;24(11):82, 84-8

Osteoarthrosis/Osteoarthritis

Healthy joints have no friction or wear.
Damaged joints have Friction. Friction causes wear.
OA is a wearing out of a joint which starts in cartilage.
Parafunction increases wear.

Normal

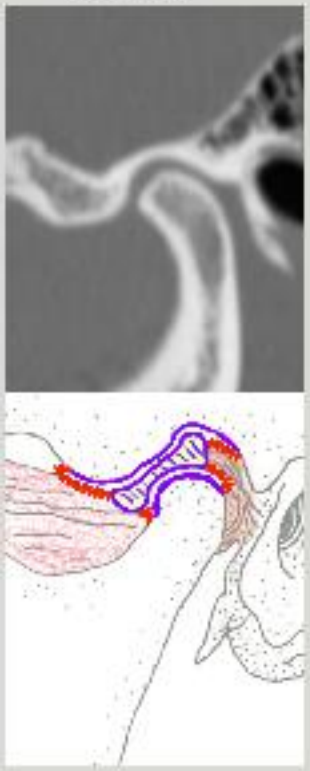

Early

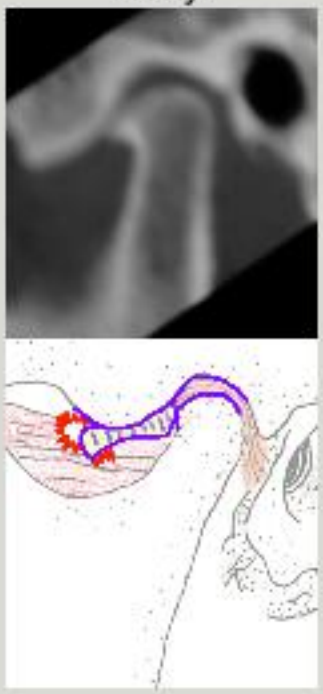

Early/ Moderate

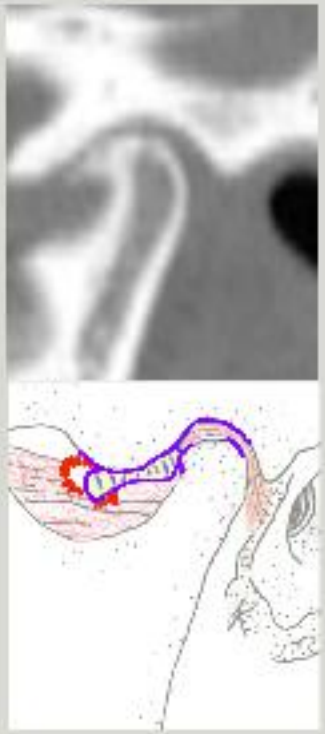

Moderate

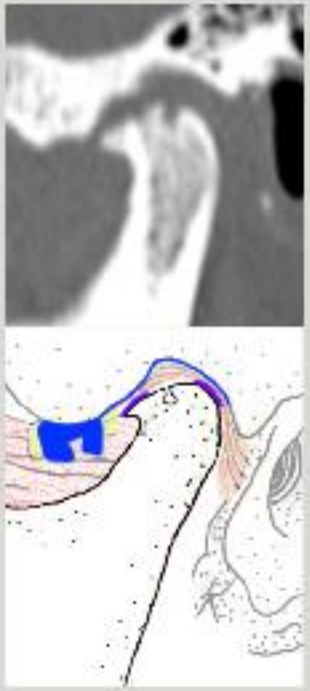

Severe OA, Eburnation

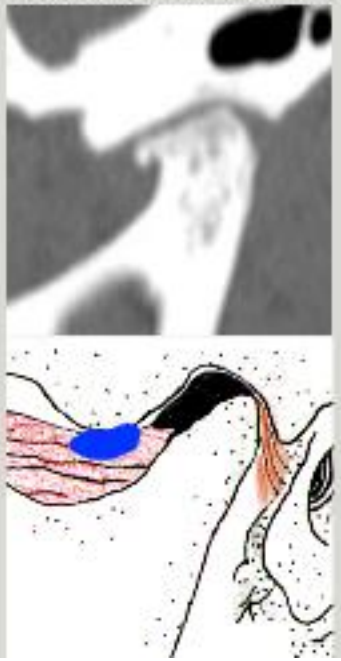

Representative examples of OA
in different patients

.....osis = disease process
.....itis = inflammation

Osteoarthr**osis** is a disease of cartilage, leading to progressive cartilage degeneration and changes in the bone.

Osteoarthr**itis** is an inflammatory phase of osteoarthrosis.

If it is not inflamed it is not **ITIS.**

Unfortunately the terms are mistakenly used interchangeably by doctors and in the literature.

If you effectively treat osteoarthritis with NSAIDs, you are now back to osteoarthrosis, which is not inflamed and will degrade at a much slower rate.

Diagnose OA

Osteoarthr**osis**

After early phase, CT scan shows bone alteration
Joint sounds, vibrations (roughness)- JVA is best
Non painful to joint palpation, loading
Friction in the joint causing wear

Osteoarthr**itis**

CT shows bone alteration
Inflammation present
Arthralgia
Need to palpate and load test the joint
Joint sounds roughness may be diminished by joint effusion
MRI STIR or T2 show inflammation

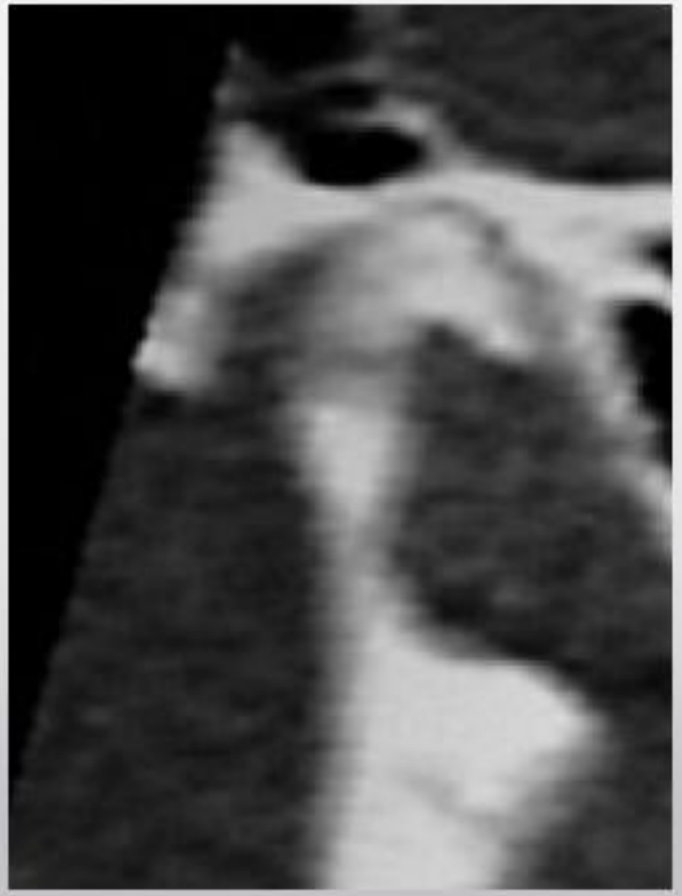

Adaptation Chronic Bilateral Osteoarthrosis

Mandible recedes Slowly
Teeth Move/ Adapt
Anterior Guidance gets steeper as Condylar Guidance get shallower

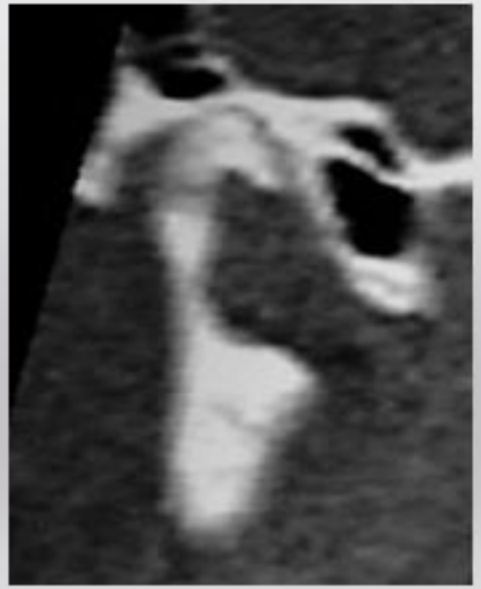

OA Right and Left Bone Loss
#8 Ankylosed

Treatment OA

Osteoarthr**osis**

- Best is no orthotic to allow for adaptation
- Minimize parafunction:
  - If sleep clenching: D-PAS
  - If sleep grinding due to airway: Airway device that allows jaw motion
- Light Force, Repetitive Motion: Promote synovial fluid flow
  - Jaw exercise: 20 reps, 5x a day jaw wiggle, open close
- Glucosamine 1500mg /Chondroitin 600 mg per day

Osteoarthr**itis**

- All of the above plus eliminate inflammation……..
  - NSAIDs 6-12 weeks
  - Cold Laser

- If still inflamed arthrocentesis with Platelet Rich Plasma (PRP)

MLS Laser
3x week for 3 weeks

My Core Belief

The TMJ is a synovial joint of the human body and will undergo the same disease processes as any other synovial joint

Understanding orthopedic medicine is the key to understanding joints, including the TMJ



Buy Salter's Orthopedic Textbook.
When you have a patient with specific disease (i.e. osteoarthritis), read that chapter.

Textbook of Disorders and Injuries of the Musculoskeletal System
Robert Salter MD

Maxillofacial Imaging
Larheim
Westesson

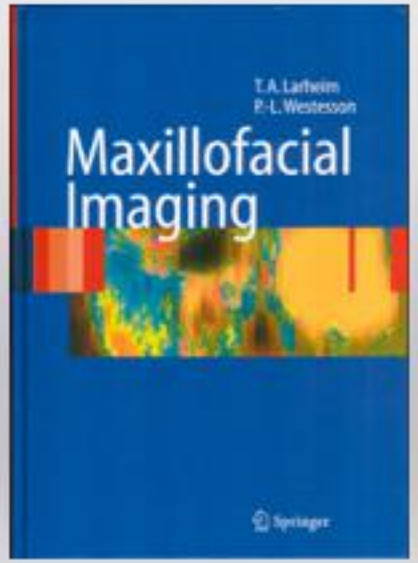

Basic Orthopedics

Joints are either
- Healthy or
- Damaged

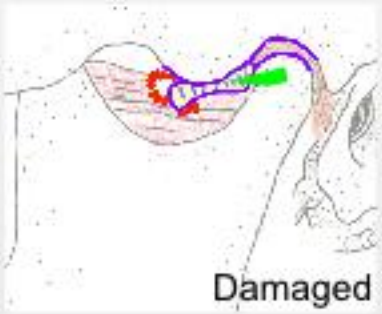

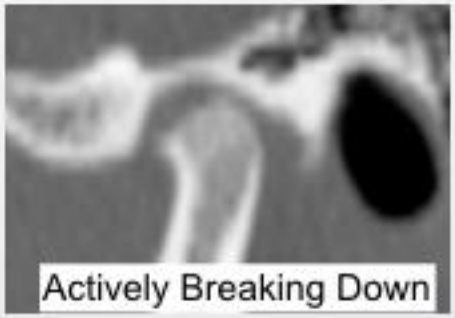

If damaged, joints will be either:
- Actively Breaking Down
- Adapting
- Adapted Favorably Structurally and Mechanically
- Adapted Unfavorably

Majority of damaged TMJs adapt favorably

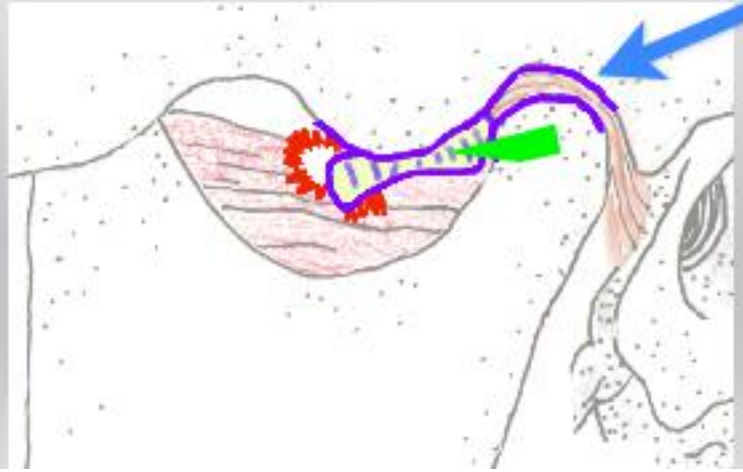

Posterior ligament, synovium, and retrodiscal tissue adapt to form a

Pseudo-disc

Tissue Fibrosis

Treating Common TMDs

Diagnosis	Pattern	Treatment
Sleep Clenching with anterior tooth contact inhibition	Sore masseters on waking Morning TMJ clicking that resolves Sleep D-PAS Relieves Symptoms	D-PAS Night Guard Time Release Vitamin C hs
Sleep Grinding , Airway Related	Worn Teeth Upper Airway Resistance	Mandibular Advancement Appliance
Occlusal Muscle Disharmony	Sore muscles on chewing Sore Lateral Pterygoid Day D-PAS Relieves Symptoms	Occlusal Adjustment
Osteoarthritis of TMJ	Arthralgia CBCT shows worn bone loss MRI T2, STIR ++	NSAID for 6-12 weeks Occlusal Adjustment Do not put in a night guard
Sprain Discal Ligament TMJ, Acute	Sudden onset pain TMJ Pain palpation TMJ Limited opening	Cold Laser, Ice 15 min 3x a day Rest, Soft diet, NSAID 7 days Anterior Reposition Orthotic 7 days
Hypoxia Induced Progressive Condylar Resorption	Progressive anterior open bite Missing condylar cortex on CT	Condylar distraction for 6 months Meloxicam, Doxycycline

Case EZ
Case MR

The Four Most Important Slides

John R Droter DDS
Annapolis, Maryland

www.jrdroter.com

TMDs- What are the choices? (190 Diagnoses, 7 Categories)

1. TMJ Damage

Adhesions and ankylosis of temporomandibular joint
Avascular Necrosis Mandibular Condyle
Cartilage Fibrillation, Mandibular Condyle, Fossa
Closed Lock, Jaw Cartilage, Acute
Closed Lock, Jaw Cartilage, Chronic
Closed Lock, Jaw Cartilage, Intermittent, Mechanically dysfunctional
Crush Injury Mandibular Condyle
Crystal arthropathy, unspecified, TMJ
Dislocation jaw cartilage due to injury, Sequela
Dislocation jaw cartilage with reduction, favorable adaptation, TMJ
Dislocation jaw cartilage without reduction, favorable adaptation, TMJ

Impingement Retrodiscal Tissue
Inflammatory Tissue Bone Resorption, TMJ Condyle
Loose Body (Joint Mice), TMJ
Malignant neoplasm of bones of skull and face
Open Lock TMJ, Recurring
Osteoarthritis TMJ, active degeneration
Osteoarthrosis- Inactive
Osteochondritis Dissecans TMJ
Osteolysis Mandibular Condyle, Active
Perforation Meniscus, TMJ
Perforation Pseudodisc, TMJ
Psoriatic Arthritis TMJ
Rheumatoid Arthritis Sero Negative TMJ

4. Cervical Damage

Cervical Vertebrae Alignment Dysfunction
Cervicocranial Syndrome
Muscle Guarding due Neck Instability
Trigger Point Neck Muscle with Referred Pain
Trigger Point Neck Muscle, Localized Pain

5. Parafunction

Without ruling out occlusal problems and parafunction it is hard to figure out the rest.

Muscle Bracing Pain Avoidance
Muscle Bracing TMJ stabilization
Muscle Bracing Airway **Patency** (with Tongue)
Muscle Contracture Fibrosis Lateral Pterygoid
Muscle Contracture Fibrosis Masseter, Medial Pterygoid, Temporalis
Muscle Fatigue Overuse
Muscle Hypertrophy TMJ Muscles

3. Cranial Alignment/Occlusion

Cranial Distortion / Misalignment
Hemifacial Hypoplasia
Hyper Occlusal Awareness
Iatrogenic Orthotic Damage
Malocclusion Anterior Open Bite
Malocclusion Centric occlusion MaxIC discrepancy
Malocclusion Deep Bite
Malocclusion due to mouth breathing
Malocclusion due to TMJ bone loss
Malocclusion due to tongue, lip or finger habits
Malocclusion Insufficient anterior occlusal guidance
Malocclusion lack of posterior occlusal support
Malocclusion Posterior Openbite Bilateral
Malocclusion Posterior Openbite Unilateral
Malocclusion unspecified

Malposition /Misalignment: Maxilla, Temporal Bone, Mandible
Mandibular asymmetry
Mandibular hyperplasia
Mandibular hypoplasia
Mandibular Retrognathia
Maxillary asymmetry
Maxillary hyperplasia
Maxillary hypoplasia
Maxillary Retrognathia
Occlusal Adaptation, Favorable
Occlusal Dependency for Joint Stabilization/ Proprioception
Tooth Intrusion
Tooth Supereruption

6. Whole Body / Systemic

Lyme Disease Arthritis
Magnesium Deficiency
Obstructive Sleep Apnea
Osteoporosis without current pathological fracture
Pathological Habitual Movement Pattern
Postural Disharmony Standing
Postural Disharmony Walking
Postural Forward Head Position
Upper Airway Resistance, UARS

7. Other

Nerve Entrapment Masseteric Nerve due to Masseteric hypertonicity
Neuroma Trigeminal Nerve
Obsessive-Compulsive Personality Disorder
Other
Otitis Ear Infection
Pain disorder exclusively related to psychological factors. Somatoform pain disorder
Pain disorder with related psychological factors

Facial Pain Diagnosis

Diagnostic Tools

1 Written and Oral History
2 Observation
3 Physical Exam
   Muscle Palpation
   Joint Palpation
   Joint Auscultation
   Joint Motion
4 Dx Orthotic- D-PAS
5 Sleep Airway Screening
6 CT Scan
7 MRI

Occlusion: CR Mounted Study Models
Complete Dental Exam
Clinical Photographs
Dx Blocks
Blood test
Dx Orthotics- Brux Checker, CR Orthotic

<u>Biometrics</u>
Joint Vibration
Jaw Tracker
Electromyography
T-Scan

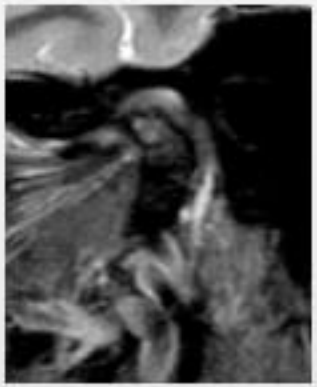

Treating Common TMDs

Diagnosis	Pattern	Treatment
Sleep Clenching with anterior tooth contact inhibition	Sore masseters on waking Morning TMJ clicking that resolves Sleep D-PAS Relieves Symptoms	D-PAS Night Guard Time Release Vitamin C hs
Sleep Grinding , Airway Related	Worn Teeth Upper Airway Resistance	Mandibular Advancement Appliance
Occlusal Muscle Disharmony	Sore muscles on chewing Sore Lateral Pterygoid Day D-PAS Relieves Symptoms	Occlusal Adjustment
Osteoarthritis of TMJ	Arthralgia CBCT shows worn bone loss MRI T2, STIR ++	NSAID for 6-12 weeks Occlusal Adjustment Do not put in a night guard
Sprain Discal Ligament TMJ, Acute	Sudden onset pain TMJ Pain palpation TMJ Limited opening	Cold Laser, Ice 15 min 3x a day Rest, Soft diet, NSAID 7 days Anterior Reposition Orthotic 7 days
Hypoxia Induced Progressive Condylar Resorption	Progressive anterior open bite Missing condylar cortex on CT	Condylar distraction for 6 months Meloxicam, Doxycycline

Eats flies.
Dates a pig.
Hollywood
star.
LIVE YOUR DREAMS
Pass It On.
VALUES.COM THE FOUNDATION FOR A BETTER LIFE

Know Yourself
Know Your Work
Know Your Patient
Apply Your Knowledge
LD Pankey Institute
Write your Dream

Know Yourself
Know Your Work
Know Your Patient
Apply Your Knowledge
LD Pankey Institute
Write your Dream

TMD from Start to Finish: Helping the patients in YOUR practice

LD Pankey Institute, Key Biscayne FL
October 21-25, 2018

John R Droter, DDS
Ed Zebovitz, DDS
Glen Kidder, DDS

Experiential Learning: Bring you own cases
- Expert advise on your cases
- See similar cases start to finish

Learn a systematic approach for diagnosing
Choosing the correct treatment
Hands on Diagnosing of TMD cases
Improve MRI and CT scan interpretation
Overcoming Obstacles to Comfort
Non-Surgical Rehabilitation verses Surgery

Class size limited to 16
Call Jackie at (305) 428-5500
www.pankey.org

Cool free stuff at www.jrdroter.com

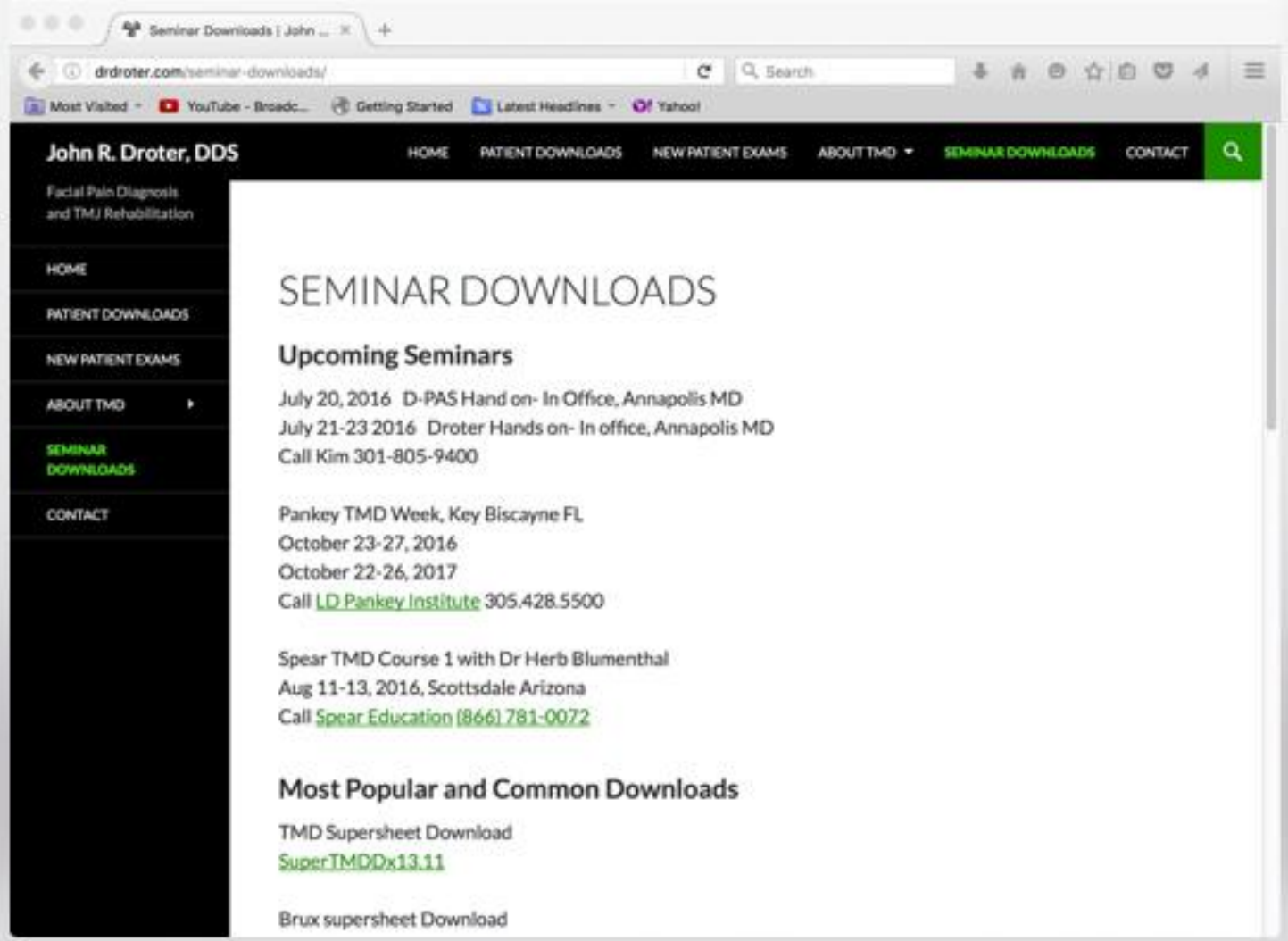

E2

Best Dentist in Neighborhood

Pankey Study Club
Baltimore 1994

My Mentor: Dr Guy Haddix

I met Dr. Guy Haddix 1992
LD Pankey Institute C4
Joined his Mastermind Group

"Become a good observer"

Non Surgical TMJ rehabilitation
CT scans in Coronal view
Condyles down for healing
Condyles UP (seated) for stability

Great Observer

3 loads, total 7.5 tons
mounted models in pickup truck

MEDIOCRITY

It Takes a Lot Less Time
and Most People Won't Notice the Difference
Until It's Too Late.

:-(

DESPAIR, INC.

He took the road less traveled.

But he brought a helmet and a tiny shopping cart.
And that made all the difference.

Know Yourself
Know Your Work
Know Your Patient
Apply Your Knowledge
LD Pankey Institute
Write your Dream