TMD for the GP
Grinding and Clenching

John R Droter DDS
Annapolis, Maryland

www.jrdroter.com

John R Droter, DDS

To get todays lecture slides:
go to www.jrdroter.com

Seminar Download

BiTown Study Club

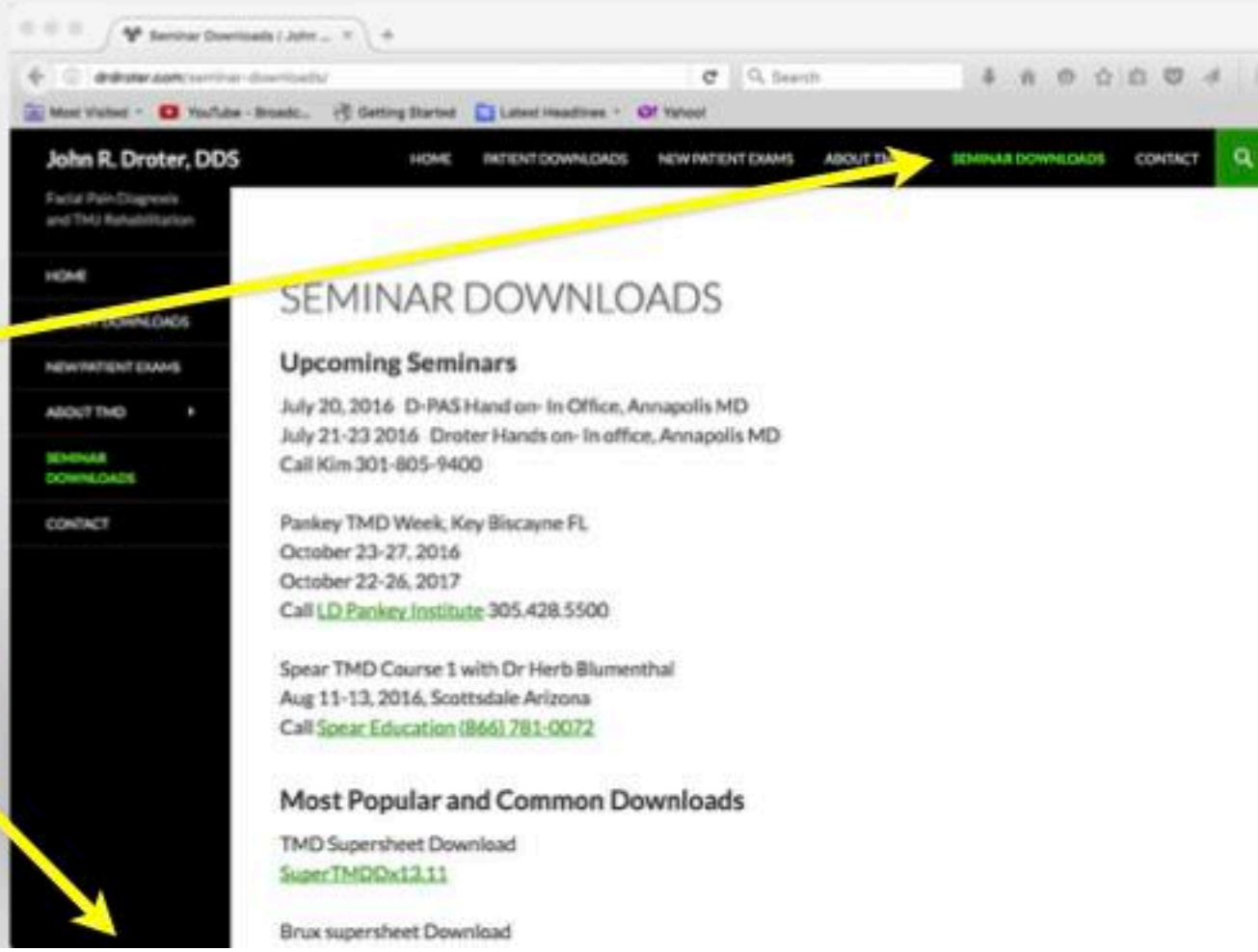

Hello. I am:

John R Droter DDS
Annapolis, Maryland

Milestones

Need to publish.....

Visiting Faculty Spear Education 2013

Visiting Faculty LD Pankey Institute 2008

Visiting Faculty Orthodontic Program
Washington Hospital Center 2000

On staff AAMC: Orthopedic Rounds
In OR for TMJ Surgery

Devoted Facial Pain Practice 1996
(No Hygiene to Check!!)

CT and MRI Imaging Joints 1992
Guy Haddix, DDS: Mentor
(3,100 images and rising)

Post Grad CE- GPR, LD Pankey Institute, Dawson, Mahan, Gremillion, Spear, Kois

Disclosures:

Ski Coach for National Ski Patrol
Level 3 Certified Profession Ski Instructors of America

Atomic Skis- Sponsored.
I do benefit financially.

LD Pankey Institute- I am paid
a small honorarium for lectures

Spear Education- Paid
honorarium for lectures

All of my slides have been altered with
respect to cropping and exposure.
None have been "photoshopped" to misrepresent reality

I have chosen the most representative slice of and MRI and CT
scans to best represent what you would see if viewing all images

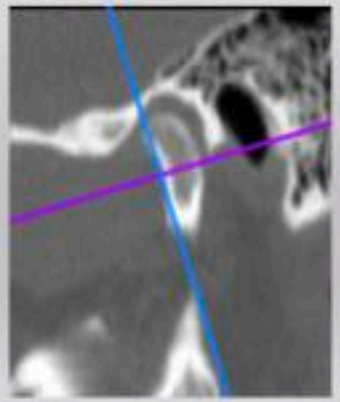

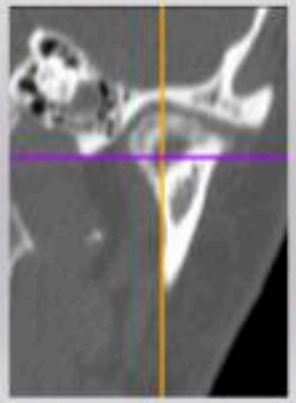

You have TMD patients in your practice



Headaches



Fatigued

16 yo F

Parafunctional Grinding

Parafunctional Clenching

Why is TMD So Confusing?

John R Droter DDS
Annapolis, Maryland

The Diagnostic Process

When diagnosing and treating facial pain,
we have entered the world of medicine.

Think!!

Differential Diagnosis
All the choices

Diagnostic tests (Observations)
Narrow down the choices

Working Diagnosis
Treating as if

Not completely resolved

Final Diagnosis
Only after problem resolved

Always make a differential diagnostic list
Ask, " It appears to be this, but what else could it be?
Be aware you are blinded by your beliefs

Differential Diagnosis
Diagnostic Boxes: Pattern Recognition

"My Tooth Hurts"

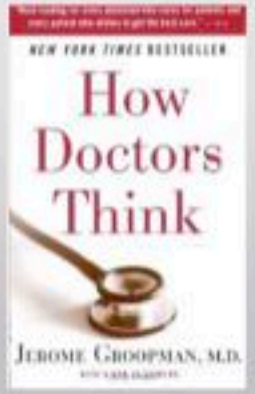

Differential Diagnosis
Diagnostic Boxes: Pattern Recognition

"My Tooth Hurts"

- Reversible Pulpitis secondary to caries
- Irreversible Pulpitis secondary to caries
- Pulpitis secondary to split tooth
- Pulpal necrosis
- Referred Pain from Muscle Trigger Point
- Sinus Infection
- Sympathetic Mediated Pain
- Neuroma

- Periodontal Infection
- Inflamed Tissue secondary to popcorn husk
- Aphthous Ulcer

- Periodontal ligament inflammation secondary to Occlusal Trauma
- Pulpits secondary to Occlusal Trauma
- Other

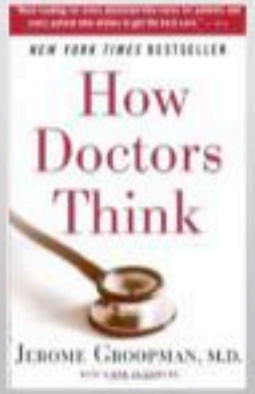

Referred Pain

Convergence

More primary sensory neurons than secondary neurons that travel to brain

50:1 Ratio

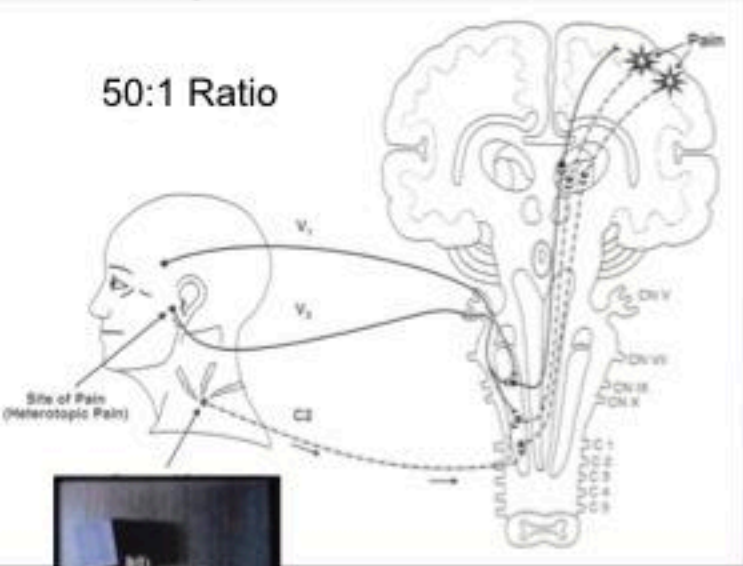

"Bells Orofacial Pain"
Jefery Okeson

Trigger Points

Contracted mass of actin, myosin and histamine

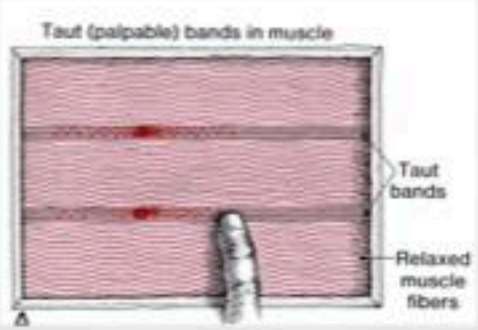

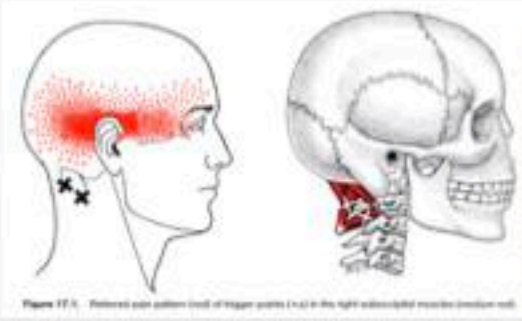

"The Trigger Point Manual"
Janet Travell, MD

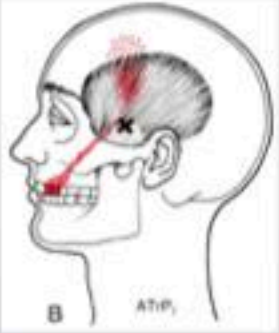

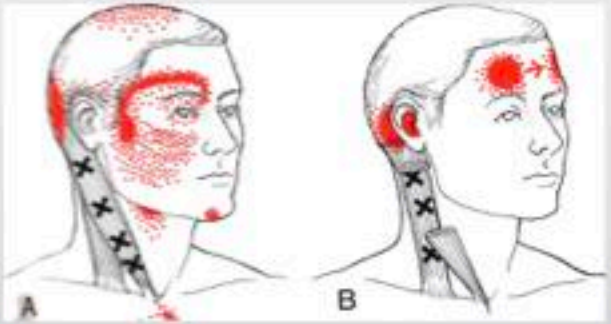

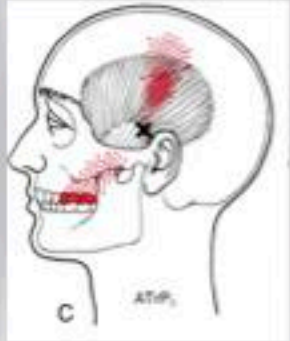

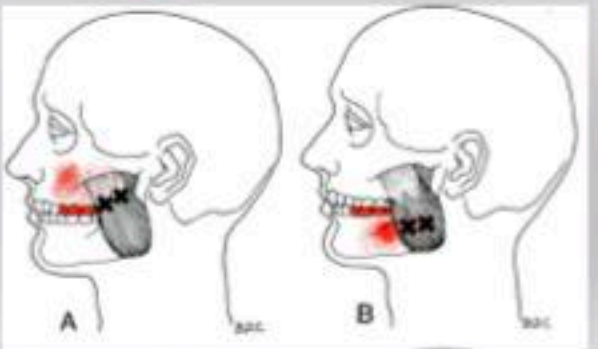

Differential Diagnosis
Diagnostic Boxes: Pattern Recognition

"My Tooth Hurts"

- Reversible Pulpitis secondary to caries
- Irreversible Pulpitis secondary to caries
- Pulpitis secondary to split tooth
- Referred Pain from Muscle Trigger Point

- Periodontal Infection
- Inflamed Tissue secondary to popcorn husk
- Aphthous Ulcer

- Periodontal ligament inflammation secondary to Occlusal Trauma
- Pulpits secondary to Occlusal Trauma
- Other

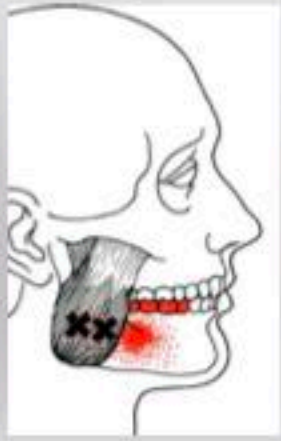

"How Doctors Think", by Jerome E. Groopman

Diagnose by Pattern Recognition
Tendency to make patients fit what we know
Ignore signs and symptoms that do not fit

Always make a differential diagnostic list
Ask, " It appears to be this, but what else could it be?
Be aware you are blinded by your beliefs

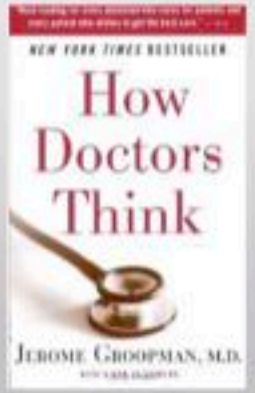

TMJ/TMD Confusion

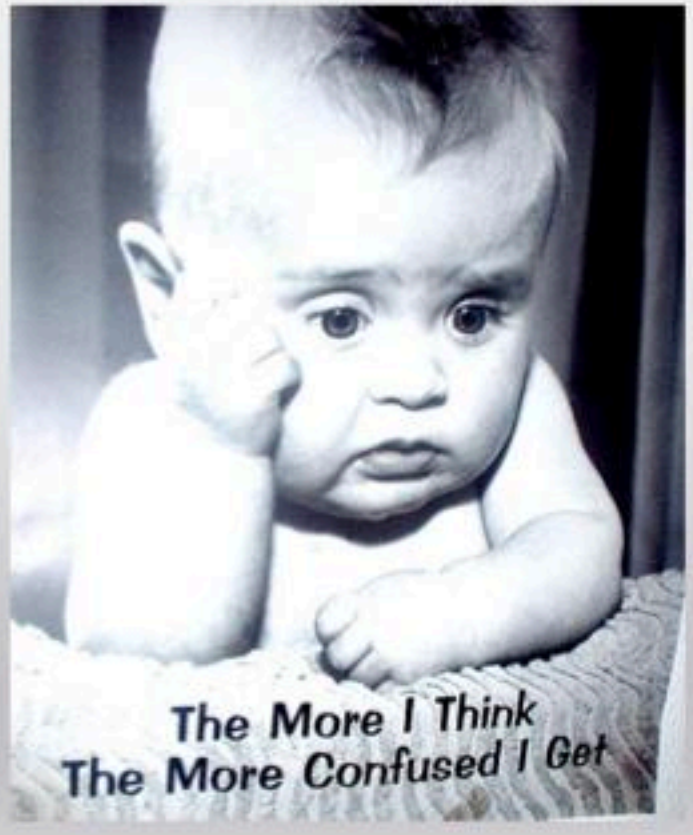

Dogmatic
Arguments

Why Confusion?

TMD/TMJ
Symptoms based

Not One Disease

Temporomandibular Disorders (TMD) is an umbrella term covering any condition causing pain or dysfunction in the temporomandibular joint, muscles of mastication, trigeminal nerve, facial nerve, and associated head and neck musculoskeletal and neural structures.
Craniomandibular Disorders would be a better term (CMD).

TMDs- What are the choices? (190 Diagnoses, 7 Categories)

1. TMJ Damage

Adhesions and ankylosis of temporomandibular joint
Avascular Necrosis Mandibular Condyle
Cartilage Fibrillation, Mandibular Condyle, Fossa
Closed Lock, Jaw Cartilage, Acute
Closed Lock, Jaw Cartilage, Chronic
Closed Lock, Jaw Cartilage, Intermittent, Mechanically dysfunctional
Crush Injury Mandibular Condyle
Crystal arthropathy, unspecified, TMJ
Dislocation jaw cartilage due to injury, Sequela
Dislocation jaw cartilage with reduction, favorable adaptation, TMJ
Dislocation jaw cartilage without reduction, favorable adaptation, TMJ
Effusion, TMJ
Impingement Retrodiscal Tissue
Inflammatory Tissue Bone Resorption, TMJ Condyle
Loose Body (Joint Mice), TMJ
Malignant neoplasm of bones of skull and face
Open Lock TMJ, Recurring
Osteoarthritis TMJ, active degeneration
Osteoarthrosis- Inactive
Osteochondritis Dissecans TMJ
Osteolysis Mandibular Condyle, Active
Perforation Meniscus, TMJ
Perforation Pseudodisc, TMJ
Psoriatic Arthritis TMJ
Rheumatoid Arthritis Sero Negative TMJ

2. Muscles of the TMJ

Dystonia
Habitual posture forward mandible
Hemifacial Muscle spasm
Inhibitory Reflex Dysfunction, Periodontal Ligament Masseter Muscle
Muscle Atrophy, TMJ
Muscle Bracing Neck Stabilization
Muscle Bracing Pain Avoidance
Muscle Bracing TMJ stabilization
Muscle Bracing Airway **Patency** (with Tongue)
Muscle Contracture Fibrosis Lateral Pterygoid
Muscle Contracture Fibrosis Masseter, Medial Pterygoid, Temporalis
Muscle Fatigue Overuse
Muscle Hypertrophy TMJ Muscles

3. Cranial Alignment/Occlusion

Cranial Distortion / Misalignment
Hemifacial Hypoplasia
Hyper Occlusal Awareness
Iatrogenic Orthotic Damage
Malocclusion Anterior Open Bite
Malocclusion Centric occlusion MaxIC discrepancy
Malocclusion Deep Bite
Malocclusion due to mouth breathing
Malocclusion due to TMJ bone loss
Malocclusion due to tongue, lip or finger habits
Malocclusion Insufficient anterior occlusal guidance
Malocclusion lack of posterior occlusal support
Malocclusion Posterior Openbite Bilateral
Malocclusion Posterior Openbite Unilateral
Malocclusion unspecified
Malposition /Misalignment: Maxilla, Temporal Bone, Mandible
Mandibular asymmetry
Mandibular hyperplasia
Mandibular hypoplasia
Mandibular Retrognathia
Maxillary asymmetry
Maxillary hyperplasia
Maxillary hypoplasia
Maxillary Retrognathia
Occlusal Adaptation, Favorable
Occlusal Dependency for Joint Stabilization/ Proprioception
Tooth Intrusion
Tooth Supereruption

4. Cervical Damage

Cervical Vertebrae Alignment Dysfunction
Cervicocranial Syndrome
Muscle Guarding due Neck Instability
Trigger Point Neck Muscle with Referred Pain
Trigger Point Neck Muscle, Localized Pain

5. Parafunction

Excessive Tooth Wear, Damage
Hypersensitive Occlusion
Parafunctional Clenching Teeth, Awake
Parafunctional Clenching Teeth, Sleep
Parafunctional Grinding Teeth, Awake
Parafunctional Grinding Teeth, Sleep
Parafunctional Clench/Grind Wiggle
Parafunctional Tongue Bracing avoiding uncomfortable tooth contact
Parafunctional Tongue Bracing Neck stabilization
Parafunctional Tongue Bracing to maintain Airway
Parafunctional Tongue Bracing unknown cause

6. Whole Body / Systemic

Lyme Disease Arthritis
Magnesium Deficiency
Obstructive Sleep Apnea
Osteoporosis without current pathological fracture
Pathological Habitual Movement Pattern
Postural Disharmony Standing
Postural Disharmony Walking
Postural Forward Head Position
Upper Airway Resistance, UARS

7. Other

Nerve Entrapment Masseteric Nerve due to Masseteric hypertonicity
Neuroma Trigeminal Nerve
Obsessive-Compulsive Personality Disorder
Other
Otitis Ear Infection
Pain disorder exclusively related to psychological factors. Somatoform pain disorder
Pain disorder with related psychological factors
Peripheral Sensitization

1. TMD: TMJ Damage and Diseases

Adhesions and ankylosis of temporomandibular joint
Avascular Necrosis Mandibular Condyle
Cartilage Fibrillation, Mandibular Condyle, Fossa
Closed Lock, Jaw Cartilage, Acute
Closed Lock, Jaw Cartilage, Chronic
Closed Lock, Jaw Cartilage, Intermittent, Mechanically dysfunctional
Crush Injury Mandibular Condyle
Crystal arthropathy, unspecified, TMJ
Dislocation jaw cartilage due to Injury, Sequela
Dislocation jaw cartilage with reduction, favorable adaptation, TMJ
Dislocation jaw cartilage without reduction, favorable adaptation, TMJ
Effusion, TMJ
Fracture of subcondylar process of mandible
Gout, TMJ
Growth Disturbance Prepuberty due to TMJ damage
Hemarthrosis TMJ, Traumatic
Hyperplasia Mandibular Condyle,
Hypoplasia Mandibular Condyle
Hypoxia Reperfusion Injury, TMJ Cartilage Damage
Hypoxic Progressive Condylar Resorption
Impingement Retrodiscal Tissue
Inflammatory Tissue Bone Resorption, TMJ Condyle
Loose Body (Joint Mice), TMJ
Malignant neoplasm of bones of skull and face
Open Lock TMJ, Recurring
Osteoarthritis TMJ, active degeneration
Osteoarthrosis- Inactive
Osteochondritis Dissecans TMJ
Osteolysis Mandibular Condyle, Active
Perforation Meniscus, TMJ
Perforation Pseudodisc, TMJ
Psoriatic Arthritis TMJ
Rheumatoid Arthritis Sero Negative TMJ
Rheumatoid Arthritis TMJ
Sprain Discal Ligament TMJ, acute with joint edema
Subluxation on Loading, TMJ
Subluxation on Movement, TMJ
Synovial Cyst (Ganglion Cyst)
Synovial Hyperplasia
Synovitis

My Core Belief

The TMJ is a synovial joint of the human body and will undergo the same disease processes as any other synovial joint

Understanding orthopedic medicine is the key to understanding joints, including the TMJ



Buy Salter's Orthopedic Textbook.
When you have a patient with specific disease (i.e. osteoarthritis), read that chapter.

Textbook of Disorders and Injuries of the Musculoskeletal System
Robert Salter MD

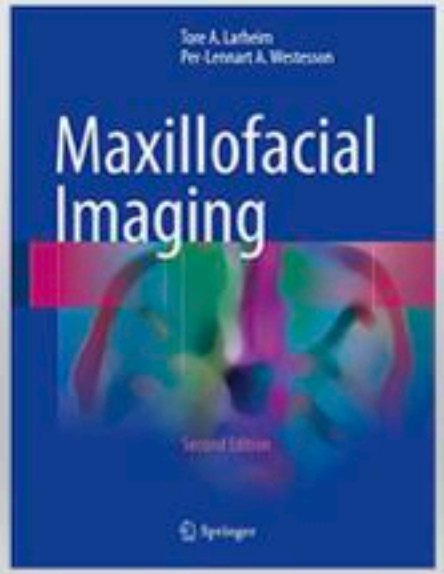

Maxillofacial Imaging
Larheim
Westesson

Diagnosis and Treating Common TMDs in a GP

John R Droter DDS
Annapolis, Maryland

www.jrdroter.com

TMDs- What are the choices? (190 Diagnoses, 7 Categories)

1. TMJ Damage

Adhesions and ankylosis of temporomandibular joint
Avascular Necrosis Mandibular Condyle
Cartilage Fibrillation, Mandibular Condyle, Fossa
Closed Lock, Jaw Cartilage, Acute
Closed Lock, Jaw Cartilage, Chronic
Closed Lock, Jaw Cartilage, Intermittent, Mechanically dysfunctional
Crush Injury Mandibular Condyle
Crystal arthropathy, unspecified, TMJ
Dislocation jaw cartilage due to injury, Sequela
Dislocation jaw cartilage with reduction, favorable adaptation, TMJ
Dislocation jaw cartilage without reduction, favorable adaptation, TMJ
Effusion, TMJ
Impingement Retrodiscal Tissue
Inflammatory Tissue Bone Resorption, TMJ Condyle
Loose Body (Joint Mice), TMJ
Malignant neoplasm of bones of skull and face
Open Lock TMJ, Recurring
Osteoarthritis TMJ, active degeneration
Osteoarthrosis- Inactive
Osteochondritis Dissecans TMJ
Osteolysis Mandibular Condyle, Active
Perforation Meniscus, TMJ
Perforation Pseudodisc, TMJ
Psoriatic Arthritis TMJ
Rheumatoid Arthritis Sero Negative TMJ

2. Muscles of the TMJ

Dystonia
Habitual posture forward mandible
Hemifacial Muscle spasm
Inhibitory Reflex Dysfunction, Periodontal Ligament Masseter Muscle
Muscle Atrophy, TMJ
Muscle Bracing Neck Stabilization
Muscle Bracing Pain Avoidance
Muscle Bracing TMJ stabilization
Muscle Bracing Airway **Patency** (with Tongue)
Muscle Contracture Fibrosis Lateral Pterygoid
Muscle Contracture Fibrosis Masseter, Medial Pterygoid, Temporalis
Muscle Fatigue Overuse
Muscle Hypertrophy TMJ Muscles

3. Cranial Alignment/Occlusion

Cranial Distortion / Misalignment
Hemifacial Hypoplasia
Hyper Occlusal Awareness
Iatrogenic Orthotic Damage
Malocclusion Anterior Open Bite
Malocclusion Centric occlusion MaxIC discrepancy
Malocclusion Deep Bite
Malocclusion due to mouth breathing
Malocclusion due to TMJ bone loss
Malocclusion due to tongue, lip or finger habits
Malocclusion Insufficient anterior occlusal guidance
Malocclusion lack of posterior occlusal support
Malocclusion Posterior Openbite Bilateral
Malocclusion Posterior Openbite Unilateral
Malocclusion unspecified
Malposition /Misalignment: Maxilla, Temporal Bone, Mandible
Mandibular asymmetry
Mandibular hyperplasia
Mandibular hypoplasia
Mandibular Retrognathia
Maxillary asymmetry
Maxillary hyperplasia
Maxillary hypoplasia
Maxillary Retrognathia
Occlusal Adaptation, Favorable
Occlusal Dependency for Joint Stabilization/ Proprioception
Tooth Intrusion
Tooth Supereruption

4. Cervical Damage

Cervical Vertebrae Alignment Dysfunction
Cervicocranial Syndrome
Muscle Guarding due Neck Instability
Trigger Point Neck Muscle with Referred Pain
Trigger Point Neck Muscle, Localized Pain

5. Parafunction

Excessive Tooth Wear, Damage
Hypersensitive Occlusion
Parafunctional Clenching Teeth, Awake
Parafunctional Clenching Teeth, Sleep
Parafunctional Grinding Teeth, Awake
Parafunctional Grinding Teeth, Sleep
Parafunctional Clench/Grind Wiggle
Parafunctional Tongue Bracing avoiding uncomfortable tooth contact
Parafunctional Tongue Bracing Neck stabilization
Parafunctional Tongue Bracing to maintain Airway
Parafunctional Tongue Bracing unknown cause

6. Whole Body / Systemic

Lyme Disease Arthritis
Magnesium Deficiency
Obstructive Sleep Apnea
Osteoporosis without current pathological fracture
Pathological Habitual Movement Pattern
Postural Disharmony Standing
Postural Disharmony Walking
Postural Forward Head Position
Upper Airway Resistance, UARS

7. Other

Nerve Entrapment Masseteric Nerve due to Masseteric hypertonicity
Neuroma Trigeminal Nerve
Obsessive-Compulsive Personality Disorder
Other
Otitis Ear Infection
Pain disorder exclusively related to psychological factors. Somatoform pain disorder
Pain disorder with related psychological factors
Peripheral Sensitization

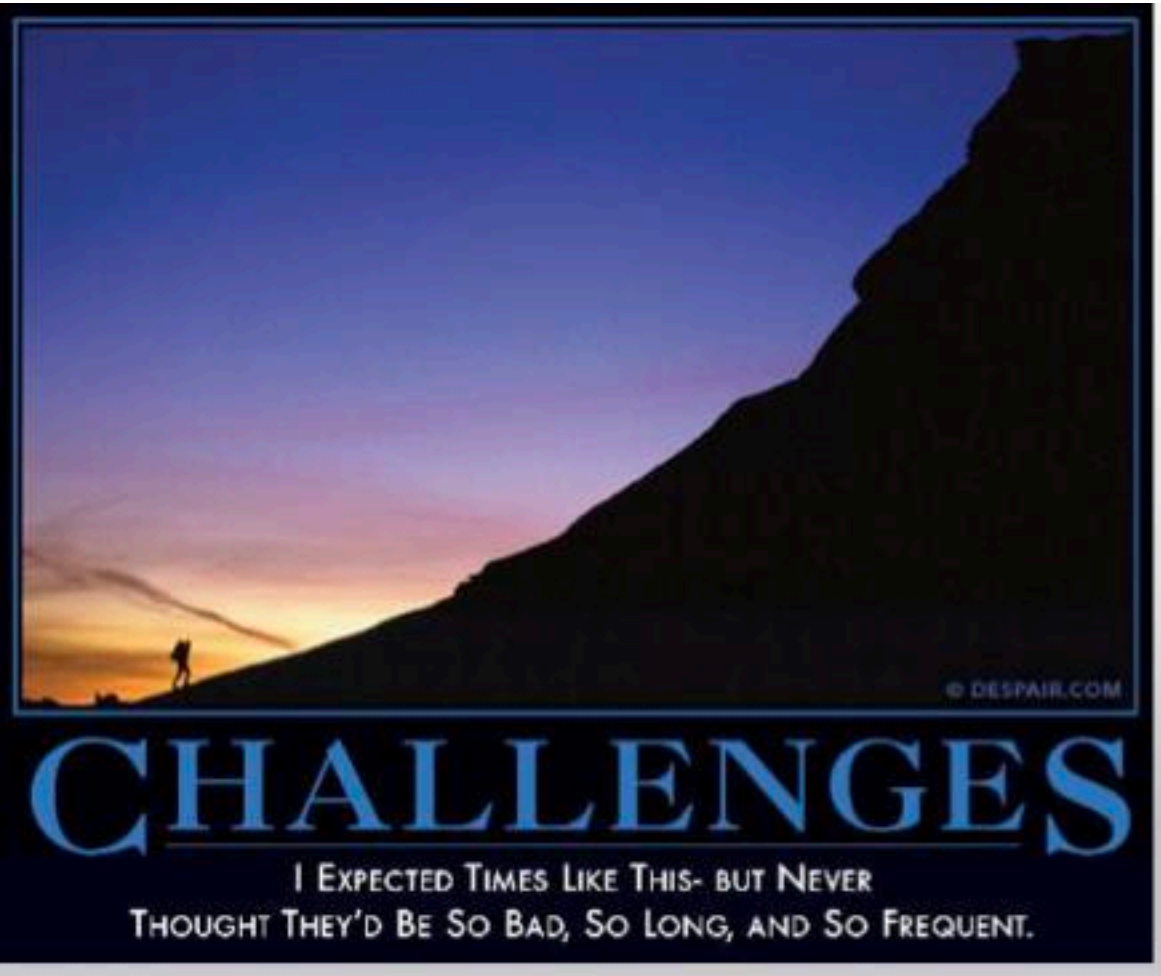

despair.com

Don't **Despair**, you have choices:

Pretend is does not matter
or
Begin to learn a few new exam skills, a few diagnostic patterns, a few new treatments. Have a box called other.

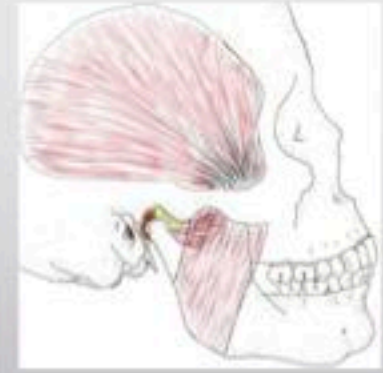

Sleep Clenching

Osteoarthritis

Acute Sprain of TMJ

Occlusal Muscle Disharmony

Upper Airway Resistance

Other

Treating Common TMDs

Diagnosis	Pattern	Treatment
Sleep Clenching with anterior tooth contact inhibition	Sore masseters on waking Morning TMJ clicking that resolves Sleep D-PAS Relieves Symptoms	D-PAS Night Guard Time Release Vitamin C hs
Occlusal Muscle Disharmony	Sore muscles when chewing Sore Lateral Pterygoid, Headaches Day orthotic relieves symptoms	Occlusal Adjustment
Osteoarthritis of TMJ	Arthralgia CBCT shows worn bone loss MRI T2, STIR ++	NSAID for 6-12 weeks Occlusal Adjustment Do not put in a night guard
Hypoxia Induced Progressive Condylar Resorption	Progressive anterior open bite Missing condylar cortex on CT	Condylar distraction for 6 months Meloxicam, Doxycycline
Sprain Discal Ligament TMJ, Acute	Sudden onset pain TMJ Pain palpation TMJ Limited opening	Cold Laser, Ice 15 min 3x a day Rest, Soft diet, NSAID 7 days Anterior Reposition Orthotic 7 days
Sleep Grinding , Airway Related	Worn Teeth Upper Airway Resistance	Nasal breathing, open airway Decrease body Inflammation

What are Clenching and Grinding?

John R Droter DDS
Annapolis, Maryland

Detailed

Which Occlusal Orthotic for Bruxing?

Upper Palatal Anterior Stop Orthotic

Upper Hard CR Orthotic

Lower Hard CR Orthotic

MyTap Mandibular Advancement Appliance

What is your definition of Bruxing?

A diurnal or nocturnal parafunctional activity that includes clenching, bracing, gnashing and grinding of teeth.

American Academy of Orofacial Pain (2008)

Bruxing is not a single disorder with a single treatment

TMDs- What are the choices? (190 Diagnoses, 7 Categories)

1. TMJ Damage

Adhesions and ankylosis of temporomandibular joint
Avascular Necrosis Mandibular Condyle
Cartilage Fibrillation, Mandibular Condyle, Fossa
Closed Lock, Jaw Cartilage, Acute
Closed Lock, Jaw Cartilage, Chronic
Closed Lock, Jaw Cartilage, Intermittent, Mechanically dysfunctional
Crush Injury Mandibular Condyle
Crystal arthropathy, unspecified, TMJ
Dislocation jaw cartilage due to injury, Sequela
Dislocation jaw cartilage with reduction, favorable adaptation, TMJ
Dislocation jaw cartilage without reduction, favorable adaptation, TMJ
Effusion, TMJ
Impingement Retrodiscal Tissue
Inflammatory Tissue Bone Resorption, TMJ Condyle
Loose Body (Joint Mice), TMJ
Malignant neoplasm of bones of skull and face
Open Lock TMJ, Recurring
Osteoarthritis TMJ, active degeneration
Osteoarthrosis- Inactive
Osteochondritis Dissecans TMJ
Osteolysis Mandibular Condyle, Active
Perforation Meniscus, TMJ
Perforation Pseudodisc, TMJ
Psoriatic Arthritis TMJ
Rheumatoid Arthritis Sero Negative TMJ

2. Muscles of the TMJ

Dystonia
Habitual posture forward mandible
Hemifacial Muscle spasm
Inhibitory Reflex Dysfunction, Periodontal Ligament Masseter Muscle
Muscle Atrophy, TMJ
Muscle Bracing Neck Stabilization
Muscle Bracing Pain Avoidance
Muscle Bracing TMJ stabilization
Muscle Bracing Airway **Patency** (with Tongue)
Muscle Contracture Fibrosis Lateral Pterygoid
Muscle Contracture Fibrosis Masseter, Medial Pterygoid, Temporalis
Muscle Fatigue Overuse
Muscle Hypertrophy TMJ Muscles

3. Cranial Alignment/Occlusion

Cranial Distortion / Misalignment
Hemifacial Hypoplasia
Hyper Occlusal Awareness
Iatrogenic Orthotic Damage
Malocclusion Anterior Open Bite
Malocclusion Centric occlusion MaxIC discrepancy
Malocclusion Deep Bite
Malocclusion due to mouth breathing
Malocclusion due to TMJ bone loss
Malocclusion due to tongue, lip or finger habits
Malocclusion Insufficient anterior occlusal guidance
Malocclusion lack of posterior occlusal support
Malocclusion Posterior Openbite Bilateral
Malocclusion Posterior Openbite Unilateral
Malocclusion unspecified
Malposition /Misalignment: Maxilla, Temporal Bone, Mandible
Mandibular asymmetry
Mandibular hyperplasia
Mandibular hypoplasia
Mandibular Retrognathia
Maxillary asymmetry
Maxillary hyperplasia
Maxillary hypoplasia
Maxillary Retrognathia
Occlusal Adaptation, Favorable
Occlusal Dependency for Joint Stabilization/ Proprioception
Tooth Intrusion
Tooth Supereruption

4. Cervical Damage

Cervical Vertebrae Alignment Dysfunction
Cervicocranial Syndrome
Muscle Guarding due Neck Instability
Trigger Point Neck Muscle with Referred Pain
Trigger Point Neck Muscle, Localized Pain

5. Parafunction

Excessive Tooth Wear, Damage
Hypersensitive Occlusion
Parafunctional Clenching Teeth, Awake
Parafunctional Clenching Teeth, Sleep
Parafunctional Grinding Teeth, Awake
Parafunctional Grinding Teeth, Sleep
Parafunctional Clench/Grind Wiggle
Parafunctional Tongue Bracing avoiding uncomfortable tooth contact
Parafunctional Tongue Bracing Neck stabilization
Parafunctional Tongue Bracing to maintain Airway
Parafunctional Tongue Bracing unknown cause

6. Whole Body / Systemic

Lyme Disease Arthritis
Magnesium Deficiency
Obstructive Sleep Apnea
Osteoporosis without current pathological fracture
Pathological Habitual Movement Pattern
Postural Disharmony Standing
Postural Disharmony Walking
Postural Forward Head Position
Upper Airway Resistance, UARS

7. Other

Nerve Entrapment Masseteric Nerve due to Masseteric hypertonicity
Neuroma Trigeminal Nerve
Obsessive-Compulsive Personality Disorder
Other
Otitis Ear Infection
Pain disorder exclusively related to psychological factors. Somatoform pain disorder
Pain disorder with related psychological factors
Peripheral Sensitization

TMDs- What are the choices? (190 Diagnoses, 7 Categories)

5. Parafunction

Excessive Tooth Wear, Damage
Hypersensitive Occlusion
Parafunctional Clenching Teeth, Awake
Parafunctional Clenching Teeth, Sleep
Parafunctional Grinding Teeth, Awake
Parafunctional Grinding Teeth, Sleep
Parafunctional Clench/Grind Wiggle
Parafunctional Tongue Bracing avoiding uncomfortable tooth contact
Parafunctional Tongue Bracing Neck stabilization
Parafunctional Tongue Bracing to maintain Airway
Parafunctional Tongue Bracing unknown cause

BRUXING: PARAFUNCTIONAL TOOTH CONTACT

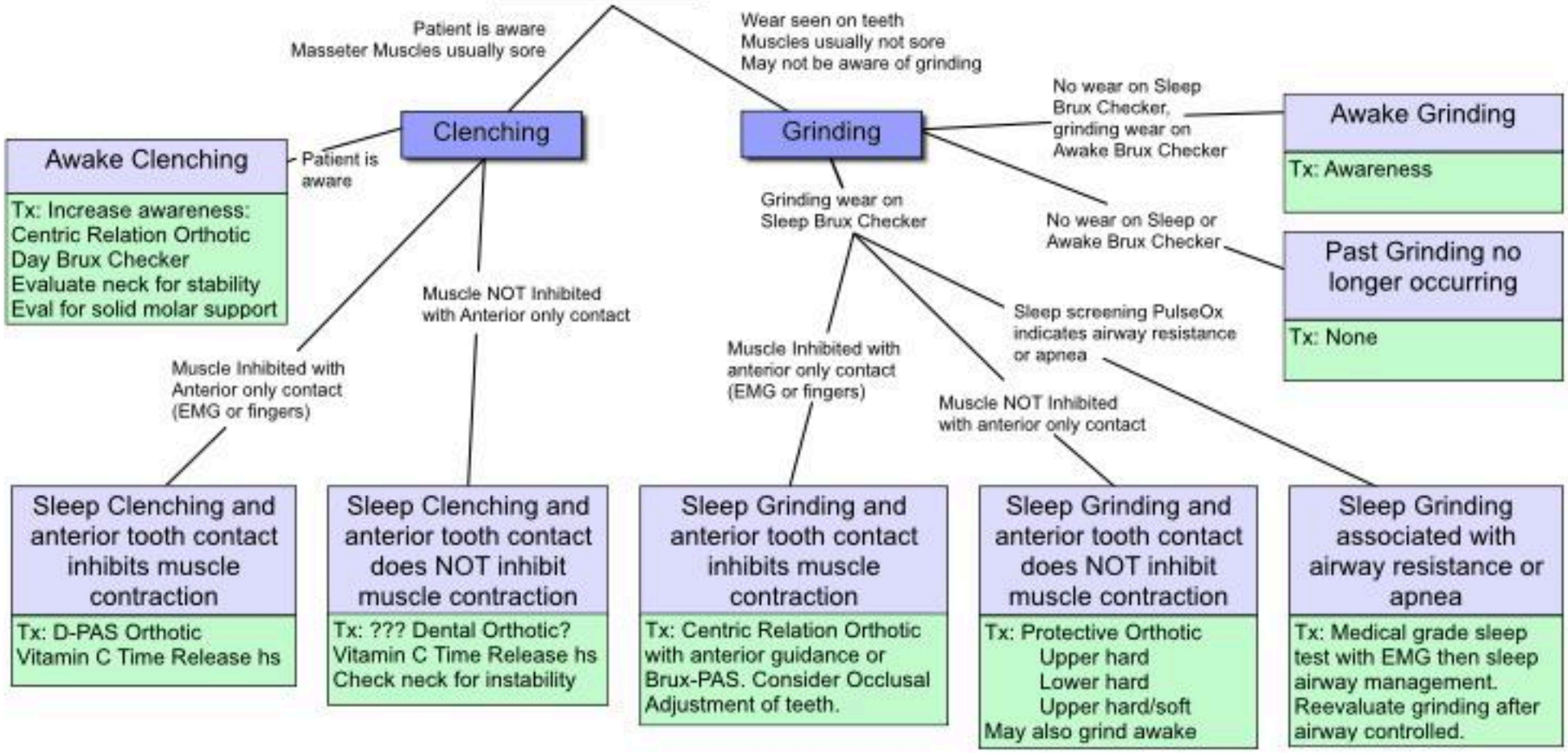

5 questions that will help identify the specific bruxing disorder:

1. Does the patient grind or clench their teeth?
2. When does/did this occur: Awake or asleep, past or present?
3. Are the TMJ muscles inhibited from full contraction with anterior only contact?
4. If sleep grinding, is there an airway issue?
5. Does the dental orthotic make the airway better or worse?

1. Does the Patient Grind or Clench?

Clenching you squeeze your teeth together

Grinding you rub your teeth together

16 yo

Clenchers destroy the joint,
Grinders destroy the teeth

<u>Clenching</u>
Painful Muscles
Patient is usually aware of clenching
Fremitus
Strong Masseters
See slight wear around tooth contacts
Damage TMJ cartilage

<u>Grinding</u>
See tooth wear
Patient is usually not aware
Buttressing bone if teeth are tight
If tooth mobility, on excursions
Strong Masseters
Slight Soreness muscles
Usually no muscle pain

If patient is unaware of clenching-
Plant seed at hygiene visit
Do you clench?

Parker Mahan-
"Women Hurt, Men destroy"

2. Does this occur awake or asleep?

Brux Checker
Great Lakes Orthodontics

0.1mm Mylar

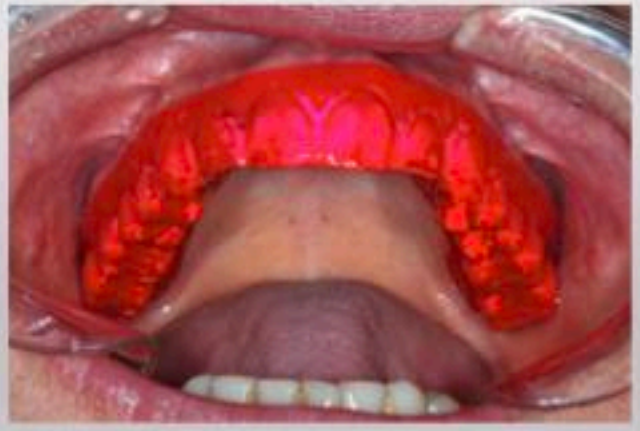

Made on Biostar Machine

Daytime Clenching- Clear Brux Checker

Increase awareness to break habit

Very thin: Similar to mylar used for composites

Great Lakes Orthodontics
Biostar Platzhalterfolie
Item Ref 3202.1

3. Are the TMJ muscles inhibited from full contraction with anterior only tooth contact?

Detect with EMG or muscle palpation- Clench full power on posterior teeth and then with D-PAS orthotic.

Diagnostic
Palatal Anterior Stop
Orthotic

Patient with muscles
<u>inhibited by anterior only contact</u>

	Clench MaxIC	Anterior Stop D-PAS
	µV	µV
TA-R	100.6	15.7
TA-L	108.9	25.3
MM-R	115.4	25.5
MM-L	70.5	6.8

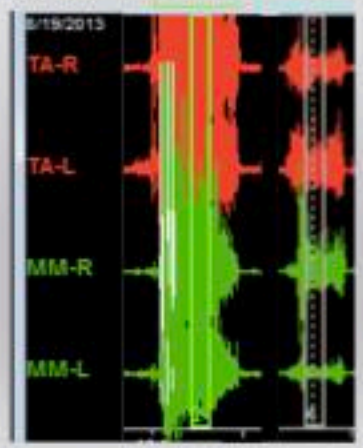

Major decrease in muscle power with D-PAS

Another Patient with muscles NOT
<u>inhibited by anterior only contact</u>

	Clench MaxIC	Anterior Stop D-PAS
	µV	µV
TA-R	82.2	77.9
TA-L	124.6	103.6
MM-R	185.0	169.0
MM-L	79.9	86.6

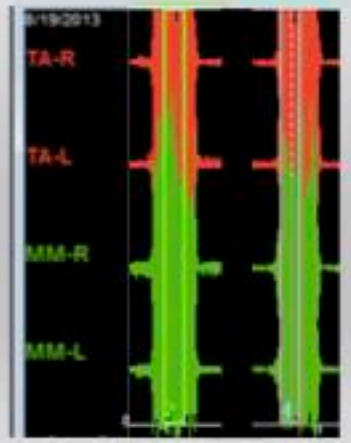

Muscle power same with D-PAS

TScan EMG Link

We can measure muscle activity chairside and link it to occlusal contacts
Muscles are inhibited from firing with anterior only contact
Gives endpoint to occlusal adjustment

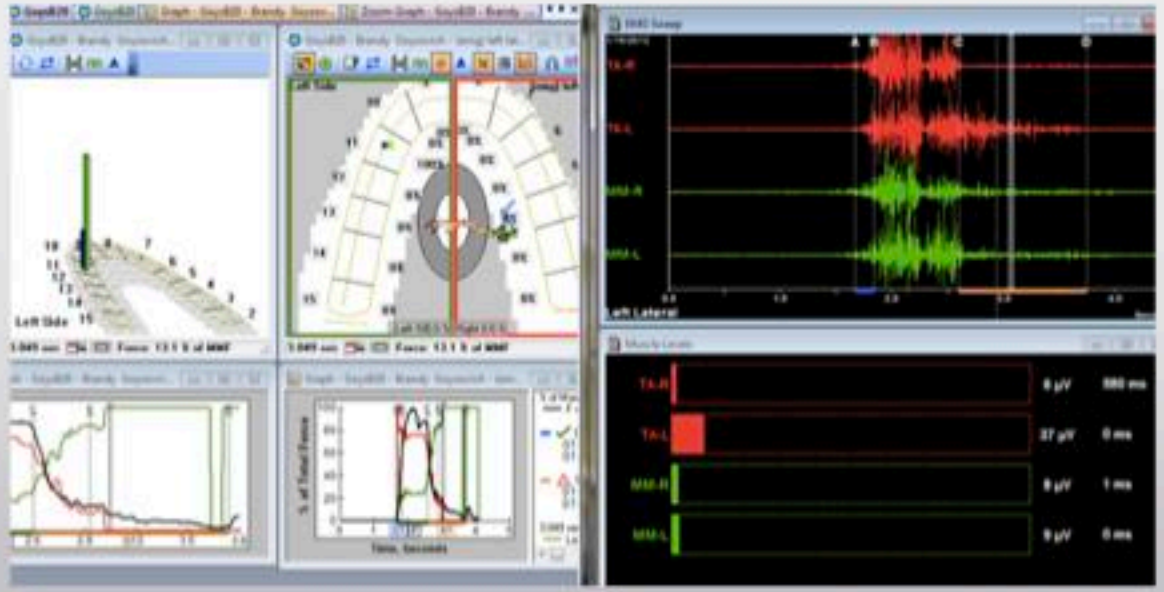

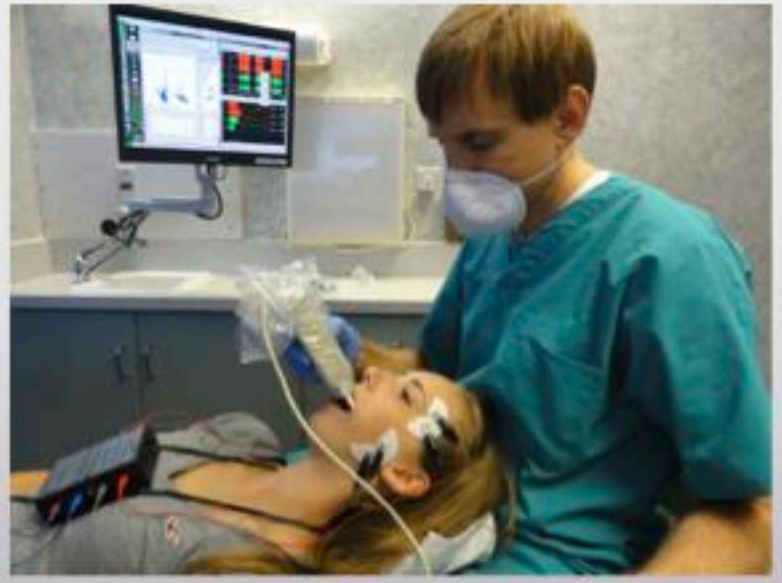

Williamson, E. H., Anterior Guidance: Its effect on electromyographic activity of the temporalis and masseter muscles. J Prosthet Dent 49-6:816-823, 1983.

EMG Tscan- Masseter and Temporalis

Maximum Intercuspation Clench
100-113 microvolts



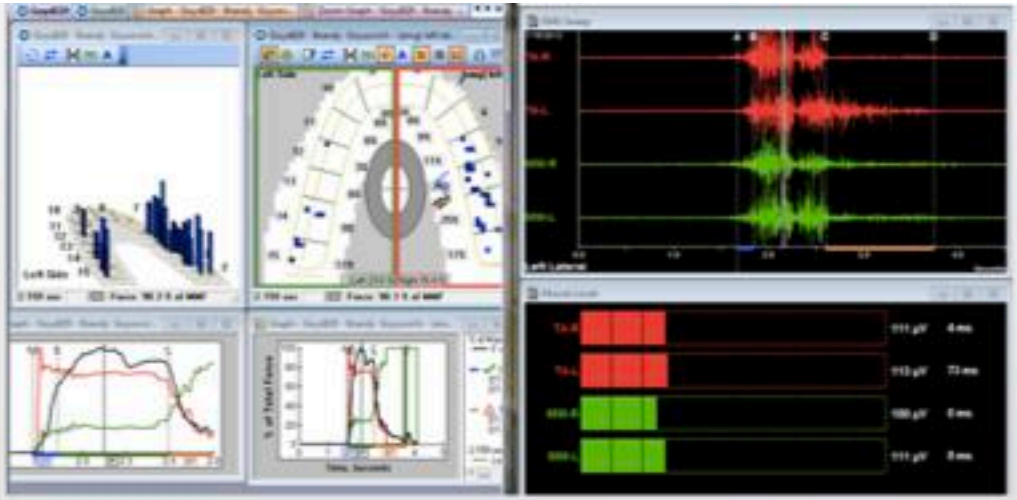

Left Lateral Excursive



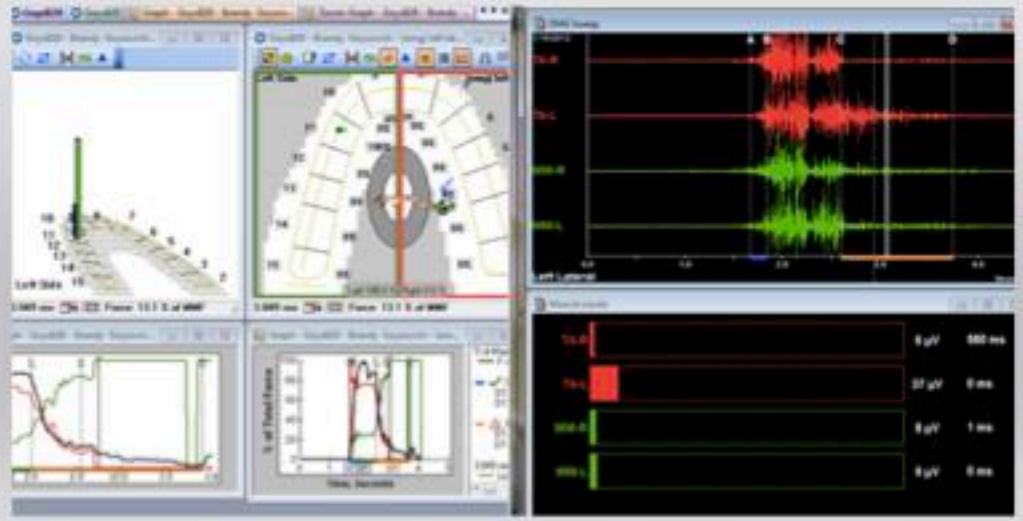

Biomechanics of Anterior Stop Orthotic

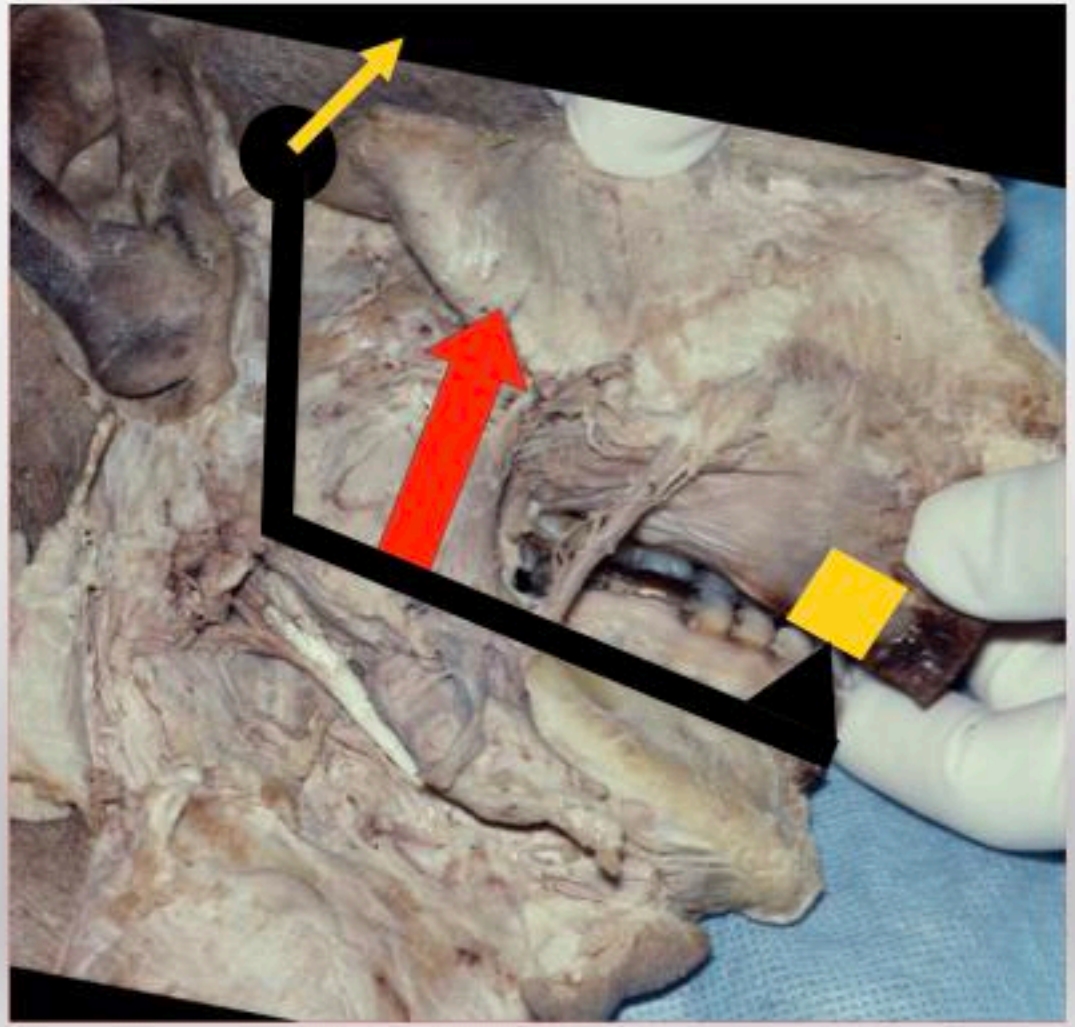

Anterior Deprogrammer
Anterior Stop Orthotic

Common Actions to all Anterior Deprogrammers:
- Only anterior teeth contact in MaxIC
- Load/seat condyles
- Eliminate immediate posterior interferences

Wear 10- 15 min in Office

Wear Nighttime

Can wear Nighttime and Daytime
24 hour wear no longer than 1 week

Upper Anterior Deprogrammer

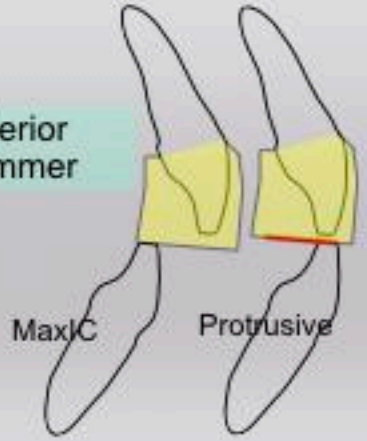

Lower Anterior Deprogrammer

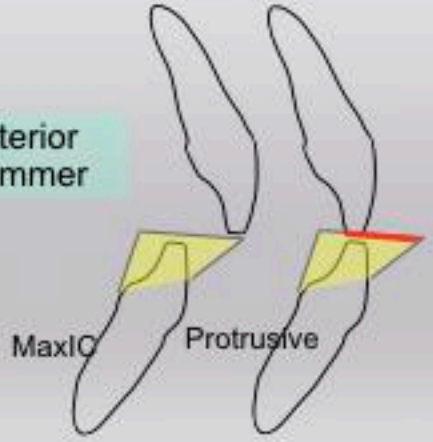

My Top Choice
"D-PAS"

Palatal Anterior Stop Orthotic

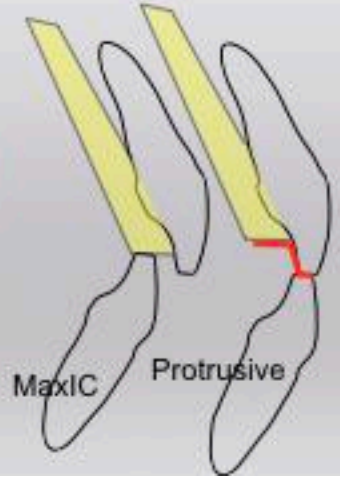

Key Features of D-PAS
Diagnostic Palatal Anterior Stop

To Optimize Results:

- Relined so forces go into whole maxilla
- Pitch is perpendicular to arc of closure
- Minimal change in vertical
- Nothing wraps around the buccal

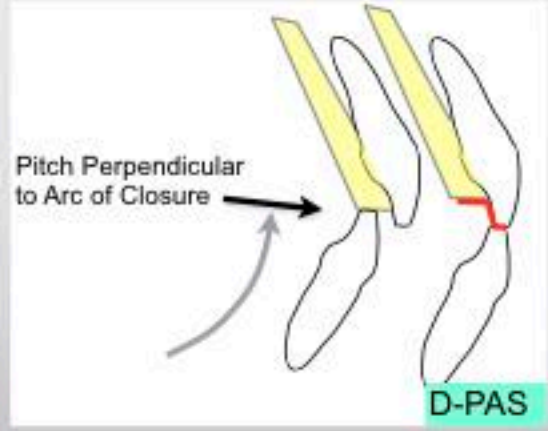

When reline can do just anterior if good retention.
Must reline at lease cuspid to cuspid.

Basically it is a relined upper Hawley Orthotic with no buccal restrictions, with an anterior stop added.
Similar Orthotics- Hawley with anterior stop, Kois, Cranham, Hegyi DATA

Muscle inhibition with anterior teeth only contact: D-PAS

50-90% decrease EMG

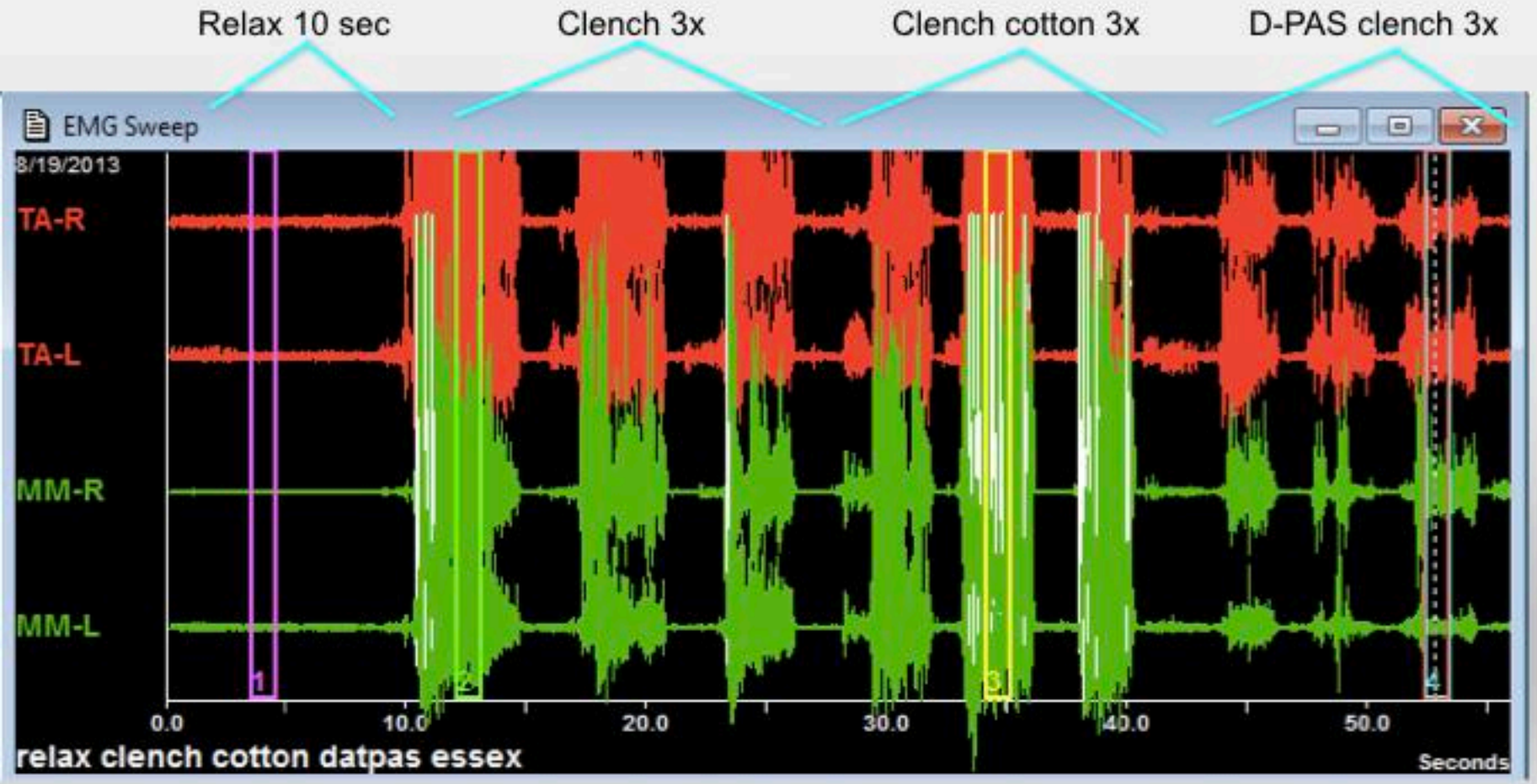

No muscle inhibition with anterior teeth only contact- D-PAS

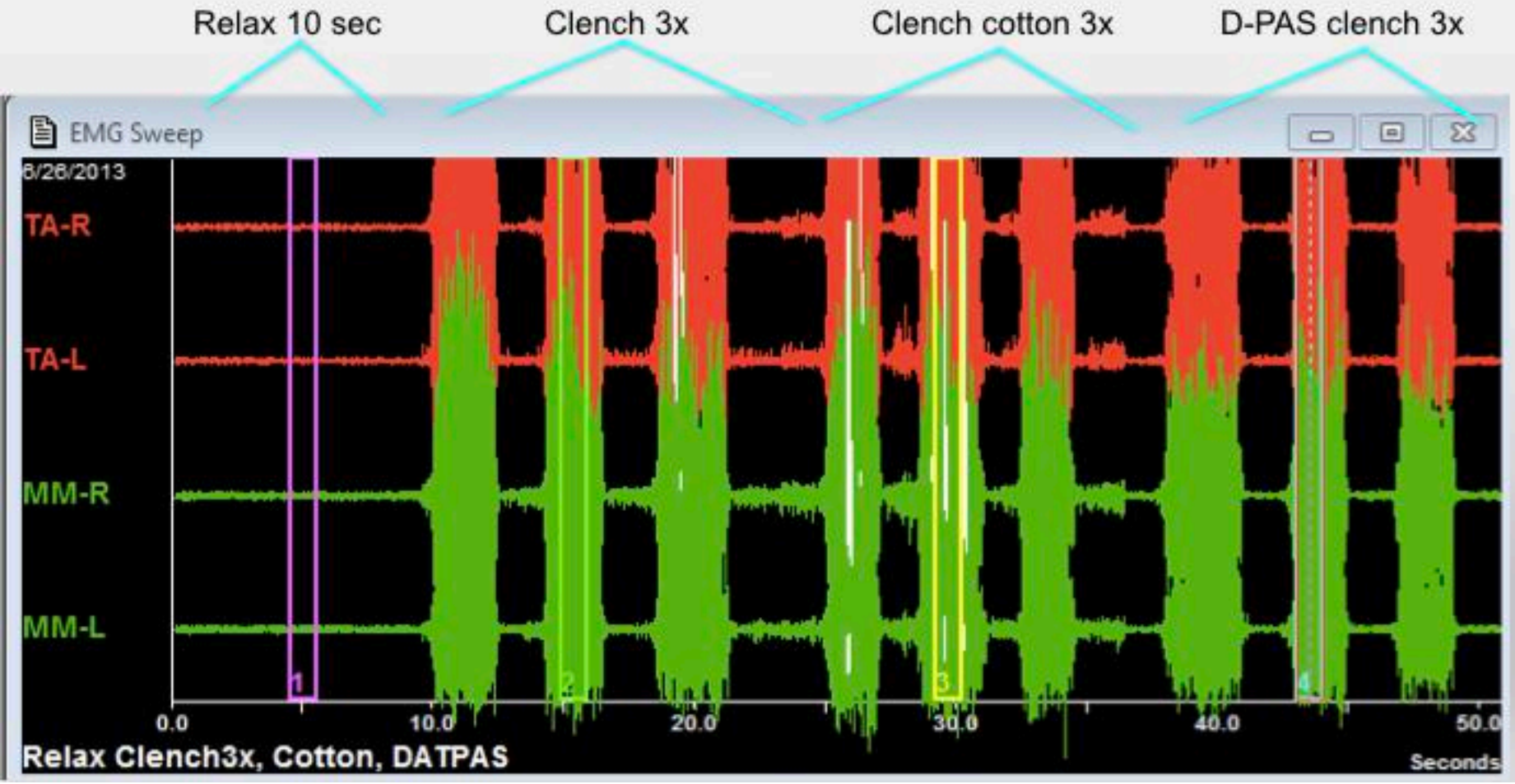

4. If sleep grinding, is there an airway issue?
(Upper Airway Resistance or Obstructive Sleep Apnea)

High Resolution Pulse Oximetry

Data every 1 second average over 3 seconds

Patient Safety Inc.

SLEEPSAT

SATSCREEN

Order Pulse Ox and Software: Go to my website or www.patientsafetyinc.com

Sleep SAT is the replacement for PULSOX 300i, Konica Minolta no longer made

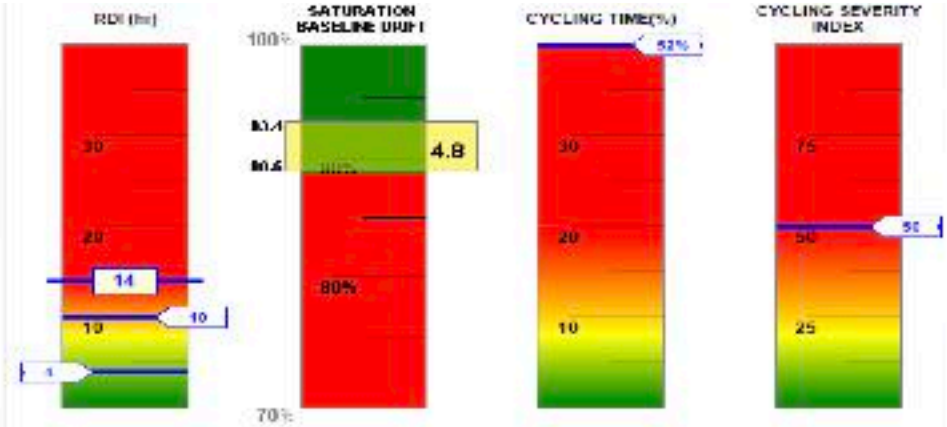

–Desaturations associated with Early Motion are Excluded in these calculations.
–Physician should review the waveform and consider reviewing the report without the above exclusions.

PATTERN BASED REPORT

OXYGEN SATURATION BASELINE ANALYSIS

Oxygen Saturation Baseline Drift(OSBD) (normal <= 3)	5
Initial Saturation Baseline	93
Lowest Saturation Baseline	89
Highest Saturation Baseline	93

Baseline is determined by the Mean SpO2 during 3 Minute window without Artifact and without Events.



SPO2 CYCLING

% Time in Cycling (Duration)	52%	(02:50:14)
Cycling Frequency	45	
96% - Lowest Sat	12	
Cycling Severity Index	50	

The total time oxygen saturation was <= 88% was 00:13:39

TRADITIONAL REPORT

ODI4:	11
Total ODI4 Events:	58
Time in ODI4 Events:	00:29:26
Avg ODI4 Event Duration:	00:00:28
<=88% ODI4 Events:	23
<=88% Longest Duration:	00:01:21
Minimum SpO2:	84
Avg Low 10% SpO2:	86
Avg Low SpO2:	89
Avg Low SpO2 <=88%:	87

Definition of ODI4 Event: a fall in oxygen saturation of at least 4% and persisting greater than 3 seconds.

%SpO2	DURATION	%TOTAL
94-100	00:16:37	5%
88-94	04:57:26	91%
80-88	00:13:39	4%
70-80	00:00:00	0%
<= 70	00:00:00	0%
Total	05:27:42	100%
Motion Artifact	00:00:07	0.04%
Error Signal	00:00:05	0.03%

5. Does the dental orthotic make the airway better or worse?

RDI= Respiratory Distress Index

Sometimes D-PAS makes airway better, sometimes worse

No dental orthotic
RDI = 3

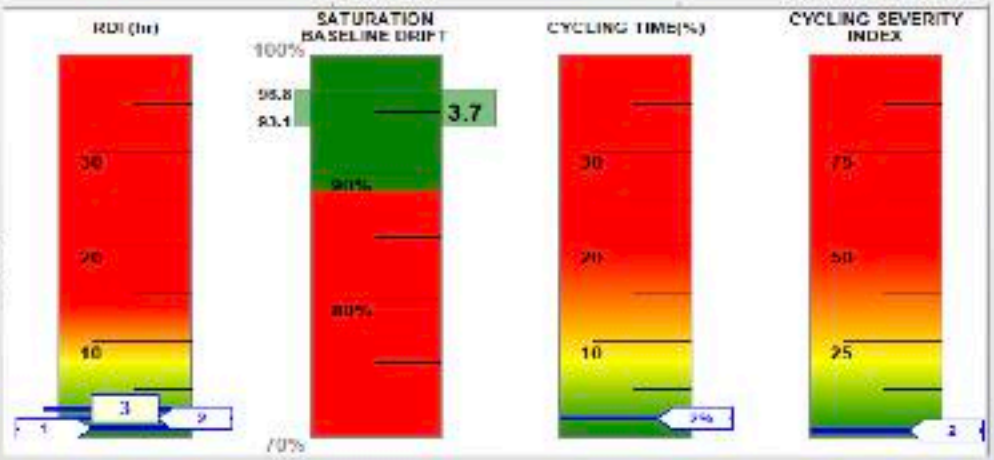

Dental Orthotic:
Anterior Stop: D-PAS
RDI =10

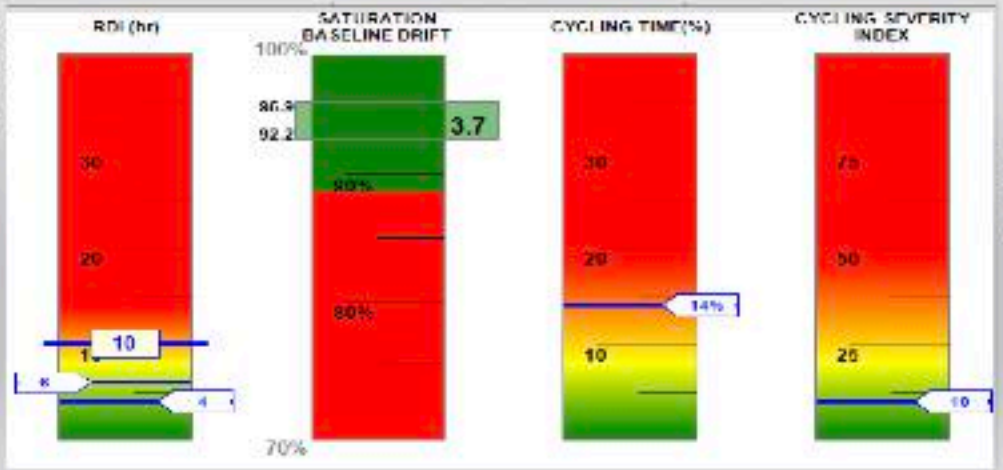

High Resolution Pulse Oximetry

Patient Safety, Inc.

5 questions that will help identify the specific bruxing disorder:

1. Does the patient grind or clench their teeth?
2. When does/did this occur: Awake or asleep, past or present?
3. Are the TMJ muscles inhibited from full contraction with anterior only contact?
4. If sleep grinding, is there an airway issue?
5. Does the dental orthotic make the airway better or worse?

BRUXING: PARAFUNCTIONAL TOOTH CONTACT

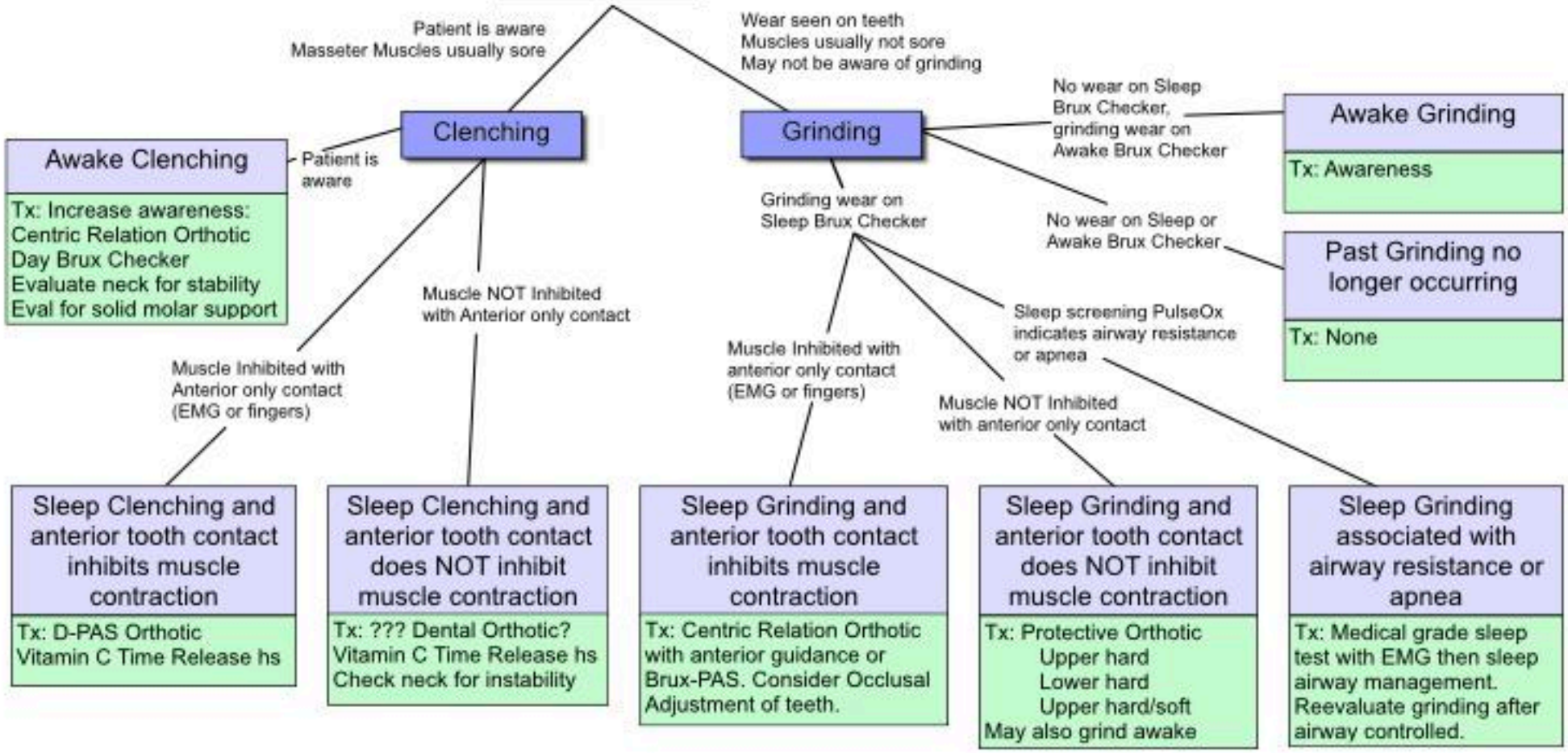

BRUXING: PARAFUNCTIONAL TOOTH CONTACT

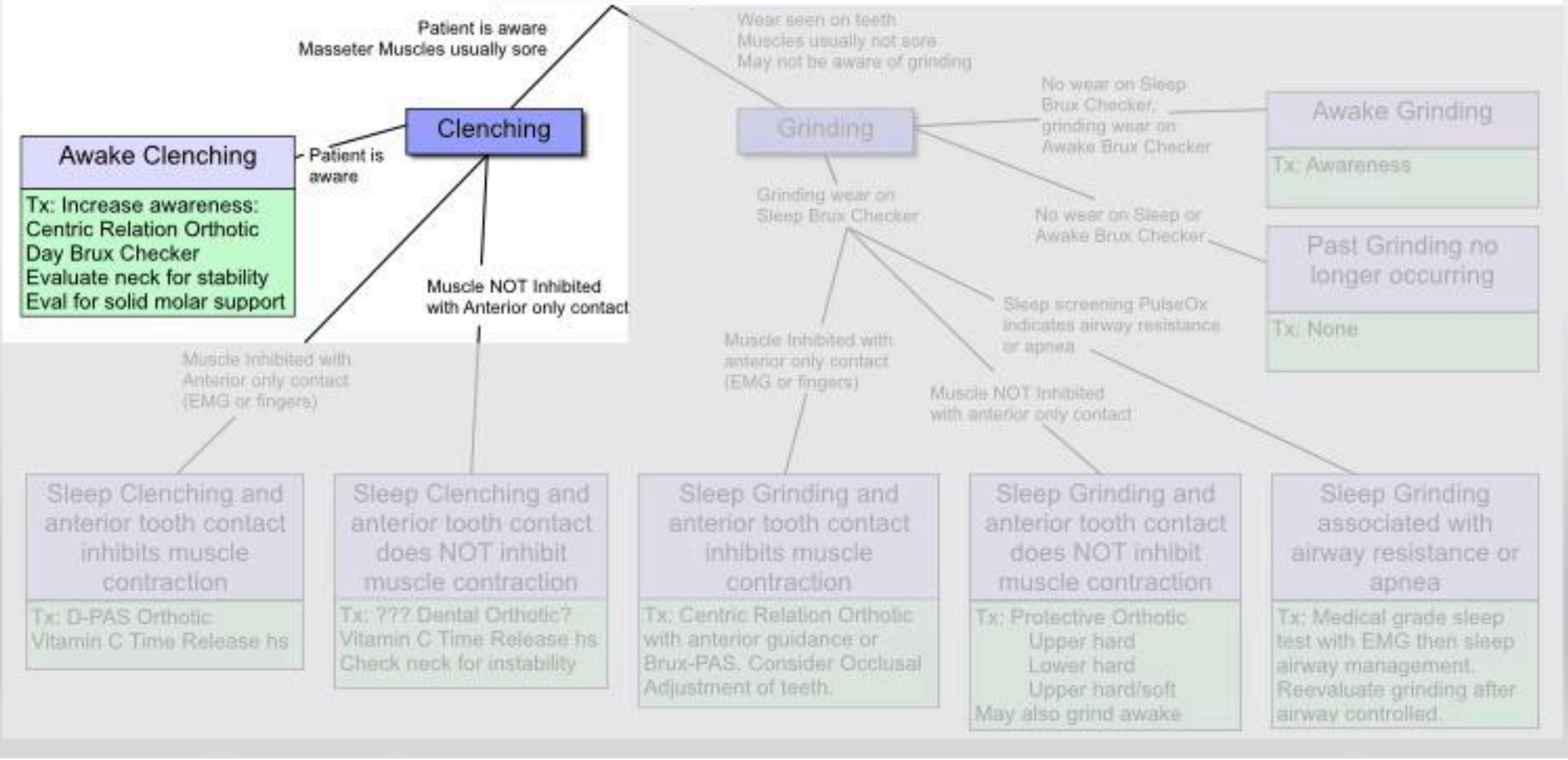

Daytime Clenching- Clear Brux Checker

Increase awareness to break habit

Very thin: Similar to mylar used for composites

Great Lakes Orthodontics
Biostar Platzhalterfolie
Item Ref 3202.1

BRUXING: PARAFUNCTIONAL TOOTH CONTACT

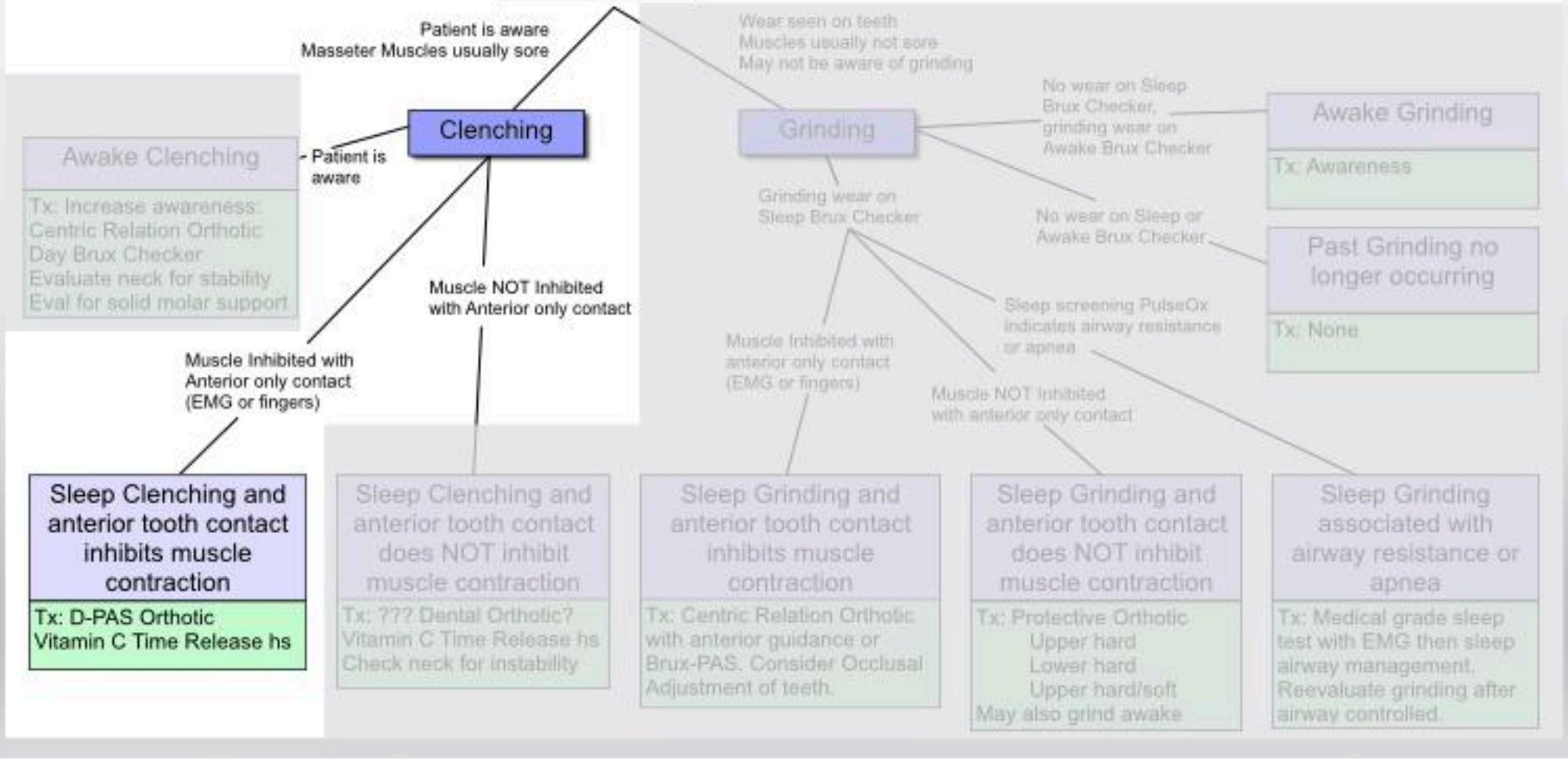

Clenching can cause disc subluxation

Chronic Micro Trauma from clenching

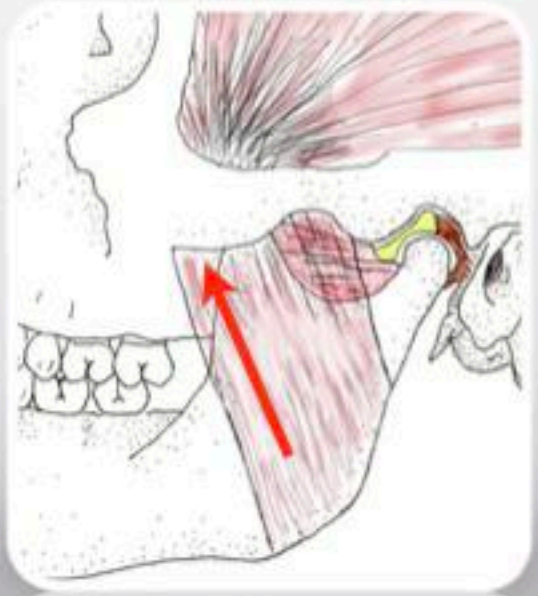

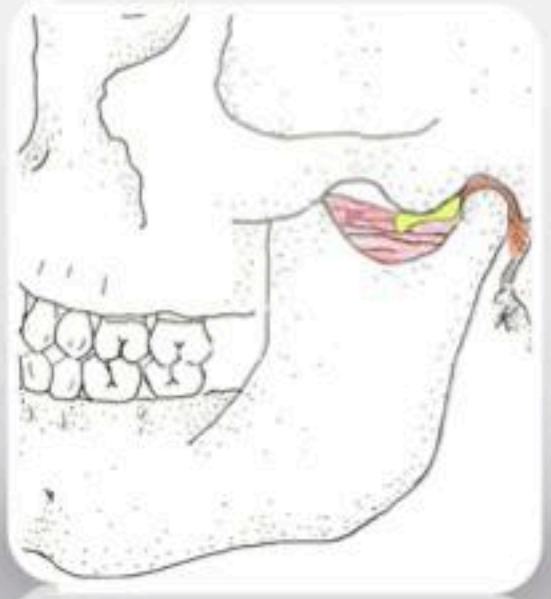

Clenching breaks down Hyaluronic Acid and Phospholipids

Creates “Sticky disc”

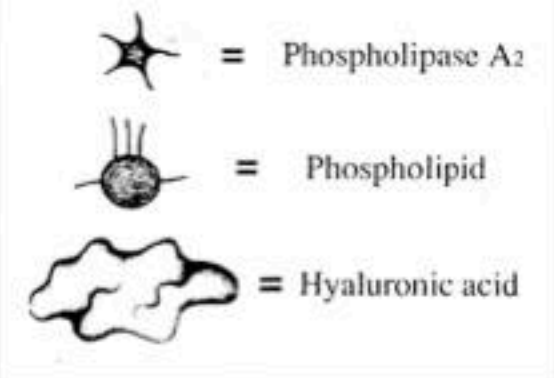

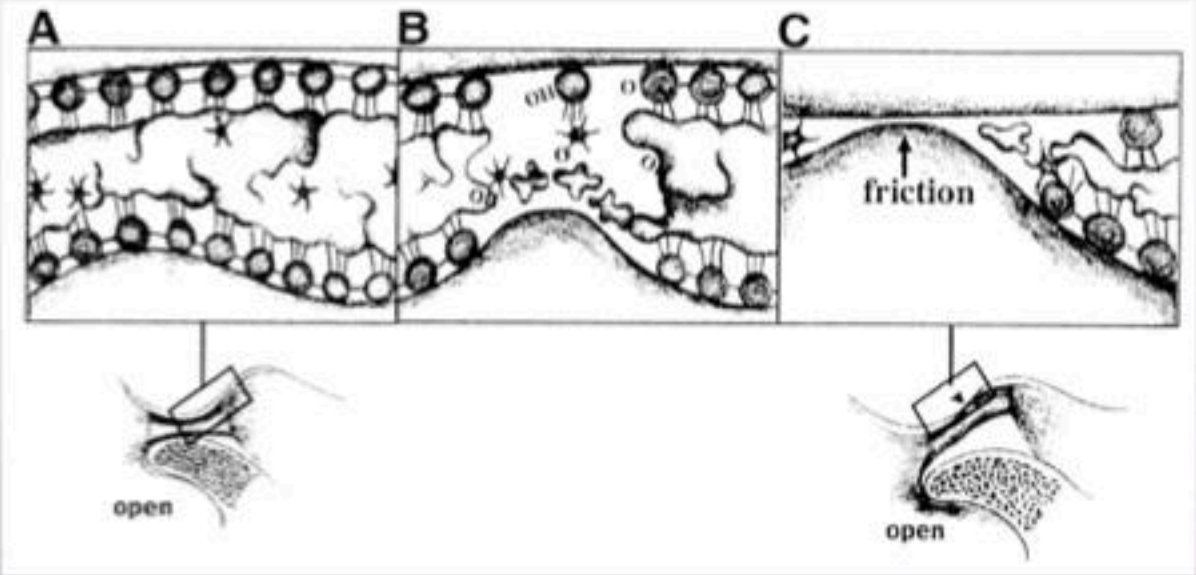

Nitzan, DW, The Process of lubrication impairment and its involvement in temporomandibular joint disc displacement: a theoretical concept, J Oral Maxillofac Surg. 59:36-45, 2001

Sticky Disc sticks as mandible moves

Ligaments loosen

Disc Distorts

Eventually ADD

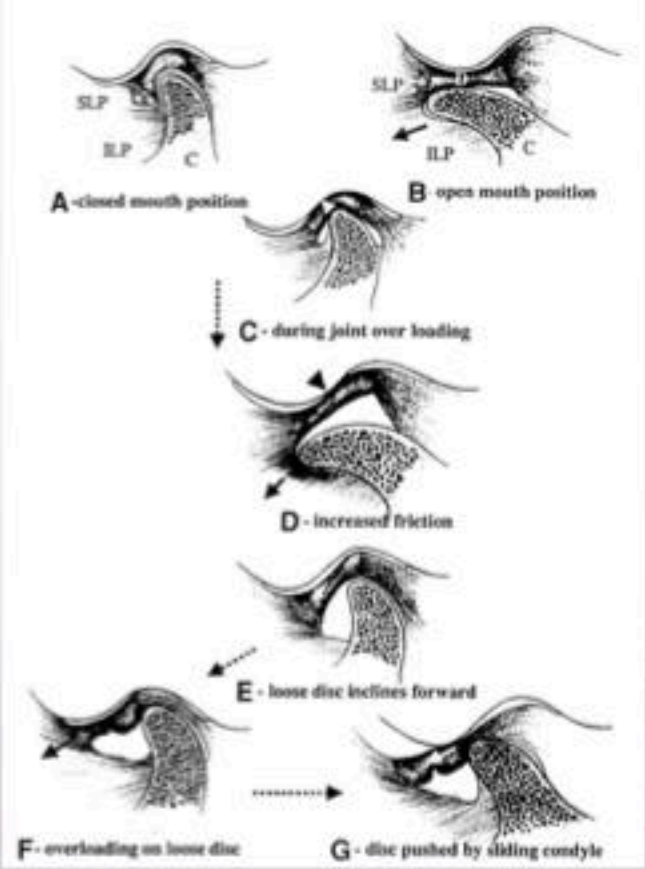

Dr. Dorit Nitzan

Nitzan, DW, The Process of lubrication impairment and its involvement in temporomandibular joint disc displacement: a theoretical concept, J Oral Maxillofac Surg. 59:36-45, 2001

Clenching can lead to disc dislocation

Normal

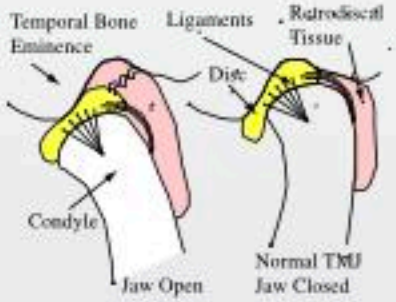

"Sticky Disc" - Clenching causes disc to stick in upper joint compartment. As condyle moves forward, disc distorts and eventually releases, making a clicking sound. On closing disc is slow to return, stretching discal ligaments.

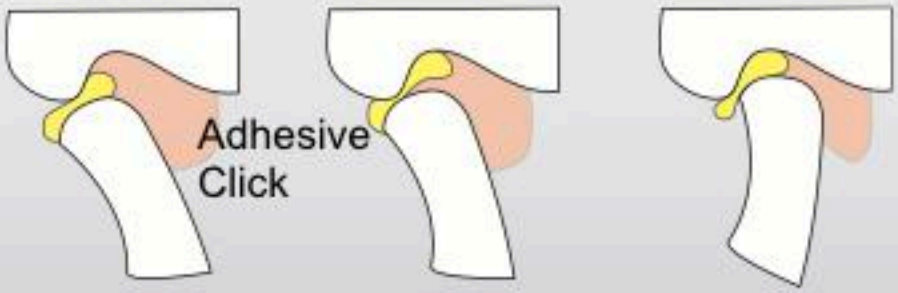

Over time can lead to Anterior Disc Dislocation with Reduction

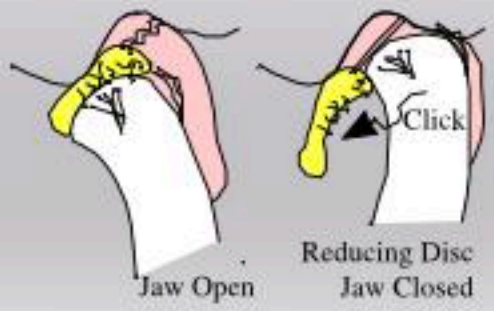

D-PAS to Manage Sleep Clenching in patients with anterior inhibition

To Optimize Results:

- Relined so forces go into whole maxilla
- Pitch is perpendicular to arc of closure
- Minimal change in vertical
- Nothing wraps around the buccal

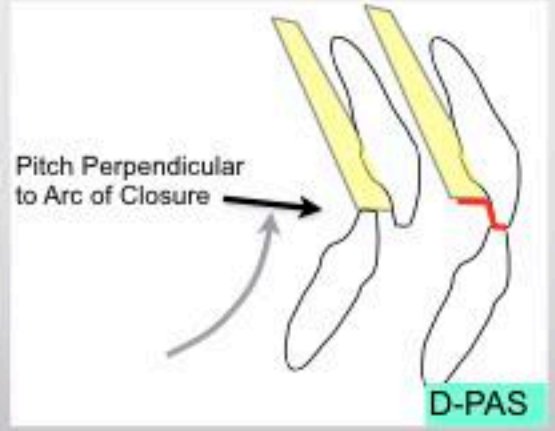

When reline can do just anterior if good retention.
Must reline at lease cuspid to cuspid.

Basically it is a relined upper Hawley Orthotic with no buccal restrictions, with an anterior stop added.
Similar Orthotics- Hawley with anterior stop, Kois, Cranham, Hegyi DATA

Make your own or have your lab make D-PAS

To get DPAS how to make:
go to www.jrdroter.com

Seminar Download

DPAS Construction

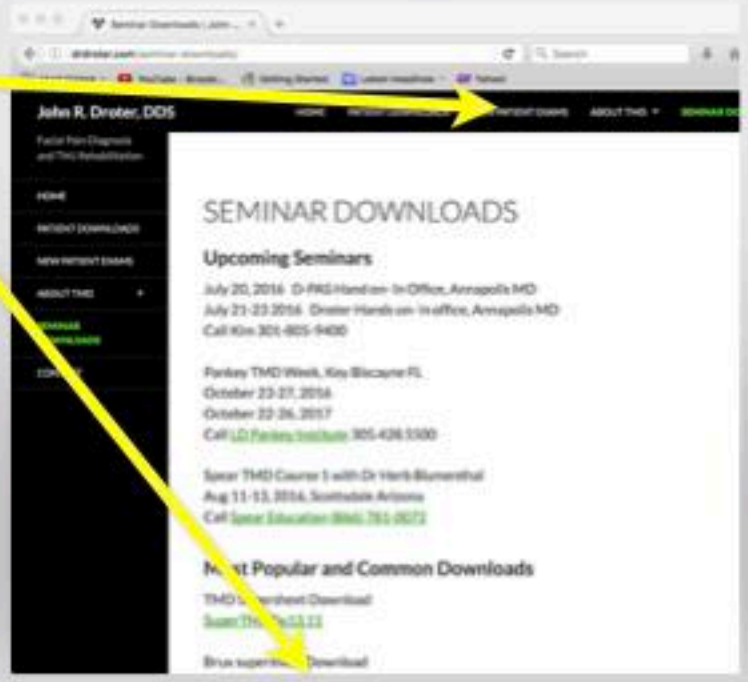

Or have Thayer Dental Lab make D-PAS as recommended by Dr Droter
Ask for Denise
Cost estimate $110

131 Old Schoolhouse Lane
Mechanicsburg, Pennsylvania
1.800.383.1240

Hypoxia Re-perfusion Injury

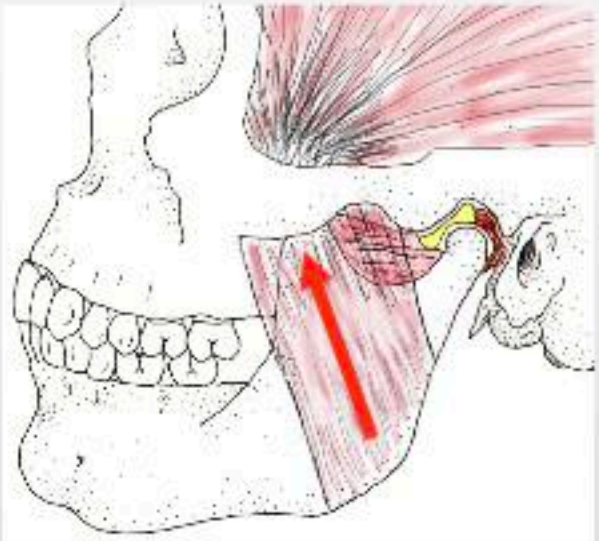

Clenching: Static Loading No Oxygen/Hypoxia
On waking with joint motion get re-perfusion of Oxygen
Oxygen Free Radicals cause Oxidative Damage

If antioxidants (Vitamin A, C, E) around:
- Protects tissue from damage
- Vitamin C 1000 mg at dinner with other vitamins
  - NOW Vitamin C Sustained Release 1000 mg
  - Shaklee Vitamin C Sustained Release 500 mg x2

Tx for Clenchers: Vitamin C at dinner, possible add Mg++ at 8pm , D-PAS

Blake DR, Merry P, Unsworth J, Kidd BL, Outhwaite JM, Ballard R, Morris CJ, Gray L, Lunec J. Hypoxic-reperfusion injury in the inflamed human joint. Lancet. 1989 Feb 11;1(8633):289-93.

McAlindon TE, Jacques P, Zhang Y, Hannan MT, Do antioxidant micronutrients protect against the development and progression of knee osteoarthritis?, Arthritis Rheum. 1996 Apr;39(4):648-56.

BRUXING: PARAFUNCTIONAL TOOTH CONTACT

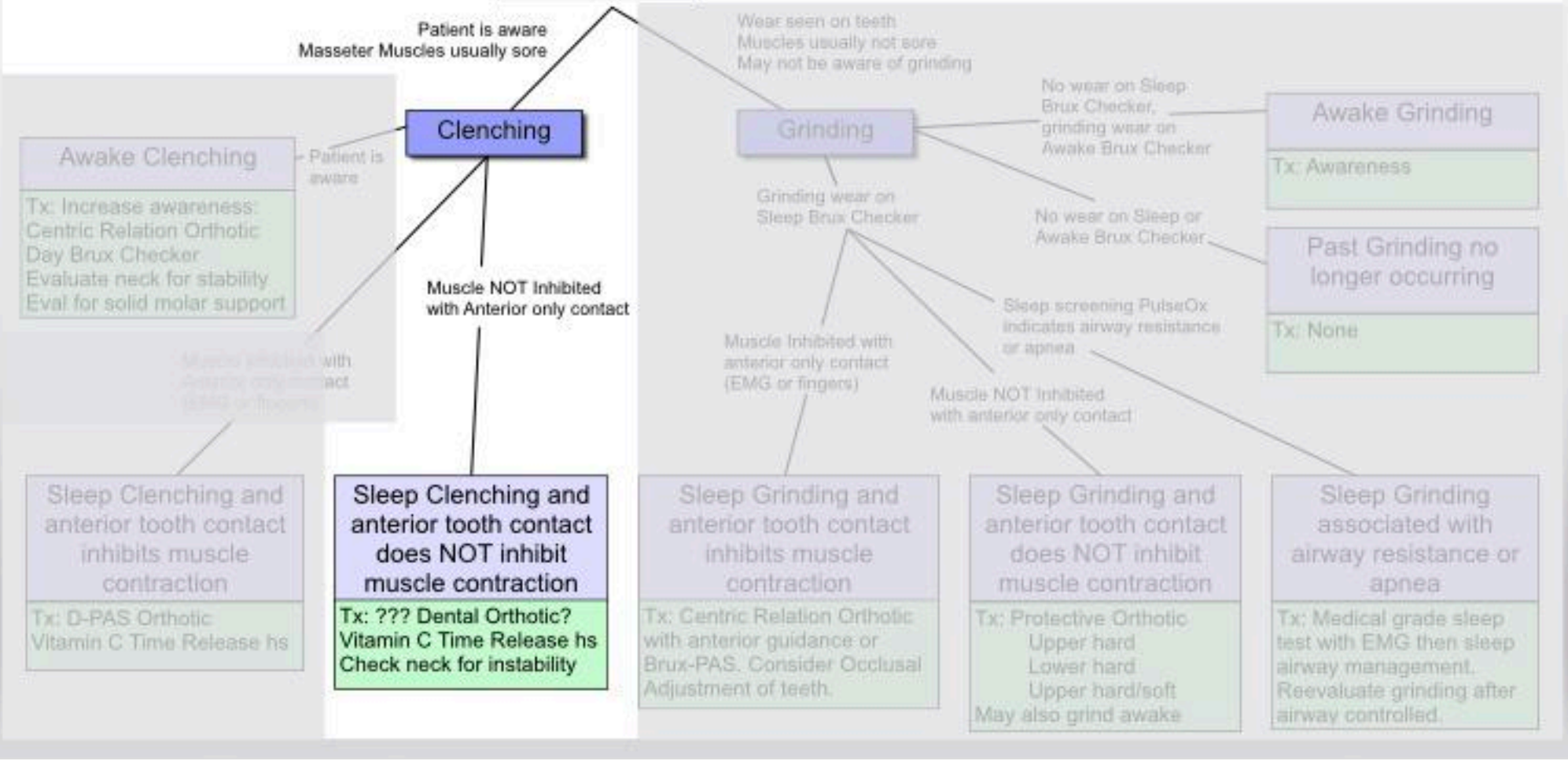

Medications that affect Parafunction

Botox will decrease strength of bruxing contraction Decrease Masseter Hypertrophy

Botox injection
Masseter Muscles

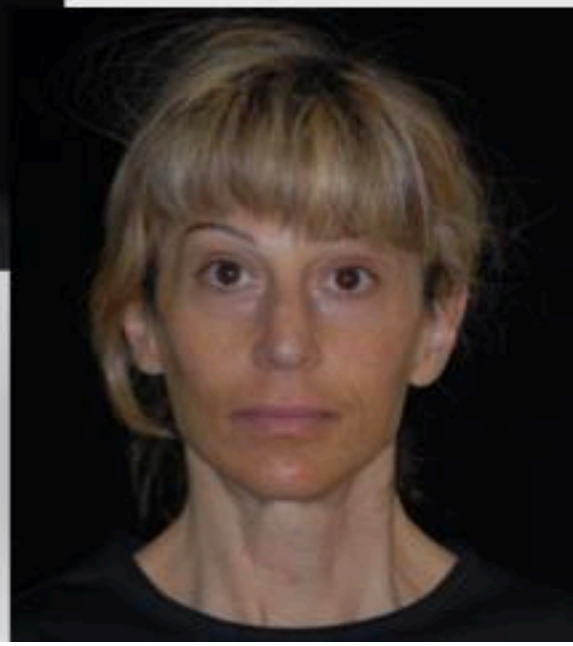

Need to address cervical and occlusal issues along with Botox therapy

6 months

J Plast Reconstr Aesthet Surg. 2010 Dec;63(12):2026-31. Evaluation and selecting indications for the treatment of improving facial morphology by masseteric injection of botulinum toxin type A. Gaofeng L1, Jun T, Bo P, Bosheng Z, Qian Z, Dongping L.

Medications that affect Bruxing

Botox injection
Masseter
Muscles

Medications that affect Bruxing

Selective Serotonin Reuptake Inhibitors
- SSRI that increase bruxing: Prozac, Zoloft
- SSRI neutral on bruxing: Cymbalta, Wellbutrin

Klonopin/Clonazepam (benzodiazepine)
- May decrease sleep bruxing
- Addiction potential, causes low BP
- Not a long term solution

Maria Clotilde Carra DMD, Nelly Huynh PhD, and Gilles Lavigne DMD PhD FRDC
Sleep Bruxism: A Comprehensive Overview for the Dental Clinician Interested in Sleep Medicine.
Dental Clinics of NA, 56(2), 387–413. doi:10.1016/j.cden.2012.01.003

BRUXING: PARAFUNCTIONAL TOOTH CONTACT

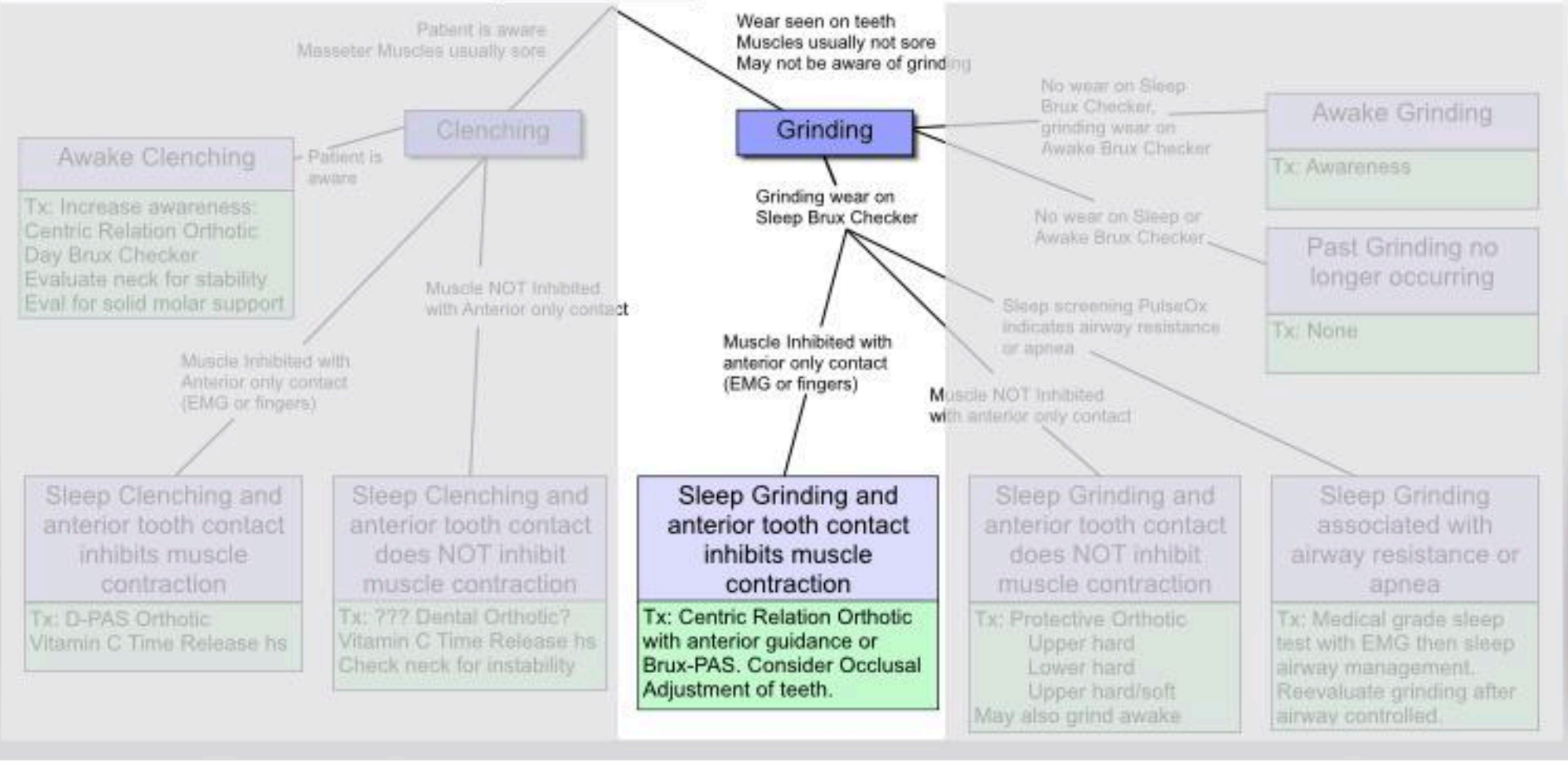

Centric Relation Orthotic

Condyles fully seated

Dots in the Back

Lines in the Front

Must not rock or be squishy

Patient gets to experience a full, solid, harmonious bite.

Doctor gains experience in setting up a harmonious bite in this particular patient

Can wear 24/7 for longer than 3 weeks

See patient at week 1, 2, 4. Then every 2-4 weeks. No longer than 6 weeks between appt.

CR Orthotic

Condyles fully seated

Dots in the Back

Lines in the Front

Anatomic Orthotic by Dr. Buzz Raymond

Pankey Study Clubs
Tanner Study Clubs

Clenching verses Grinding and the TMJ

Clenching- Squeeze your teeth
Destroys Cartilage

Grinding- Rub your teeth
Destroys teeth
Adaptation in Joint

D-PAS

Manage Clenching with D-PAS

Manage grinding with Brux-PAS

Must have muscle inhibition!!!

Brux-PAS +
Essex

Brux-PAS

Note: Soft orthotics increase power of clench or grind

BRUXING: PARAFUNCTIONAL TOOTH CONTACT

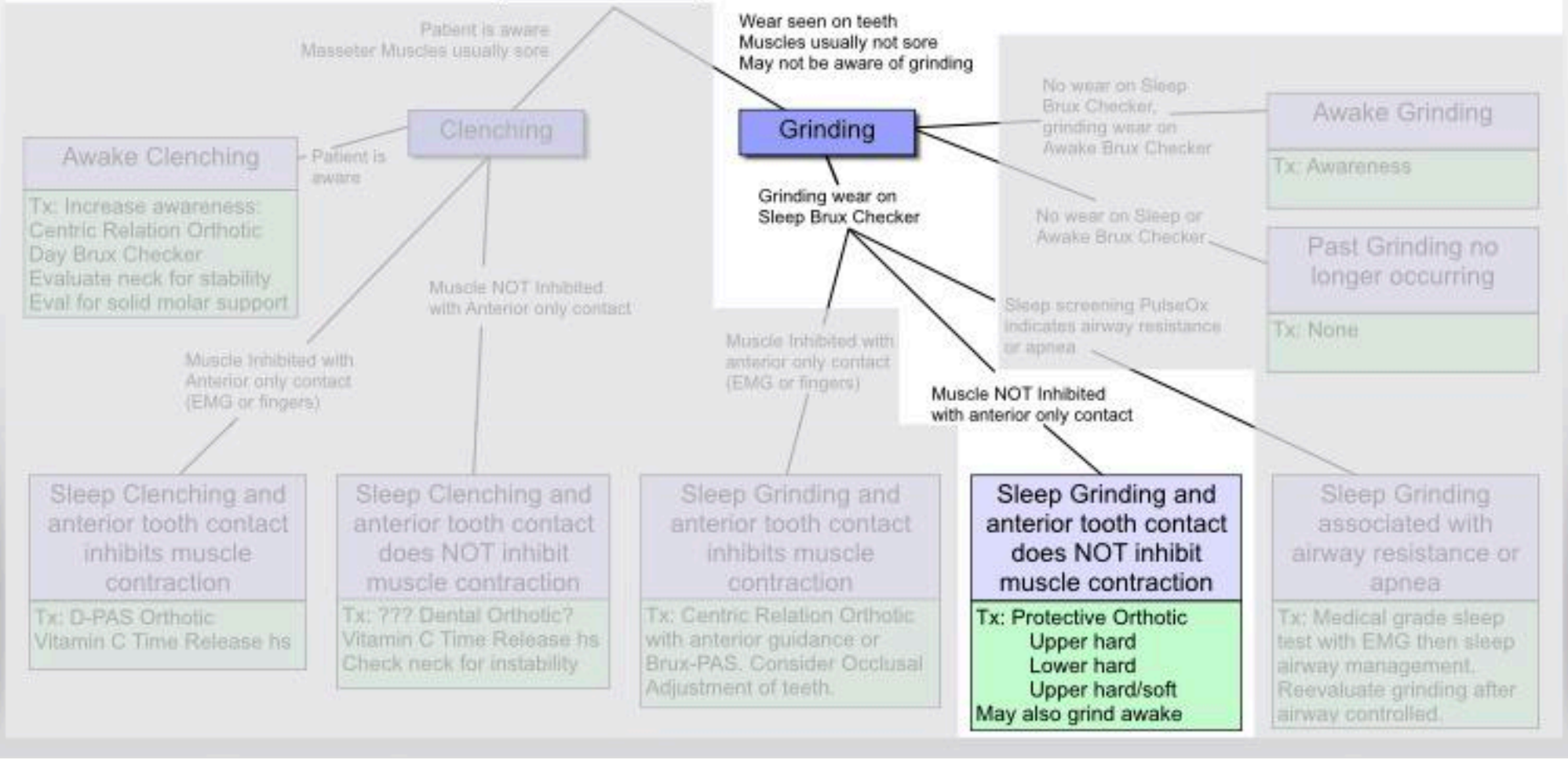

Side to Side Severe Grinding

Sleep Disorder
?Airway Related?

How to Restore??

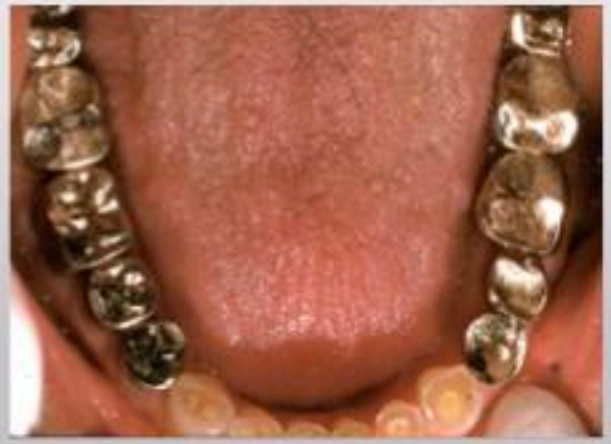

Lavigne GJ, Khoury S, Abe S, Yamaguchi T, Raphael K., Bruxism physiology and pathology: an overview for clinicians. J Oral Rehabil. 2008 Jul;35(7):476-94

Delivery

5 years post tx

Key Point:
Build in group function
Side to Side Grinders.

Kids 25-35% Grind

Serra-Negra JM, Paiva SM, Seabra AP, Dorella C, Lemos BF, Pordeus IA., Prevalence of sleep bruxism in a group of Brazilian schoolchildren. Eur Arch Paediatr Dent. 2010 Aug;11(4):192-5.

BRUXING: PARAFUNCTIONAL TOOTH CONTACT

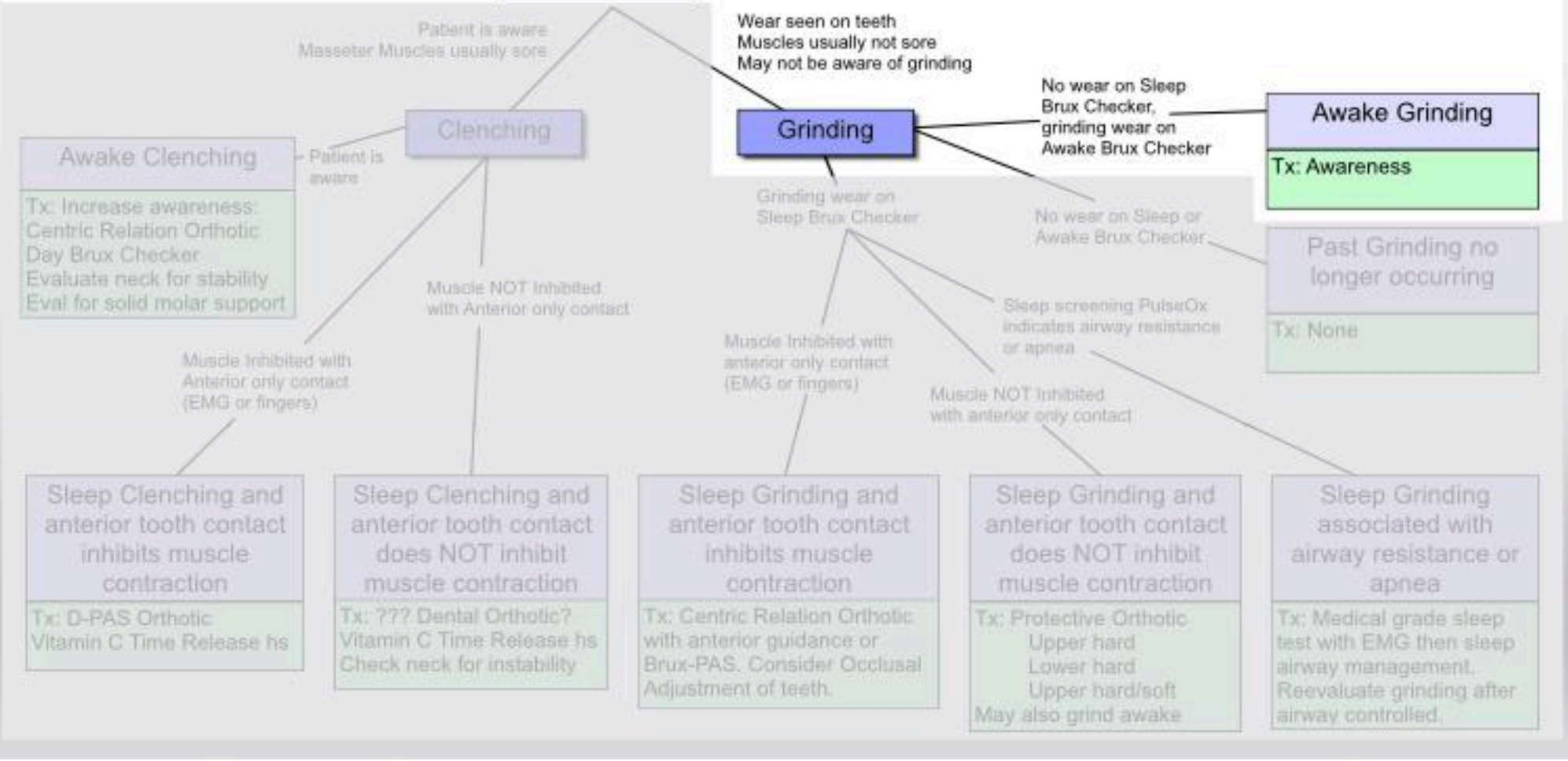

Fracture of porcelain and fracture of lower teeth 6 months
after delivery of full mouth crowns
(Not my crowns)

Occlusal Adjustment on curve Spee/Wilson
Set up group function
Long term Radica Temps 23-26
Pt reported crowns finally felt natural

BRUXING: PARAFUNCTIONAL TOOTH CONTACT

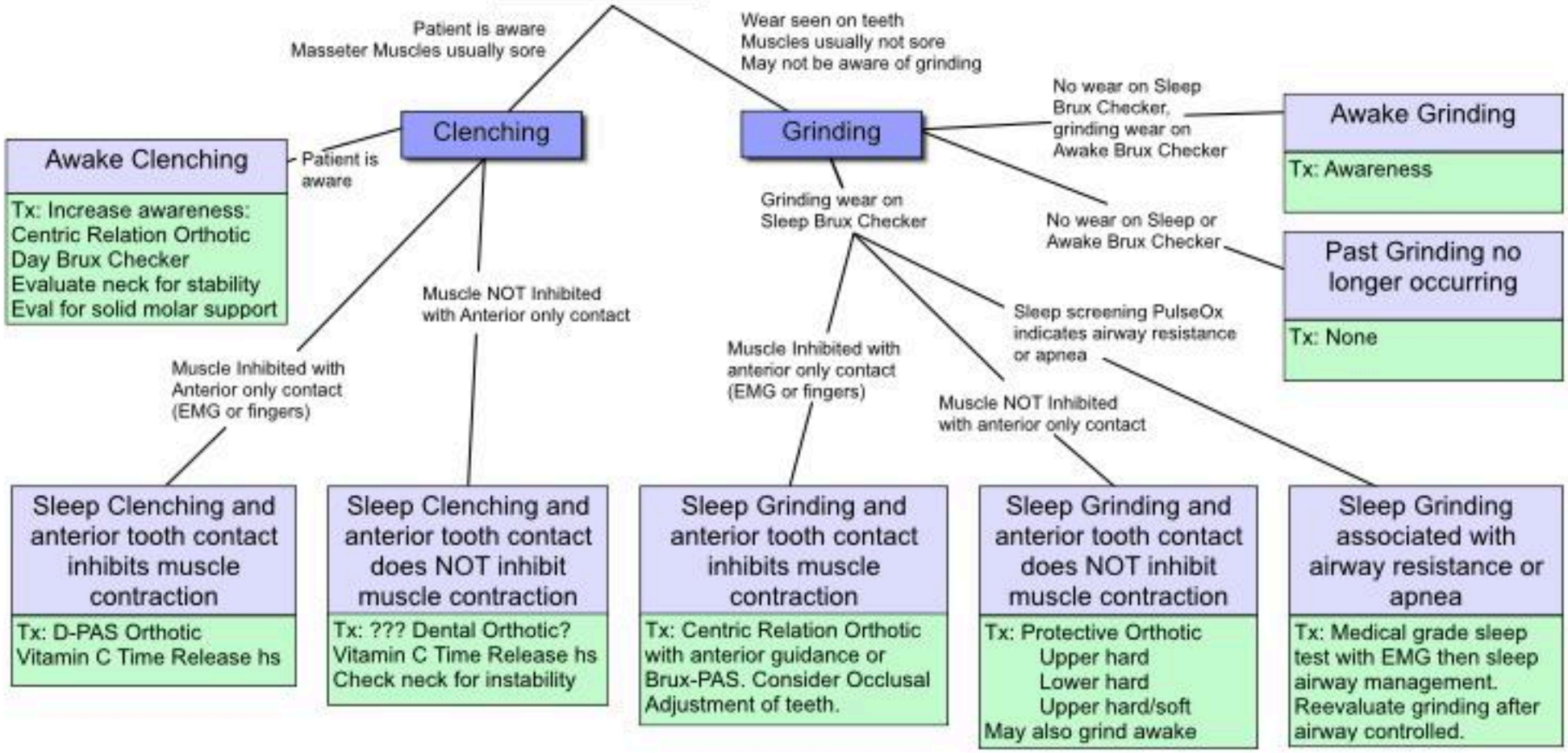

BRUXING: PARAFUNCTIONAL TOOTH CONTACT

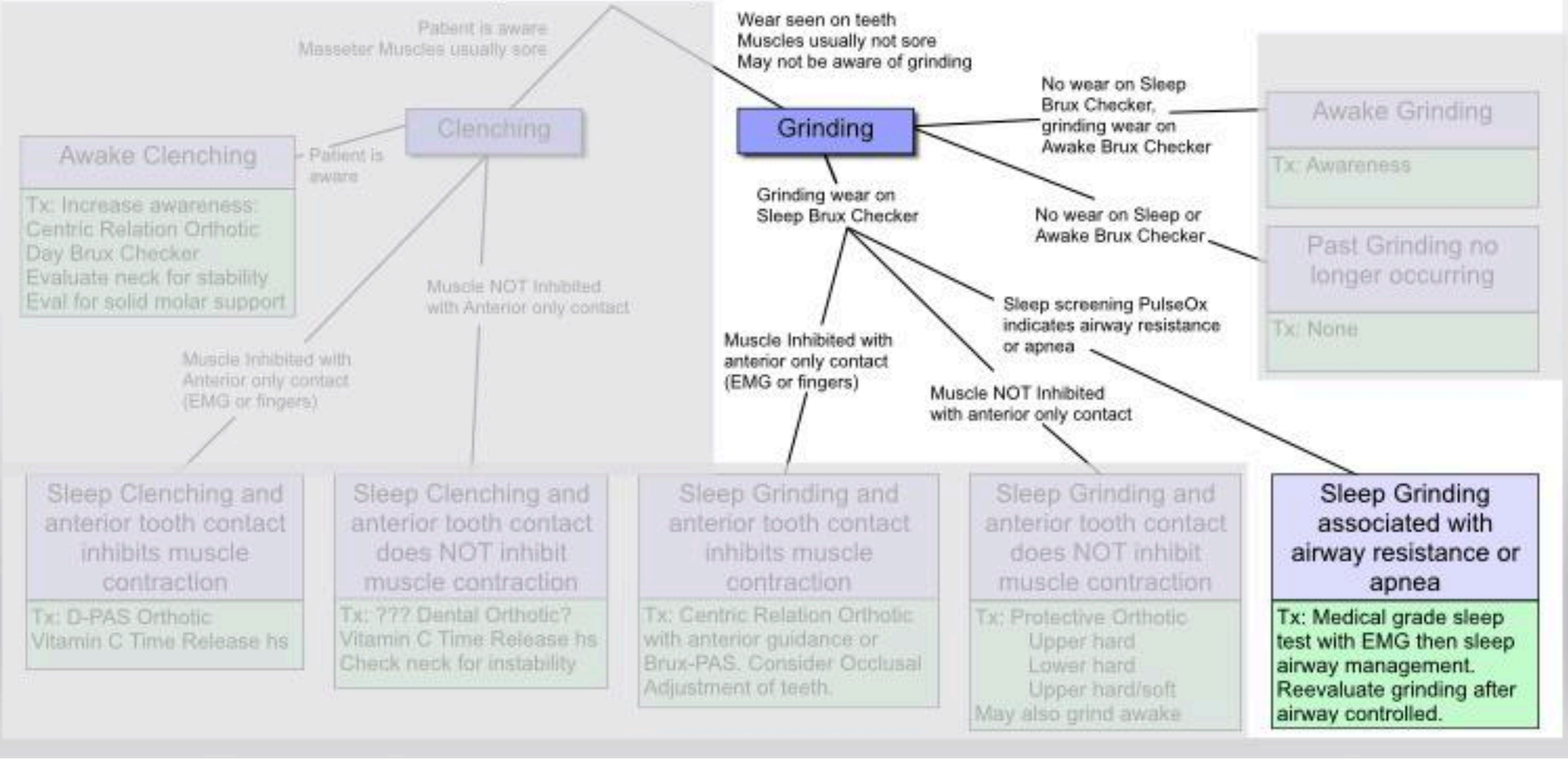

Mandibular Advancement Devices (MAD)
Open the airway by advancing the mandible and tongue

Normal Airway

Upper Airway Resistance
Snoring in men
Purring in women

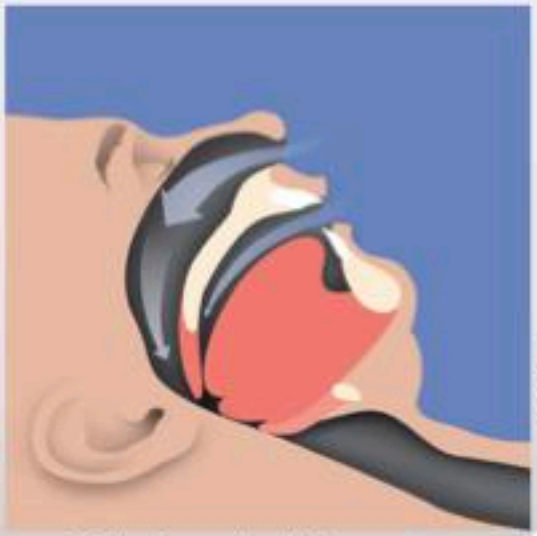

Obstructed Apnea
Airway

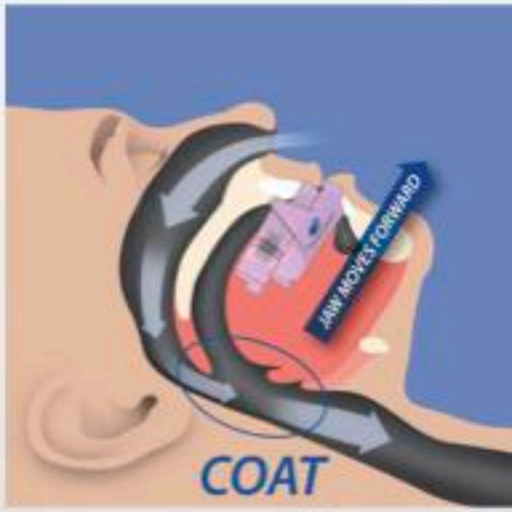

Airway opens with
Mandibular Advancement

Better Solutions:
Treat Causes

Images from Somnodent https://somnomed.com/us

example: worldwide insulin shortage

Disordered Breathing Disease Progression

Disease Stage 1

Predisposing Factors

Tongue Tie, Lip Tie
Bottle Fed as Infant
Dysfunctional Swallow
Allergies
Nasal Obstruction
Large Tonsil
Large Adenoids
Mid-face Deficient
Mandibular Deficient

Small Airway

Disease Stage 2

Compensation: Airway Maintained

Signs
- Tongue Bracing
- Indents in Tongue
- Head Postured Forward
- Jaw Postured Forward
- Sore Masseters
- Sore Neck Muscle
- Sleep Teeth Grinding
- Tooth Wear
- Mouth Breathing

Symptoms
- Facial Ache
- Not Waking Rested
- Daily Fatigue
- Neck Soreness

Disease Stage 3

Airway Partial Collapse

Signs
- All of stage 1 and 2 plus…..
- Upper Airway Resistance
- 2% Drop O_2 Saturation
- RERA- Respiratory Arousals
- ⬇ Growth Hormone

Symptoms
- Heart Rate Fluctuation
- Snoring or "Purring"
- Weight Gain
- Cognitive Impairment, ADD
- Hyperactivity

Disease Stage 4

Airway Full collapse

Signs
- All of stage 1, 2, 3 plus….
- 3+% drop O_2 Saturation
- Cardiovascular Damage
- Elevated BP
- GERD

Symptoms
- All of stage 2, 3 plus….
- Apnea

John R. Droter DDS

Disordered Breathing Disease Stage 4

OSA- Obstructive Sleep Apnea

<u>AHI- Apnea Hypopnea Index</u>

Apnea and Hypopnea events per hour

Apnea- Stop airflow for 10 seconds

Hypopnea- <50% airflow or 3+% O_2 Desaturation

AHI 1-4 "Normal" ??	AHI 5-15 Mild OSA	AHI 15-30 Moderate OSA	AHI 30+ Severe

<u>Signs</u>

- Cardiovascular Damage
- Elevated BP
- GERD
- ↓ Growth Hormone

<u>Symptoms</u>

- Apnea, Hypopnea
- Snoring
- Not Waking Rested, Daily Fatigue
- Cognitive Impairment

Irreversible Damage

John R. Droter DDS

Handout for Patients

www.jrdroter.com

Disordered Breathing Disease Progression

Disease Stage 1	Disease Stage 2	Disease Stage 3	Disease Stage 4
Predisposing Factors	Compensation: Airway Maintained	Airway Partial Collapse	Airway Full collapse
Tongue Tie, Lip Tie Bottle Fed as Infant Dysfunctional Swallow Allergies Nasal Obstruction Large Tonsil Large Adenoids Mid-face Deficient Mandibular Deficient Small Airway	Signs Tongue Bracing Indents in Tongue Head Postured Forward Jaw Postured Forward Sore Masseters Sore Neck Muscle Sleep Teeth Grinding Tooth Wear Mouth Breathing Symptoms Facial Ache Not Waking Rested Daily Fatigue Neck Soreness	Signs All of stage 1 and 2 plus..... Upper Airway Resistance 2% Drop O_2 Saturation RERA- Respiratory Arousals ↓ Growth Hormone Symptoms Heart Rate Fluctuation Snoring or "Purring" Weight Gain Cognitive Impairment, ADD Hyperactivity	Signs All of stage 1, 2, 3 plus.... 3+% drop O_2 Saturation Cardiovascular Damage Elevated BP GERD Symptoms All of stage 2, 3 plus.... Apnea

John R. Droter DDS

Disordered Breathing Disease Stage 4

OSA- Obstructive Sleep Apnea

AHI- Apnea Hypopnea Index

Apnea and Hypopnea events per hour

Apnea- Stop airflow for 10 seconds

Hypopnea- <50% airflow or 3+% O_2 Desaturation

AHI 1-4 "Normal" ??	AHI 5-15 Mild OSA	AHI 15-30 Moderate OSA	AHI 30+ Severe

Signs
Cardiovascular Damage
Elevated BP
GERD
↓ Growth Hormone

Symptoms
Apnea, Hypopnea
Snoring
Not Waking Rested, Daily Fatigue
Cognitive Impairment

Irreversible Damage

John R. Droter DDS

Disordered Breathing is a very serious condition that can be fatal.

Young patients can be treated, older patients can only be managed.

There are many causes. This is not a single disease with a single treatment.

Causes:
Nasal Obstruction
Tonsil Adenoids Obstruct
Mouth breathing
Tongue hypertrophy
Tongue Adipose
Inflammation Pharyngeal Tissue
Central Apnea

New York 2013
Train took curve at 80mph
4 Dead, 61 Injured

Sleep Apnea

Look at neck Size:
17 inches or greater??

Train engineer 'was nodding off and caught himself too late,' union rep says

By Shimon Prokupecz, Mike Ahlers and Ray Sanchez, CNN
updated 7:21 PM EST, Tue December 3, 2013

Engineer was 'in a daze' before crash

BREAKING NEWS

Union rep: Train engineer was 'nodding off'



No sign brakes failed, says NTSB

William Rockefeller "caught himself too late" before the deadly Bronx train derailment, a union representative said. FULL STORY

- What did the engineer not say
- What it's like to be in a train crash
- Train took curve at 80 mph | Photos
- Opinion: High-tech trains safer?
- The safest spot on a train

Obstructive Sleep Apnea OSA

Mega Bus





Why are Airway and Sleep Grinding Related?

Sleep Grinding Preceding Events

- Rise in autonomic, cardiac sympathetic dominance
- Withdraw of cardiac parasympathetic dominance
- Rise in Brain EEG
- Rise in heart rate
- Rise in suprahyoid muscle tone
- Two big breaths
- Tooth Grinding- Rhythmic masticatory muscle activity

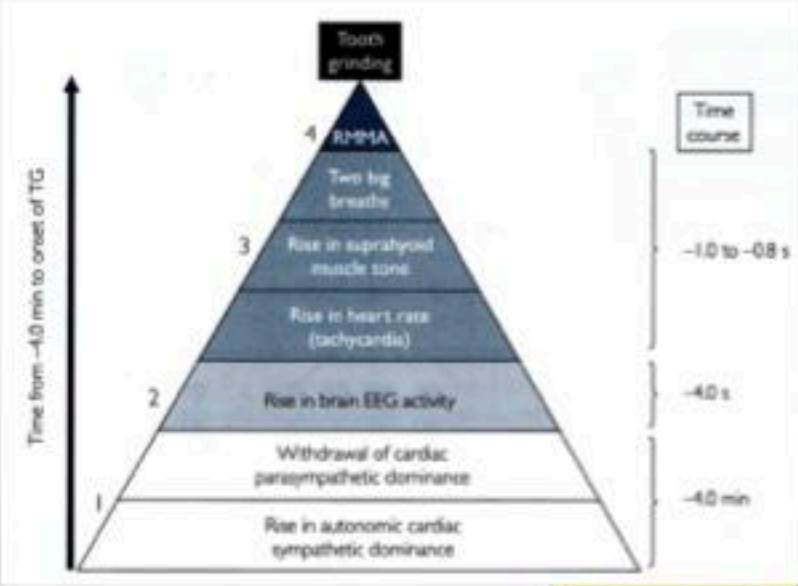

HUYNH, N., KATO, T., ROMPRE, P. H., OKURA, K., SABER, M., LANFRANCHI, P. A., et al. (2006). Sleep bruxism is associated to micro-arousals and an increase in cardiac sympathetic activity. *Journal of Sleep Research*, *15*(3), 339–346.

Lavigne, G. J., Cistulli, P. A., & Smith, M. T. (2009). Sleep medicine for dentists. *Chicago, IL: Quintessence*, *210*. Page 119

Is Sleep Grinding a parasympathetic response to quell the sympathetic response?

Rhythmic jaw movements lower heart rate

McLaughlin J, Powell DA. Pavlovian heart rate and jaw movement conditioning in the rabbit: effects of medial prefrontal lesions. Neurobiology of learning and memory. 1999;71(2):150–166

Schames SE, Schames J, Schames M, Chagall-Gungur SS
J Calif Dent Assoc. 2012 Aug;40(8):670-1, 674-6.
Sleep bruxism, an autonomic self-regulating response by triggering the trigeminal cardiac reflex.

2. Does this occur awake or asleep?

Brux Checker
Great Lakes Orthodontics

0.1mm Mylar

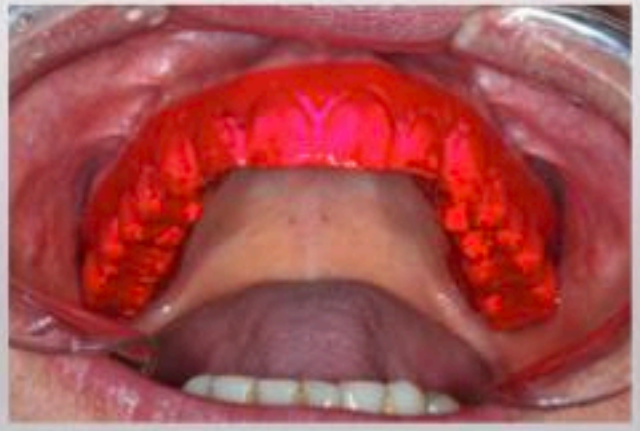

Made on Biostar Machine

If sleep grinding, is there an airway issue?
(Upper Airway Resistance or Obstructive Sleep Apnea)

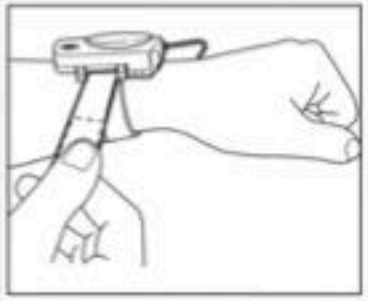

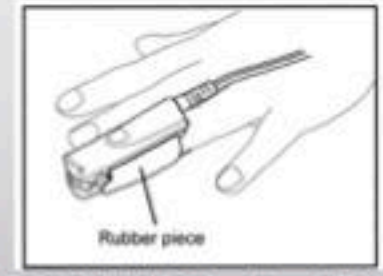

High Resolution
Pulse Oximetry

Data every 1
second average
over 3 seconds

PULSOX 300i, Konica Minolta
with data analysis Patient Safety, Inc.

Order PULSOX: Go to my website
jrdroter.com ….. Doctor Links

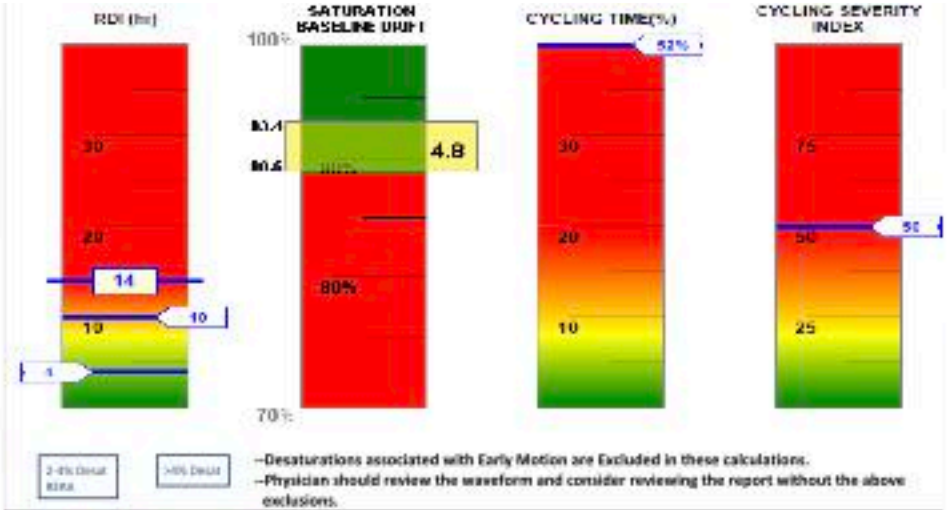

PATTERN BASED REPORT

OXYGEN SATURATION BASELINE ANALYSIS

Oxygen Saturation Baseline Drift(OSBD) (normal <= 3)	5
Initial Saturation Baseline	93
Lowest Saturation Baseline	89
Highest Saturation Baseline	93

Baseline is determined by the Mean SpO2 during 3 Minute window without Artifact and without Events.



SPO2 CYCLING

% Time in Cycling (Duration)	52%	(02:50:14)
Cycling Frequency	45	
96% - Lowest Sat	12	
Cycling Severity Index	50	

The total time oxygen saturation was <= 88% was 00:13:39

TRADITIONAL REPORT

ODI4:	11
Total ODI4 Events:	58
Time in ODI4 Events:	00:29:26
Avg ODI4 Event Duration:	00:00:28
<=88% ODI4 Events:	23
<=88% Longest Duration:	00:01:21
Minimum SpO2:	84
Avg Low 10% SpO2:	86
Avg Low SpO2:	89
Avg Low SpO2 <=88%:	87

Definition of ODI4 Event: a fall in oxygen saturation of at least 4% and persisting greater than 3 seconds.

%SpO2	DURATION	%TOTAL
94-100	00:16:37	5%
88-94	04:57:26	91%
80-88	00:13:39	4%
70-80	00:00:00	0%
<= 70	00:00:00	0%
Total	05:27:42	100%
Motion Artifact	00:00:07	0.04%
Error Signal	00:00:05	0.03%

4. If sleep grinding, is there an airway issue?
(Upper Airway Resistance or Obstructive Sleep Apnea)

High Resolution Pulse Oximetry

Data every 1 second average over 3 seconds

Patient Safety Inc.

SLEEPSAT

SATSCREEN

Order Pulse Ox and Software: Go to my website or www.patientsafetyinc.com

Sleep SAT is the replacement for PULSOX 300i, Konica Minolta no longer made

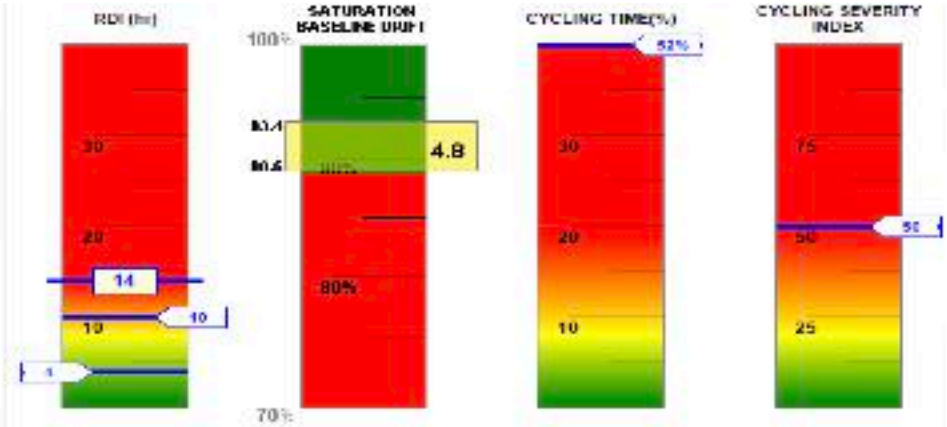

–Desaturations associated with Early Motion are Excluded in these calculations.
–Physician should review the waveform and consider reviewing the report without the above exclusions.

PATTERN BASED REPORT

OXYGEN SATURATION BASELINE ANALYSIS

Oxygen Saturation Baseline Drift(OSBD) (normal <= 3)	5
Initial Saturation Baseline	93
Lowest Saturation Baseline	89
Highest Saturation Baseline	93

Baseline is determined by the Mean SpO2 during 3 Minute window without Artifact and without Events.



SPO2 CYCLING

% Time in Cycling (Duration)	52%	(02:50:14)
Cycling Frequency	45	
96% - Lowest Sat	12	
Cycling Severity Index	50	

The total time oxygen saturation was <= 88% was 00:13:39

TRADITIONAL REPORT

ODI4:	11
Total ODI4 Events:	58
Time in ODI4 Events:	00:29:26
Avg ODI4 Event Duration:	00:00:28
<=88% ODI4 Events:	23
<=88% Longest Duration:	00:01:21
Minimum SpO2:	84
Avg Low 10% SpO2:	86
Avg Low SpO2:	89
Avg Low SpO2 <=88%:	87

Definition of ODI4 Event: a fall in oxygen saturation of at least 4% and persisting greater than 3 seconds.

%SpO2	DURATION	%TOTAL
94-100	00:16:37	5%
88-94	04:57:26	91%
80-88	00:13:39	4%
70-80	00:00:00	0%
<= 70	00:00:00	0%
Total	05:27:42	100%
Motion Artifact	00:00:07	0.04%
Error Signal	00:00:05	0.03%

4. If sleep grinding, is there an airway issue?
(Upper Airway Resistance or Obstructive Sleep Apnea)

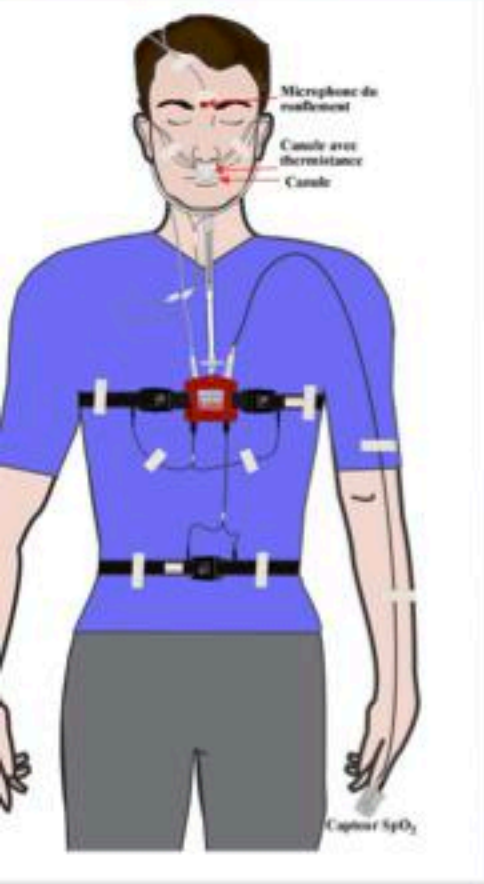

MEDIBYTE

OROFACIAL MOVEMENT (OFM) AND RESPIRATORY REPORT

PATIENT

Patient ID	
Study Date	
Date of Birth	
Age	70
Sex	Male
Height	5' 8" (173 cm)
Weight	182.0 lbs
BMI	27.0
Waist-Hip Ratio	0.00 (W: 0", H: 0")

AHI/REI **32.5**

RDI: 40.4

ODI: 24.0

Severe >30
Moderate 15-30
Mild 5-15
Normal <5

Chart Code	0987654321
Referring Physician	
Start Time	00:24:57
End Time	06:37:41
Total Recording Time	373.1 minutes

HOME SLEEP APNEA TESTING DEVICE

The MediByte®, 12-channel Type 3 home sleep apnea and snoring recorder, was used to evaluate sleep-disordered breathing. The following parameters were recorded for a duration of 373 minutes: Orofacial Movement EMG, Snoring Audio, Volume in decibels, Snoring (high frequency vibrations in airflow), nasal pressure Airflow, thermal Airflow, RIP Chest/Abdominal/Sum Effort, SpO2, Pulse Rate, Body Position, and User Events.

Note: Respiratory events were scored using the following rules: Apneic events required a 80% or more reduction in airflow. Hypopneic events required a 30% reduction in airflow along with an accompanying 3% oxygen desaturation.

COMMENTS

99.1% of all breaths had flow limitation which is associated with upper airway resistance. AHI & RDI were 32.5 and 40.4, respectively. Oxygen Desaturation Index (ODI) was 24.0 and time below 88% SpO2 was 0.2 minutes. Total bruxism index was 12.7 and total supine bruxism index was 16.8.

OXIMETRY

SpO_2 Range	% Time	minutes
96-100 %	1.8%	6.7
94-96 %	32.2%	119.7
90-94%	52.3%	194.8
88-90 %	12.4%	46.3
86-88 %	1.0%	3.6
80-100 %	99.9%	371.2
85-89 %	0.2%	0.9
70-79 %	0.0%	0.0
60-69 %	0.0%	0.0
50-59 %	0.0%	0.0
< 50%	0.0%	0.0
Total <88 %	0.1%	0.2

	Total	ODI Index
Desaturations ≥3%	149	24.0

	Mean	Min.	Max.
SpO_2 (%)	94.9	80.0	98.0
Pulse Rate	49.8	40.0	100.0

PULSE

Pulse Rate Range	% Time	minutes
125-150	0.0%	0.0
100-125	0.0%	0.0
75-100	0.4%	1.4
50-75	45.0%	169.5
25-50	54.1%	201.2

4. If sleep grinding, is there an airway issue?
(Upper Airway Resistance or Obstructive Sleep Apnea)

EMG
Masseter
Bruxism Index
16.8 per hour
on back

EVENTS BY BODY POSITION	Supine	Non-Supine
% Time in Position	48.7%	50.7%
Total Breaths	2936	3547
Snoring Flow (SNR)	699	574
Flow Limitation (FL)	714	710
RERAs	22	27
RDI	54.5	27.3
Desaturations	108	41
ODI	35.7	13.0
Apneas + Hypopneas	143	59
AHI/REI	47.2	18.7
Bruxism Events	51	27
Bruxism Index	16.8	8.6

zMachine

GENERAL sleep

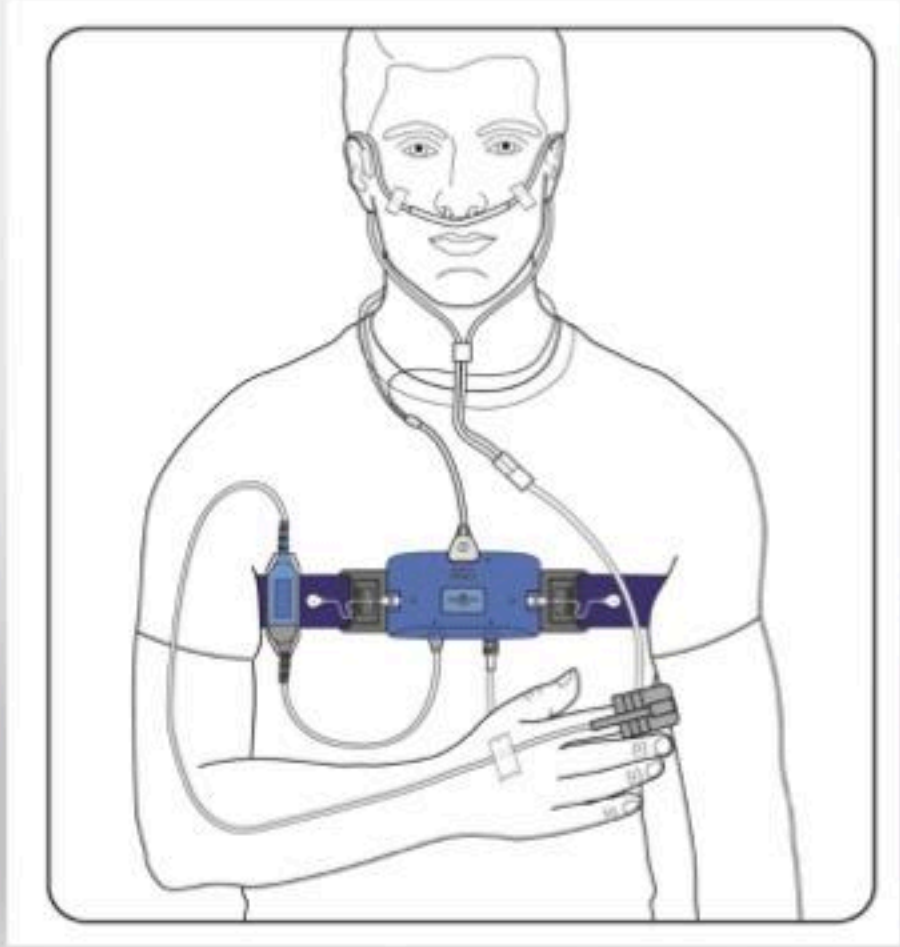

Patient: M Y
Study Date: 2018-09-27 Study ID: 1124990976
3% Threshold

AHI: 8.9
AHI is how many times an hour your blood oxygen goes down.

RDI: 8.9
RDI is how many times an hour your sleep is disturbed due to respiration

Date of Birth: 1998
Age: 20
Sex: F

Height: 63 Inches
Weight: 105 Pounds
BMI: 18.60

Note:

GENERAL sleep
Zmachine® Synergy
Home Sleep Test Report
Study Ordered by:
John R. Droter, DDS
Scored by: Computer

Study Details: Computer Generated Scoring
The following parameters were recorded using a Zmachine Synergy (General Sleep Corporation): ECG for sleep staging & arousals; respiratory inductance plethysmography for thoracic respiratory effort; pressure transducer for respiratory airflow & snore; pulse oximeter for SpO2, pulse, & optical plethysmograph; and tri-axis accelerometer for body position. Hypopneas were scored per AASM recommended definition of 3% desaturation.

Times and Durations	
Lights off	2018-09-27 01:47:32
Lights on	2018-09-27 08:42:54
Total Recording Time (TRT)	536.8 min.
Time in Bed (TIB)	414.0 min. (81.7% of TRT) [, 6 hours 54 minutes
Total Sleep Time (TST)	396.8 min. (95.9% of TIB)
Sleep Efficiency (SE)	95.9 % of TIB
Latency to Persistent Sleep (LPS)	8 min
Latency to Deep Sleep (LDEEP)	19 min
Latency to REM Sleep (LREM)	8.5 min
Total Light Sleep Time N1+N2	207.9 min. (52.4% of TST)
Total Deep Sleep Time N3 SWS	95.7 min. (24.1% of TST)
Total REM Time	93.2 min. (23.5% of TST)
SpO_2 < 89% cumulative time	0 min.
SpO_2 < 89% longest span	0 min.

Awakenings During Sleep	
Wake After Sleep Onset (WASO)	13 min
≥ 1-Epoch Awakenings	18 (2.7 per sleep hour)
≥ 3-Epoch Awakenings	0 (0 per sleep hour)

WASO is the cumulative wake time following LPS; ≥ 1-Epoch Awakenings is the number of times the patient wakes for one epoch (i.e. 30 seconds) or more after LPS; and ≥ 3-Epoch Awakenings is the number of times the patient wakes for three epochs or more after LPS (this is a subset of ≥ 1-Epoch

Sleep Study Ranges of Normal
Sleep Latency 10-20 min
Latency to REM 90 min
Sleep Efficiency >85%

N1 2% - 5%
N2 45% - 55%
N3 Deep Sleep 10% - 20%
R 8% - 25%: 48 min. to 96 min
REM Sleep 20% - 25%
R 8% - 25%: 96 min. to 120 min

REM to REM is about 90 min
4-5 cycle per night
REM time longer as night goes on

Deep N3 SWS slow wave sleep is first third of night, less as we age

TRT is the total duration of the recording, TIB is the elapsed time from lights off to lights on; TST is the cumulative time scored as any stage of sleep; SE is 100×(TST÷TIB) expressed as a percentage; AHI is apneas + hypopneas per hour of sleep time; RDI is apneas + hypopneas + RERAs per hour of sleep time; and RII is apneas + hypopneas + RERAs per hour of recording time.

LPS is the elapsed time to the beginning of the first period in which 10 of 11 minutes are scored as any stage of sleep (i.e. the start of persistent sleep); LDEEP is the elapsed time to the beginning of first epoch of Deep Sleep; and LREM is the elapsed time to the beginning of first epoch of REM.

Respiratory Events

Body Position		
72.1%	Supine/hr	9.0
0%	Prone/hr	0
12.9%	Left/hr	4.5
14.8%	Right/hr	9.8

Sleep Stages

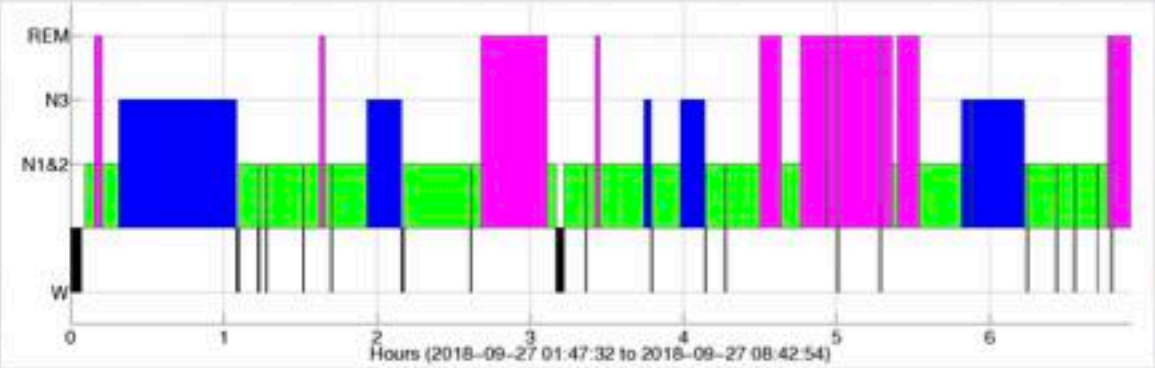

Treating Common TMDs in a General Practice

Management

Diagnosis	Pattern	~~Treatment~~
Sleep Grinding Airway Related	Worn Teeth Upper Airway Resistance	Mandibular Advancement Appliance (after MD approves)

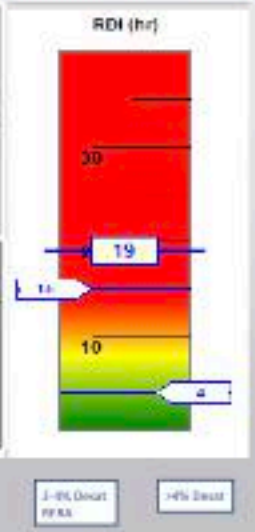

Pulse Ox Screening

Refer to Medical Sleep Doctor

Get approval for Mandibular Advancement Appliance

Verify Airway Improves

19 events/hr before

2 events/hr with Orthotic

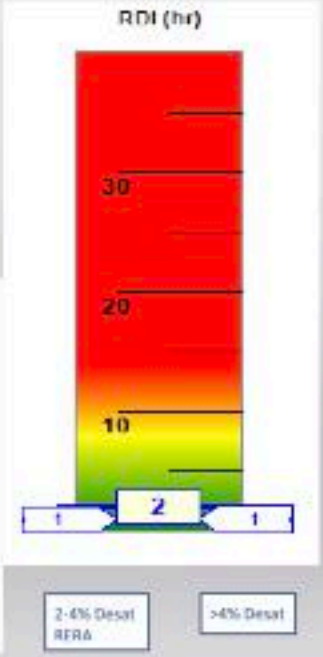

PULSOX 300i, Konica Minolta
with data analysis Patient Safety, Inc.

Narval CC
Great Lakes Ortho

Anterior Repositioning Orthotic

Minolta Pulse Ox

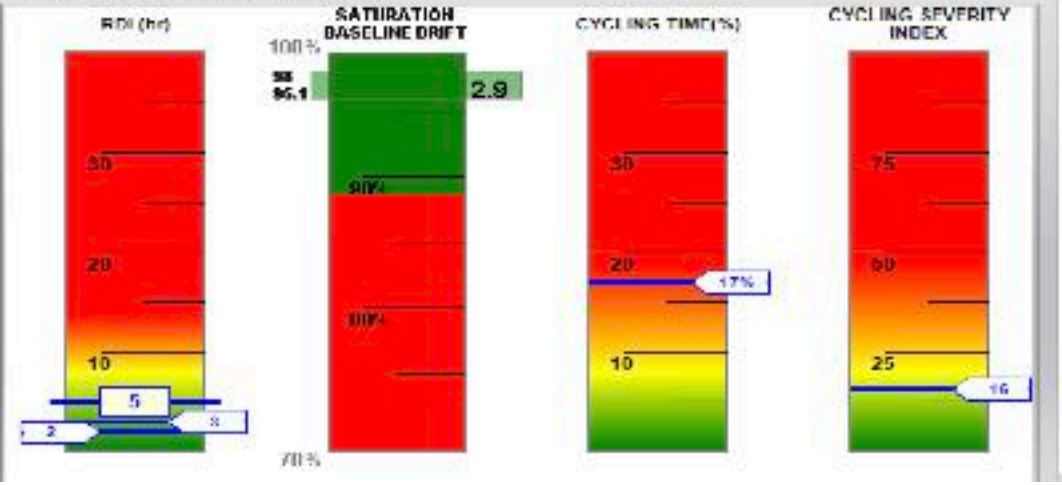

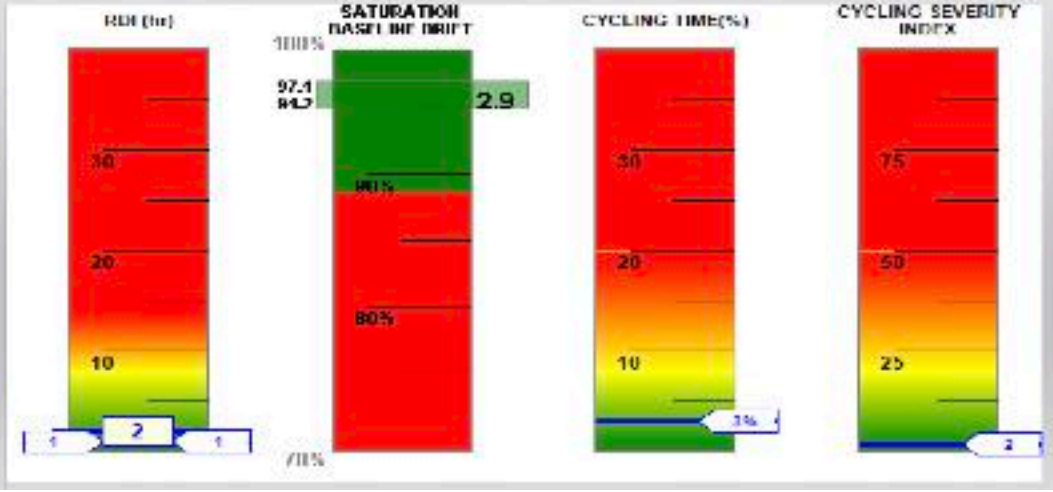

Anterior Repositioning Orthotic

BRUXING: PARAFUNCTIONAL TOOTH CONTACT

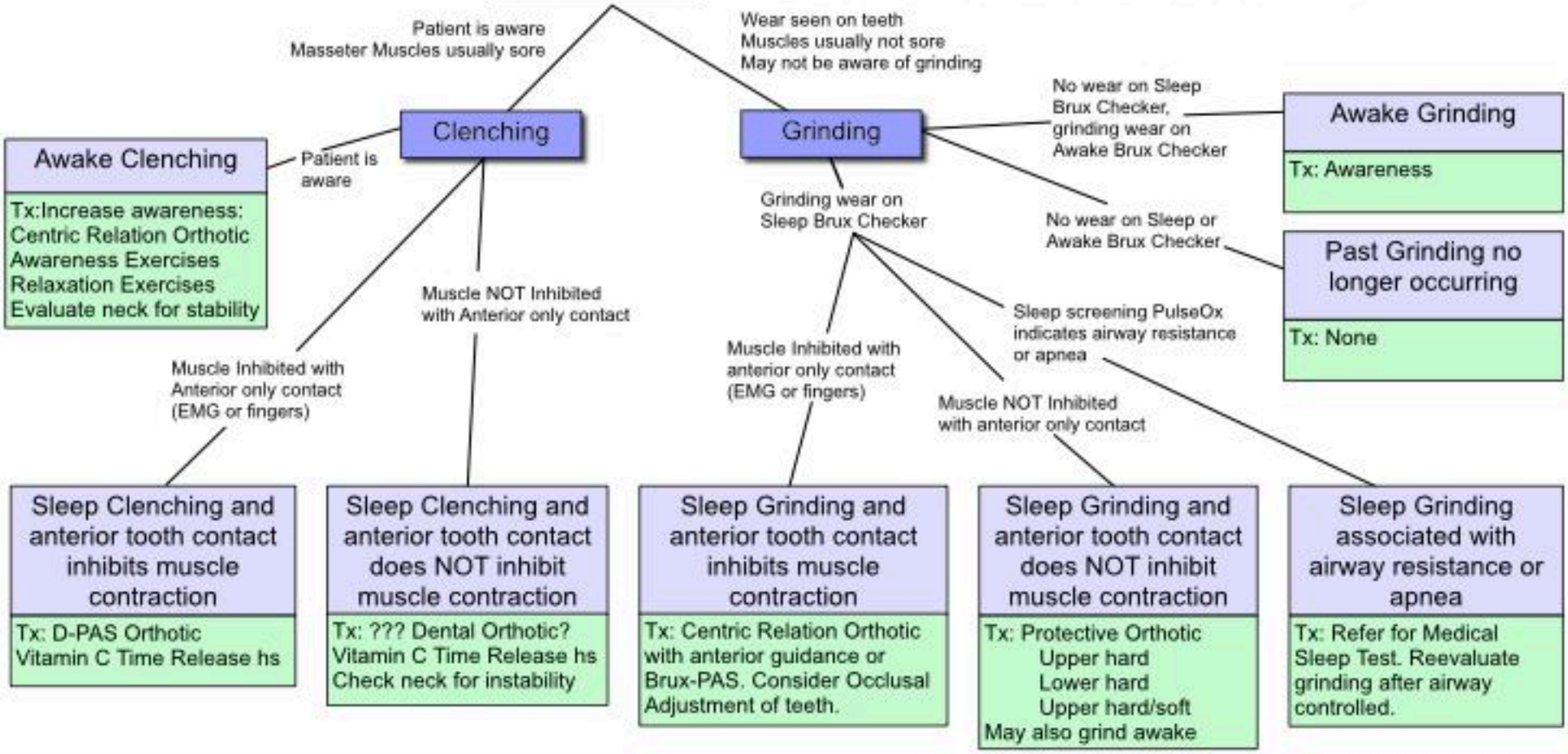

5 Levels of Occlusal Orthotic Therapy

Level 1
Protective Therapy for Sleep Grinding or Clenching

Store bought $20

Level 2
Clenching Inhibition

Palatal Anterior Stop

CR Orthotic

Level 3
Airway Management

Level 4
Diagnose and Treat Occlusal Muscle Dysfunction

Airway Orthotic

Level 5
TMJ Rehabilitation
Unfavorably Adapted Joint
Actively Degenerating Joint

Indexed Orthotic

Condylar Distraction

Level 1
Protective therapy for Grinding or clenching
Joint status- healthy or fav adapt
Occlusal status- Non pathologic
Protective guard

Level 2
Tx Clenching
Joint status- healthy or favorable adaptation
Occlusal status- Non pathologic
Anterior Stop Orthotic

Level 3
Airway Management Orthotics

Level 4
Tx OMD
Joint status- healthy or favorable adaptation
Occlusal status- Pathologic
CR Orthotic
Occlusal Equilibration

Level 5
Tx unfavorably adapted damaged joint
Orthopedic Orthotic
Tx actively degenerating joints
Orthopedic and Medical Management



TMD for the GP

What is a Click?

John R Droter DDS
Annapolis, Maryland

www.jrdroter.com

TMDs- What are the choices? (190 Diagnoses, 7 Categories)

1. TMJ Damage

Adhesions and ankylosis of temporomandibular joint
Avascular Necrosis Mandibular Condyle
Cartilage Fibrillation, Mandibular Condyle, Fossa
Closed Lock, Jaw Cartilage, Acute
Closed Lock, Jaw Cartilage, Chronic
Closed Lock, Jaw Cartilage, Intermittent, Mechanically dysfunctional
Crush Injury Mandibular Condyle
Crystal arthropathy, unspecified, TMJ
Dislocation jaw cartilage due to injury, Sequela
Dislocation jaw cartilage with reduction, favorable adaptation, TMJ
Dislocation jaw cartilage without reduction, favorable adaptation, TMJ
Effusion, TMJ
Impingement Retrodiscal Tissue
Inflammatory Tissue Bone Resorption, TMJ Condyle
Loose Body (Joint Mice), TMJ
Malignant neoplasm of bones of skull and face
Open Lock TMJ, Recurring
Osteoarthritis TMJ, active degeneration
Osteoarthrosis- Inactive
Osteochondritis Dissecans TMJ
Osteolysis Mandibular Condyle, Active
Perforation Meniscus, TMJ
Perforation Pseudodisc, TMJ
Psoriatic Arthritis TMJ
Rheumatoid Arthritis Sero Negative TMJ

2. Muscles of the TMJ

Dystonia
Habitual posture forward mandible
Hemifacial Muscle spasm
Inhibitory Reflex Dysfunction, Periodontal Ligament Masseter Muscle
Muscle Atrophy, TMJ
Muscle Bracing Neck Stabilization
Muscle Bracing Pain Avoidance
Muscle Bracing TMJ stabilization
Muscle Bracing Airway **Patency** (with Tongue)
Muscle Contracture Fibrosis Lateral Pterygoid
Muscle Contracture Fibrosis Masseter, Medial Pterygoid, Temporalis
Muscle Fatigue Overuse
Muscle Hypertrophy TMJ Muscles

3. Cranial Alignment/Occlusion

Cranial Distortion / Misalignment
Hemifacial Hypoplasia
Hyper Occlusal Awareness
Iatrogenic Orthotic Damage
Malocclusion Anterior Open Bite
Malocclusion Centric occlusion MaxIC discrepancy
Malocclusion Deep Bite
Malocclusion due to mouth breathing
Malocclusion due to TMJ bone loss
Malocclusion due to tongue, lip or finger habits
Malocclusion Insufficient anterior occlusal guidance
Malocclusion lack of posterior occlusal support
Malocclusion Posterior Openbite Bilateral
Malocclusion Posterior Openbite Unilateral
Malocclusion unspecified
Malposition /Misalignment: Maxilla, Temporal Bone, Mandible
Mandibular asymmetry
Mandibular hyperplasia
Mandibular hypoplasia
Mandibular Retrognathia
Maxillary asymmetry
Maxillary hyperplasia
Maxillary hypoplasia
Maxillary Retrognathia
Occlusal Adaptation, Favorable
Occlusal Dependency for Joint Stabilization/ Proprioception
Tooth Intrusion
Tooth Supereruption

4. Cervical Damage

Cervical Vertebrae Alignment Dysfunction
Cervicocranial Syndrome
Muscle Guarding due Neck Instability
Trigger Point Neck Muscle with Referred Pain
Trigger Point Neck Muscle, Localized Pain

5. Parafunction

Excessive Tooth Wear, Damage
Hypersensitive Occlusion
Parafunctional Clenching Teeth, Awake
Parafunctional Clenching Teeth, Sleep
Parafunctional Grinding Teeth, Awake
Parafunctional Grinding Teeth, Sleep
Parafunctional Clench/Grind Wiggle
Parafunctional Tongue Bracing avoiding uncomfortable tooth contact
Parafunctional Tongue Bracing Neck stabilization
Parafunctional Tongue Bracing to maintain Airway
Parafunctional Tongue Bracing unknown cause

6. Whole Body / Systemic

Lyme Disease Arthritis
Magnesium Deficiency
Obstructive Sleep Apnea
Osteoporosis without current pathological fracture
Pathological Habitual Movement Pattern
Postural Disharmony Standing
Postural Disharmony Walking
Postural Forward Head Position
Upper Airway Resistance, UARS

7. Other

Nerve Entrapment Masseteric Nerve due to Masseteric hypertonicity
Neuroma Trigeminal Nerve
Obsessive-Compulsive Personality Disorder
Other
Otitis Ear Infection
Pain disorder exclusively related to psychological factors. Somatoform pain disorder
Pain disorder with related psychological factors
Peripheral Sensitization

TMDs- What are the choices? (190 Diagnoses, 7 Categories)

1. TMJ Damage

Impingement Retrodiscal Tissue

Dislocation of Jaw Cartilage

Crystal arthropathy, unspecified, TMJ
Dislocation jaw cartilage due to injury, Sequela
Dislocation jaw cartilage with reduction, favorable adaptation, TMJ
Dislocation jaw cartilage without reduction, favorable adaptation, TMJ
Effusion, TMJ

Osteolysis Mandibular Condyle, Active
Perforation Meniscus, TMJ
Perforation Pseudodisc, TMJ
Psoriatic Arthritis TMJ
Rheumatoid Arthritis Sero Negative TMJ

2. Muscles of the TMJ

Dystonia
Habitual posture forward mandible
Hemifacial Muscle spasm
Inhibitory Reflex Dysfunction, Periodontal Ligament Masseter Muscle
Muscle Atrophy, TMJ
Muscle Bracing Neck Stabilization
Muscle Bracing Pain Avoidance
Muscle Bracing TMJ stabilization
Muscle Bracing Airway **Patentcy** (with Tongue)
Muscle Contracture Fibrosis Lateral Pterygoid
Muscle Contracture Fibrosis Masseter, Medial Pterygoid, Temporalis
Muscle Fatigue Overuse
Muscle Hypertrophy TMJ Muscles

3. Cranial Alignment/Occlusion

Cranial Distortion / Misalignment
Hemifacial Hypoplasia
Hyper Occlusal Awareness
Iatrogenic Orthotic Damage
Malocclusion Anterior Open Bite
Malocclusion Centric occlusion MaxIC discrepancy
Malocclusion Deep Bite
Malocclusion due to mouth breathing
Malocclusion due to TMJ bone loss
Malocclusion due to tongue, lip or finger habits
Malocclusion Insufficient anterior occlusal guidance
Malocclusion lack of posterior occlusal support
Malocclusion Posterior Openbite Bilateral
Malocclusion Posterior Openbite Unilateral
Malocclusion unspecified

Malposition /Misalignment: Maxilla, Temporal Bone, Mandible
Mandibular asymmetry
Mandibular hyperplasia
Mandibular hypoplasia
Mandibular Retrognathia
Maxillary asymmetry
Maxillary hyperplasia
Maxillary hypoplasia
Maxillary Retrognathia
Occlusal Adaptation, Favorable
Occlusal Dependency for Joint Stabilization/ Proprioception
Tooth Intrusion
Tooth Supereruption

4. Cervical Damage

Cervical Vertebrae Alignment Dysfunction
Cervicocranial Syndrome
Muscle Guarding due Neck Instability
Trigger Point Neck Muscle with Referred Pain
Trigger Point Neck Muscle, Localized Pain

5. Parafunction

Excessive Tooth Wear, Damage
Hypersensitive Occlusion
Parafunction clech/grind wiggle
Parafunctional Clenching Teeth, Awake
Parafunctional Clenching Teeth, Sleep
Parafunctional Grinding Teeth, Awake
Parafunctional Grinding Teeth, Sleep
Parafunctional Tongue Bracing avoiding uncomfortable tooth contact
Parafunctional Tongue Bracing Neck stabilization
Parafunctional Tongue Bracing to maintain Airway
Parafunctional Tongue Bracing unknown cause

6. Whole Body / Systemic

Lyme Disease Arthritis
Magnesium Deficiency
Obstructive Sleep Apnea
Osteoporosis without current pathological fracture
Pathological Habitual Movement Pattern
Postural Disharmony Standing
Postural Disharmony Walking
Postural Forward Head Position
Upper Airway Resistance, UARS

7. Other

Nerve Entrapment Masseteric Nerve due to Masseteric hypertonicity
Neuroma Trigeminal Nerve
Obsessive-Compulsive Personality Disorder
Other
Otitis Ear Infection
Pain disorder exclusively related to psychological factors. Somatoform pain disorder
Pain disorder with related psychological factors

aka What is a Click?

John R Droter DDS
Annapolis, Maryland

A joint joins two bones that allows movement between the two bones

TMJ has 2 Joint Compartments:

Upper- Translation
Lower- Rotation

Rotate
Slide
Pivot

Solid end point closing
Ligamentous end point opening

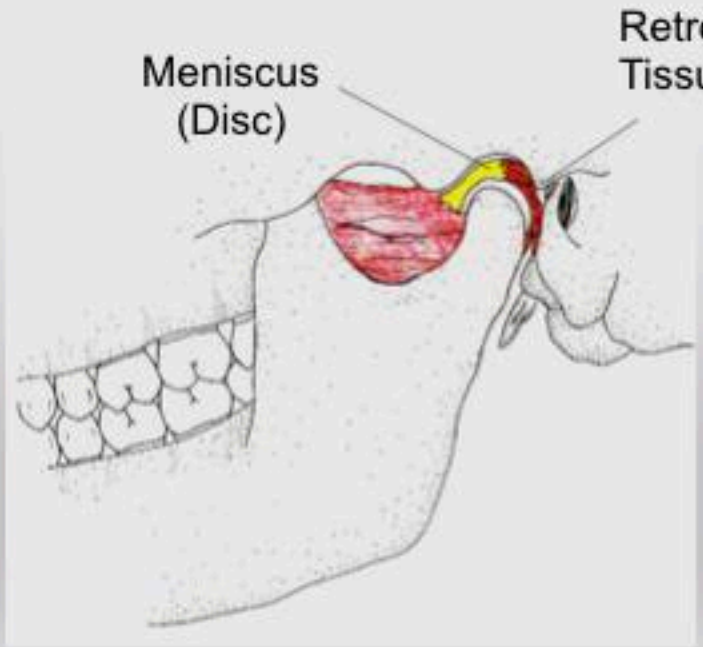

Oblique Sagittal View

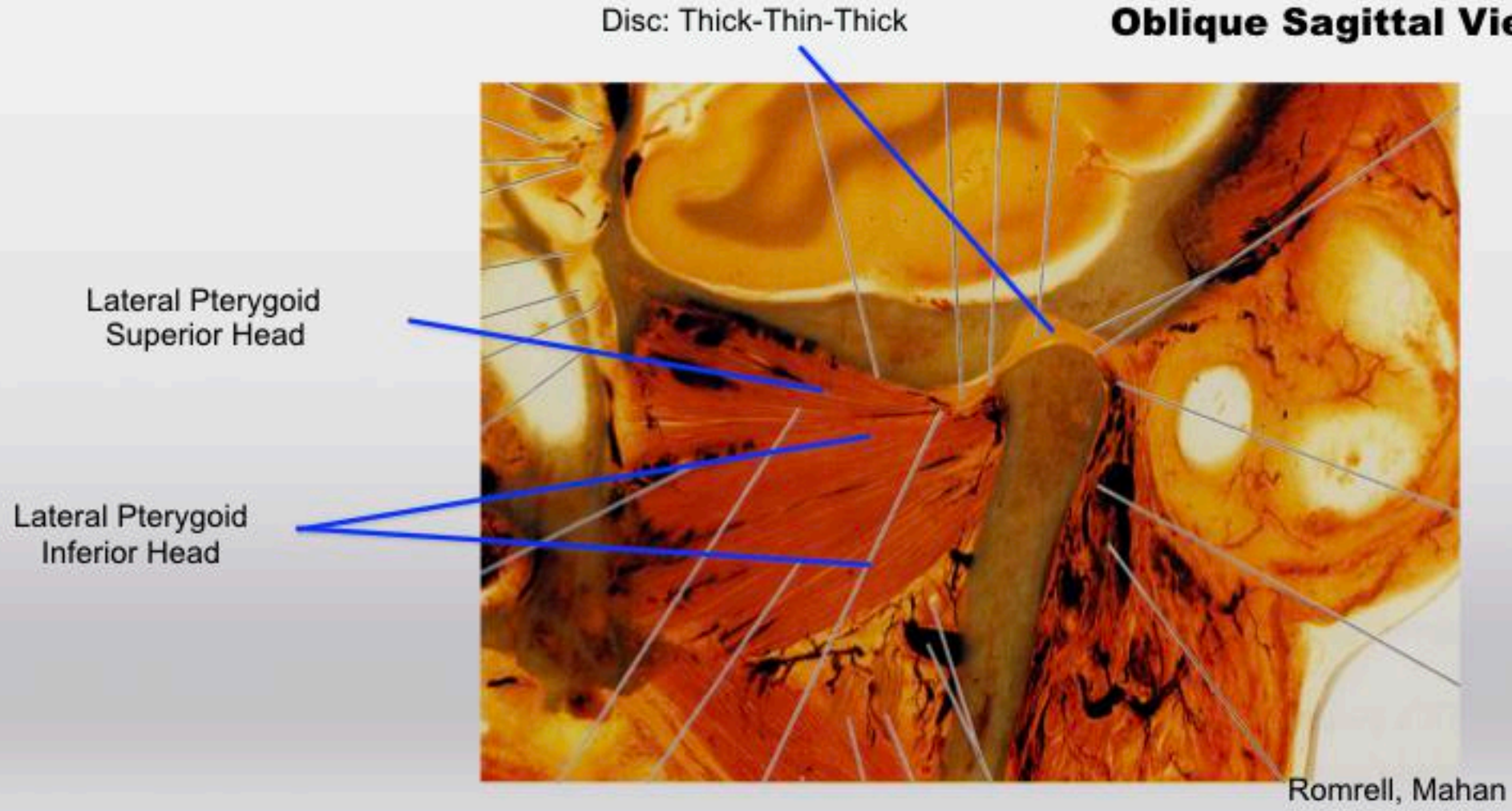

Axial View

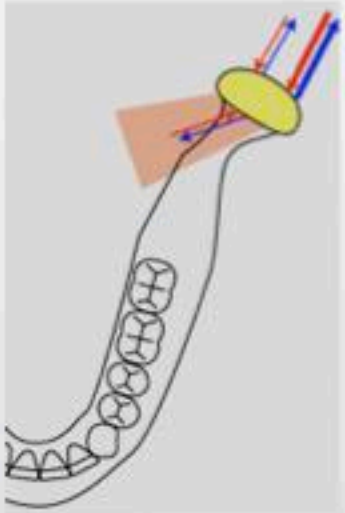

Normal TMJ Blood Flow, Marrow

Condylar head limited collateral circulation

Epiphyseal growth center

Marrow is fatty tissue with blood vessels, containing the precursor for blood cells

No Blood vessel inside joint

Closed Sagittal

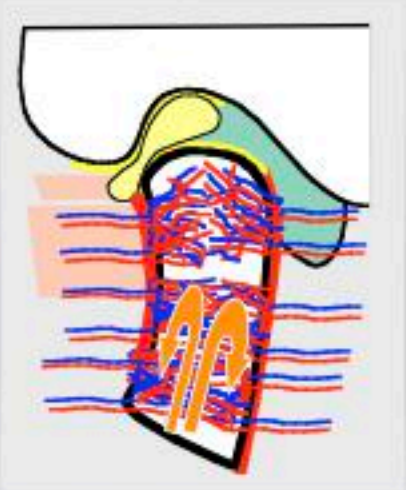

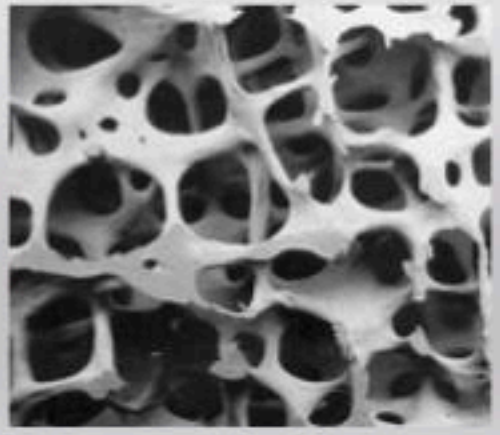

Normal TMJ- Synovium, Cartilage

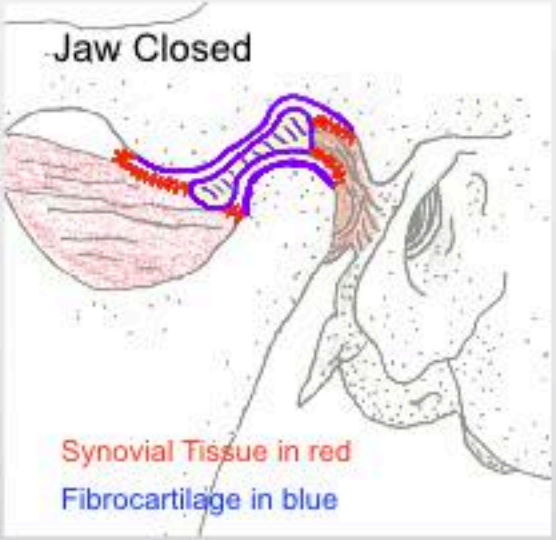

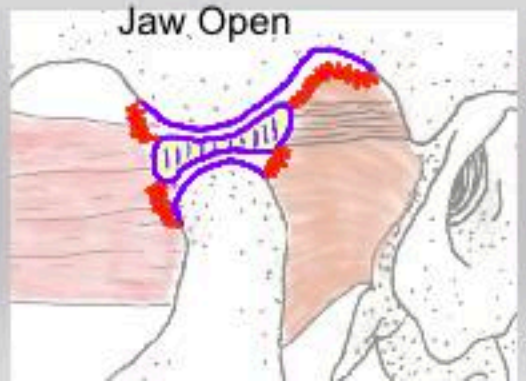

Fibrocartilage-
- Slope of Eminence
- Disc
- Top of Condyle

Synovial Tissue makes Synovial Fluid
- No blood vessels in a health joint
- Nutrition to the cartilage cells
- Lubrication- Hyaluronic Acid and Lubricin

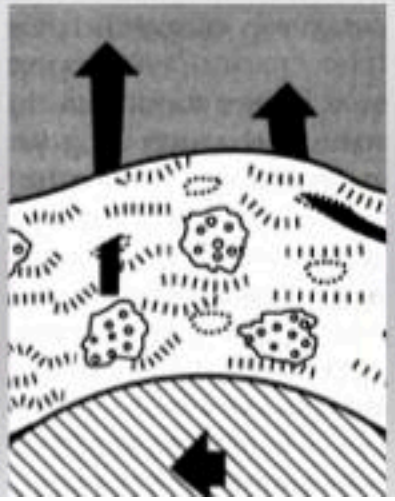

Fibrocartilage surface covered in fluid
- Cartilage is hydrophilic
- Proteoglycan negative charge
- Surface Active Phospholipids
- Fluid slides against fluid
- 5x slipperier than ice

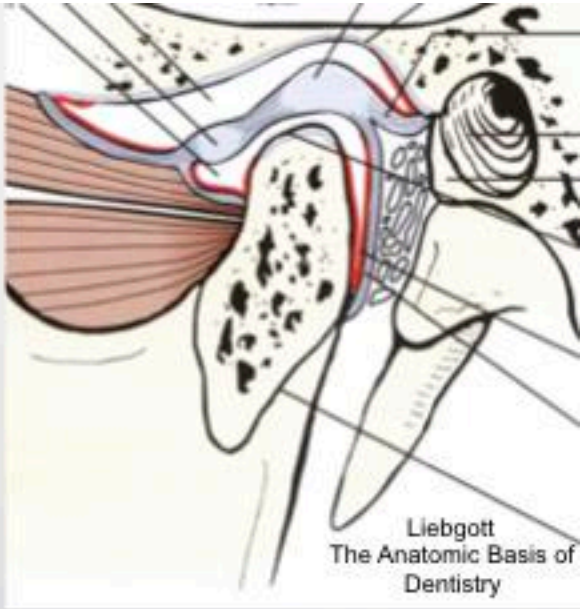

Left TMJ Sagittal View

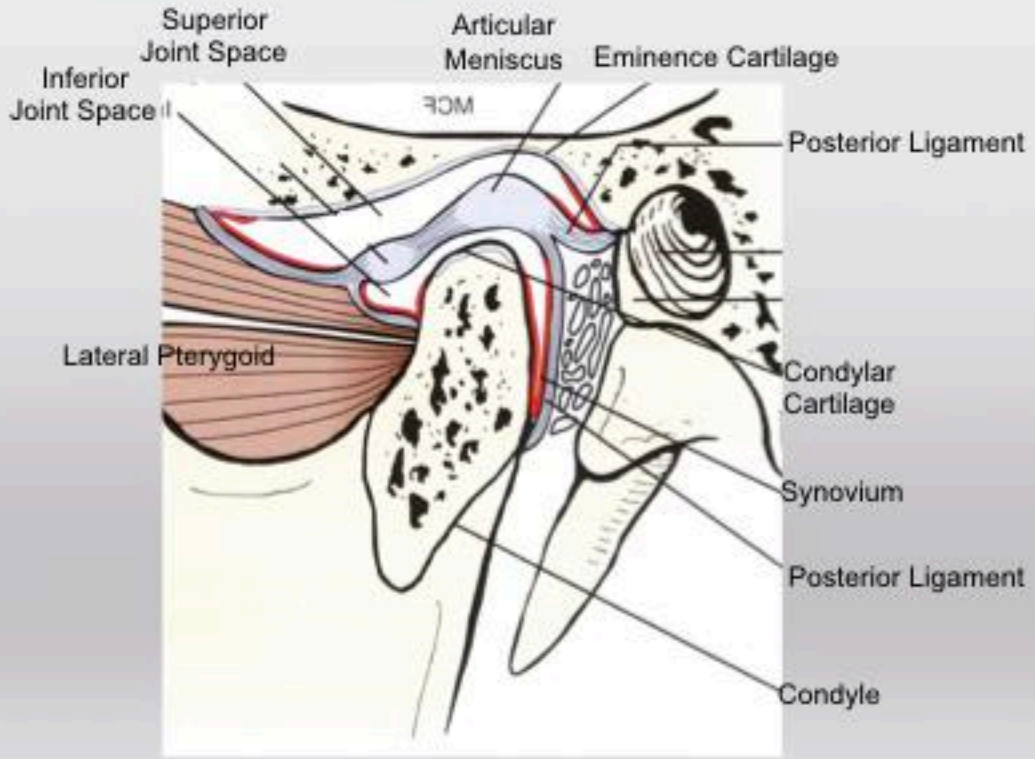

Left TMJ Coronal View

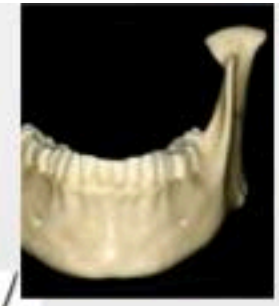

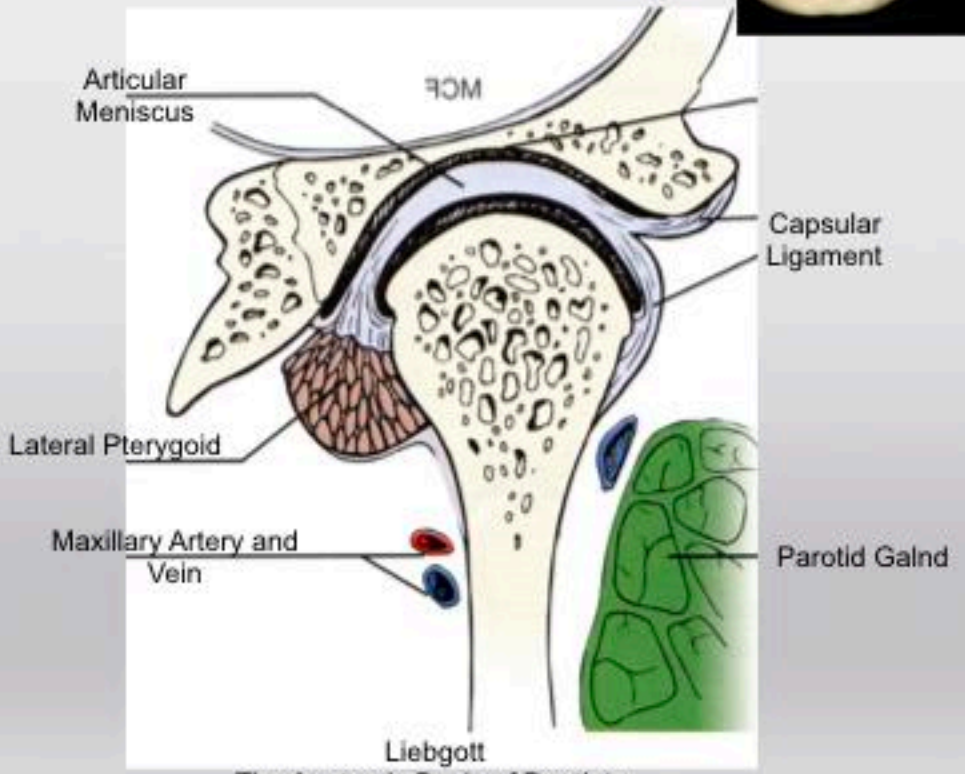

Liebgott
The Anatomic Basis of Dentistry

Normal TMJ

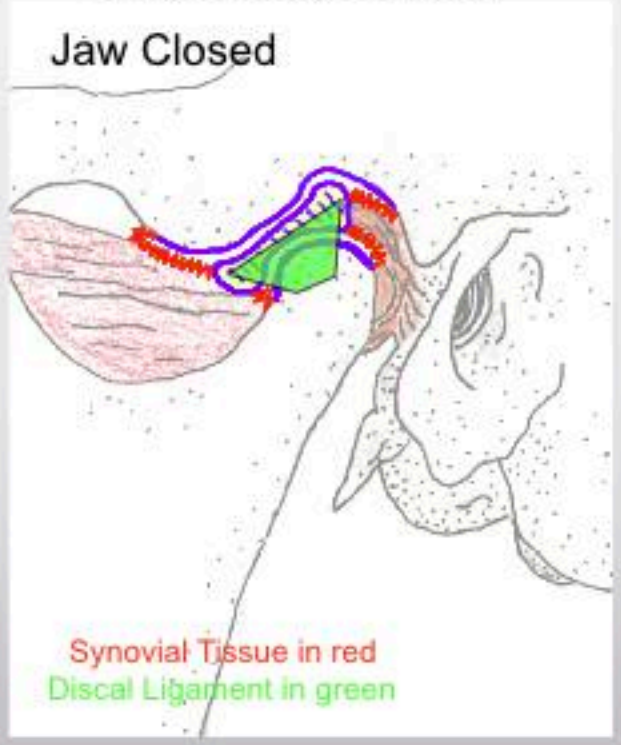

Discal Ligaments attach Disc to Condyle

Synovial Tissue
- Covers Front , Back and Sides
- Collapsed due to negative joint pressure

Disc viewed from above

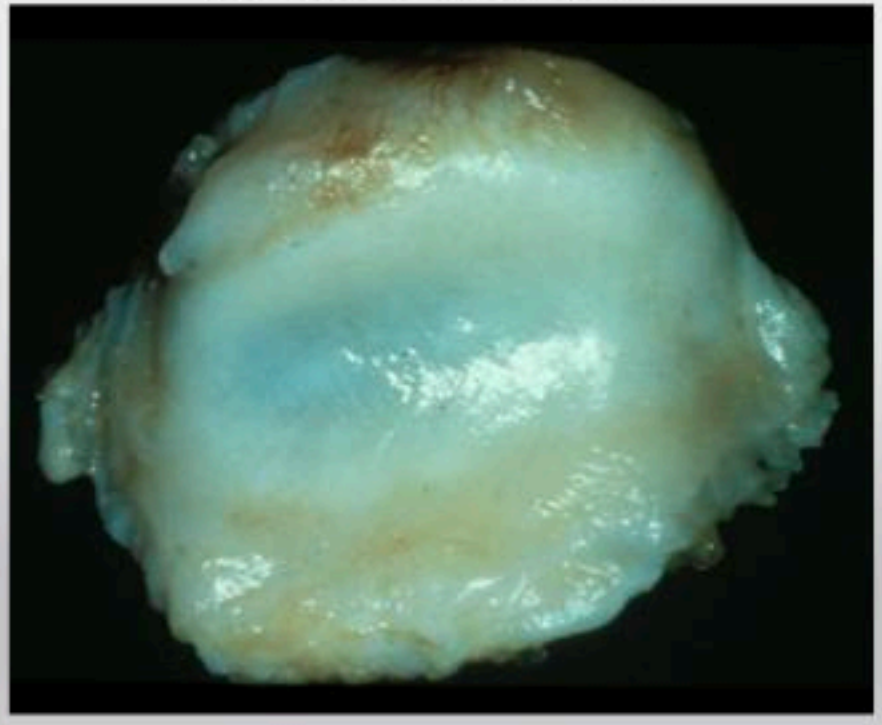

Photo Courtesy of Dr Henry Gremillion

Damaged TMJ- Anteriorly Dislocated Disc

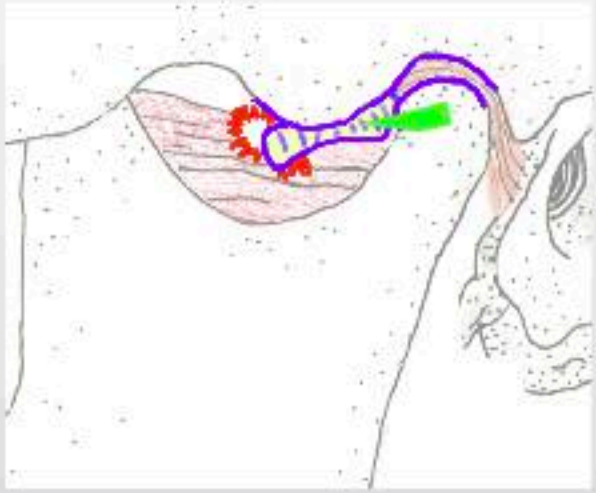

Torn or stretched Meniscal ligaments

Anterior Dislocated Disc

Damaged Synovium

Retrodiscal Tissue pulled up and over the condyle
- Retrodiscal tissue in direct contact with fibrocartilage
- Major Increase in friction
- Retrodiscal tissue adapts into fibrous "pseudodisc"

85% of all damaged joints adapt favorably without treatment

Cartilage sliding on tissue creates vibrations that can be detected

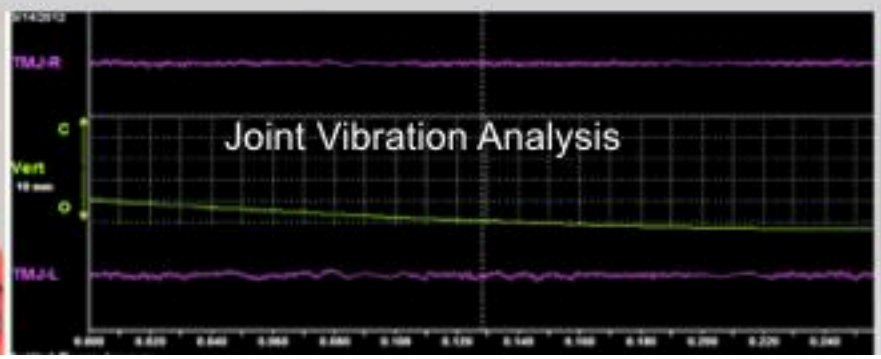

Pseudodisc

MRI
Right
PDD

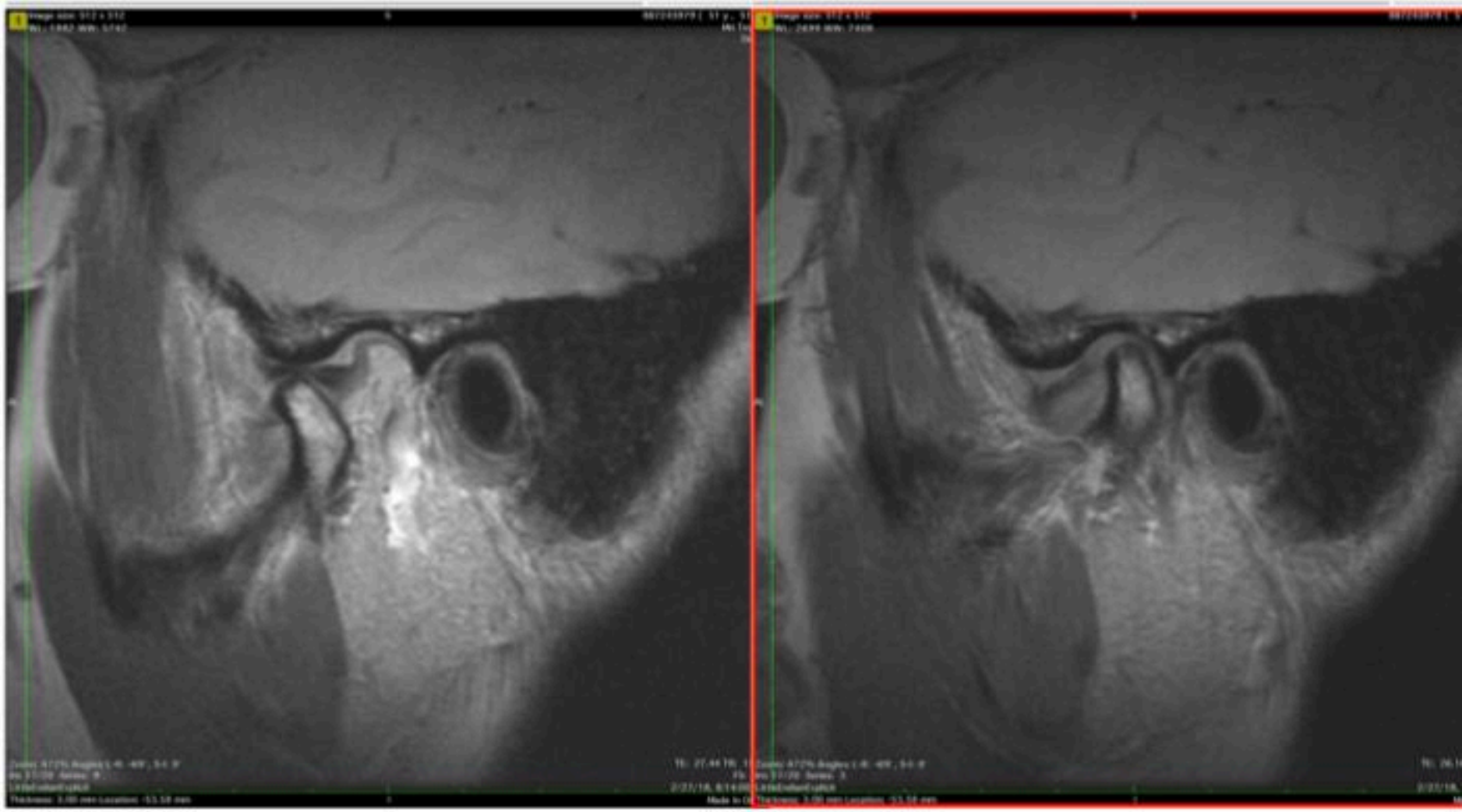

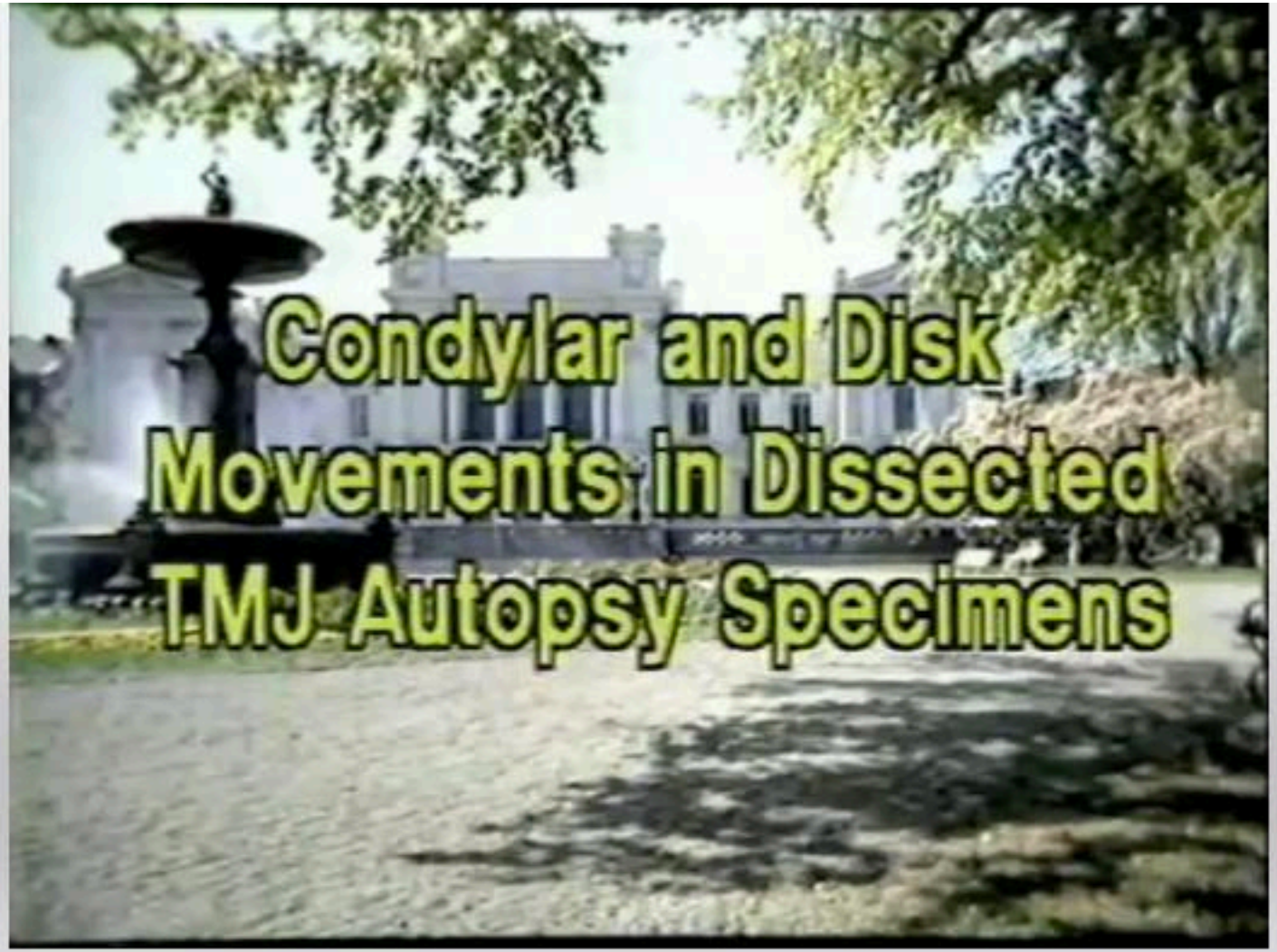
Condylar and Disk
Movements in Dissected
TMJ Autopsy Specimens

Dr. Mark Piper's Classification

Left TMJ

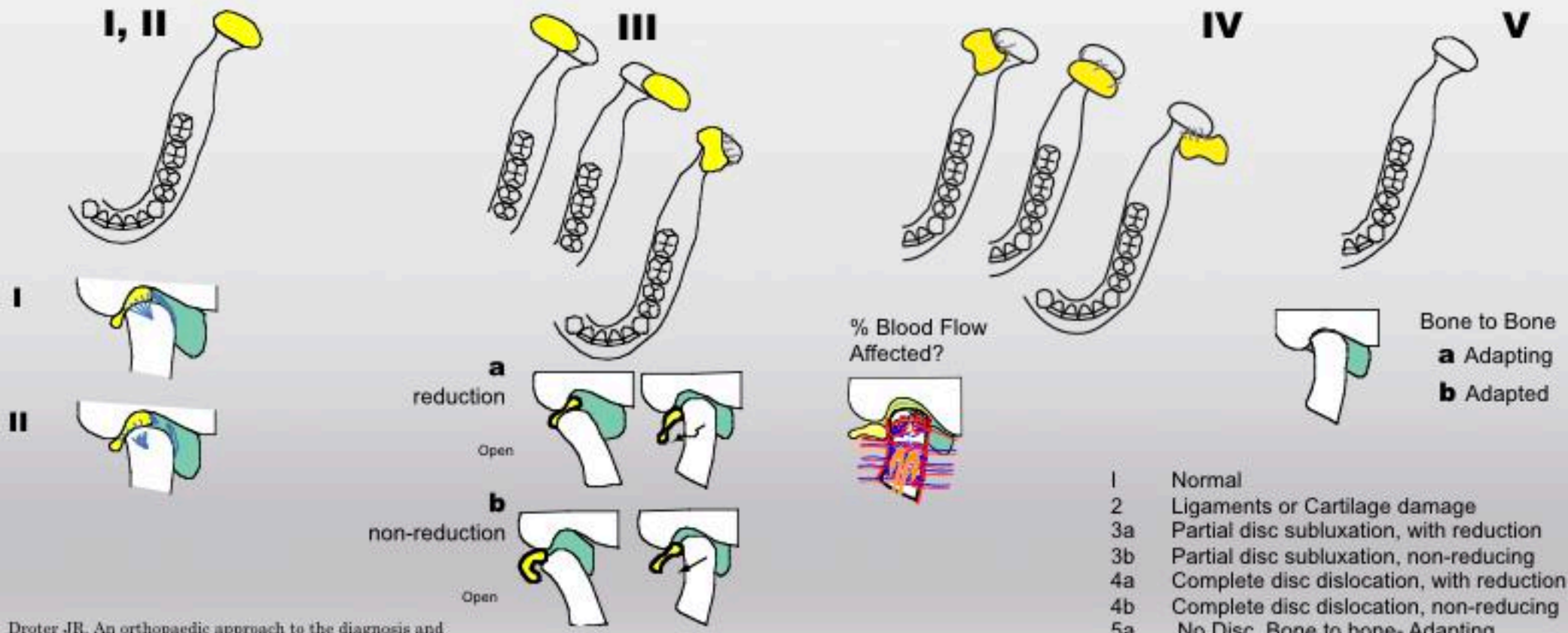

I	Normal
2	Ligaments or Cartilage damage
3a	Partial disc subluxation, with reduction
3b	Partial disc subluxation, non-reducing
4a	Complete disc dislocation, with reduction
4b	Complete disc dislocation, non-reducing
5a	No Disc, Bone to bone- Adapting
5b	No Disc, Bone to bone- Adapted

Droter JR, An orthopaedic approach to the diagnosis and treatment of disorders of the temporomandibular joint. Dent Today 2005 Nov;24(11):82, 84-8

Left TMJ
Normal Disc postion
Thick posterior band sits on top of condyle

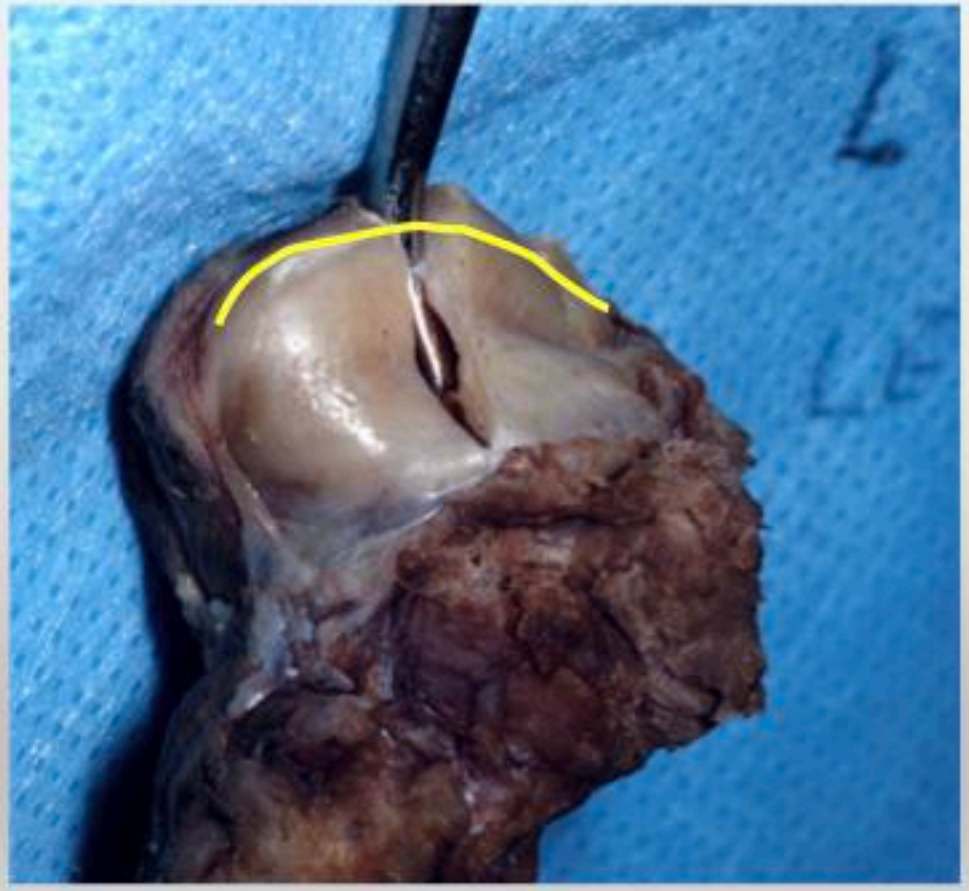

Lateral

www.anomalousmedical.com

Show 4a, 3a

Phone: (727) 823-3220
Anomalous Medical
111 2nd Ave NE Suite 1006
St. Petersburg, FL 33702

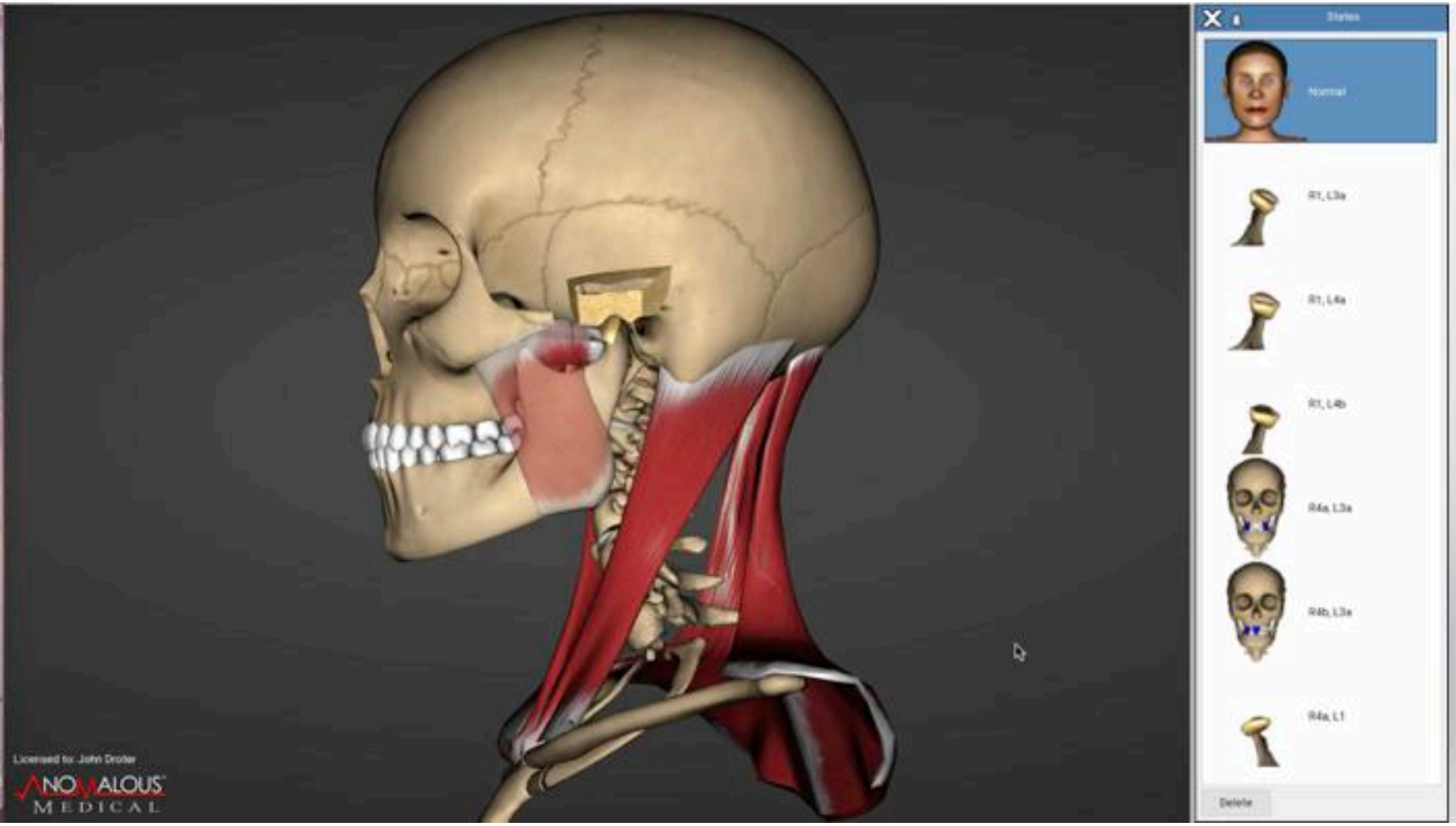

Skull Anatomy 4a

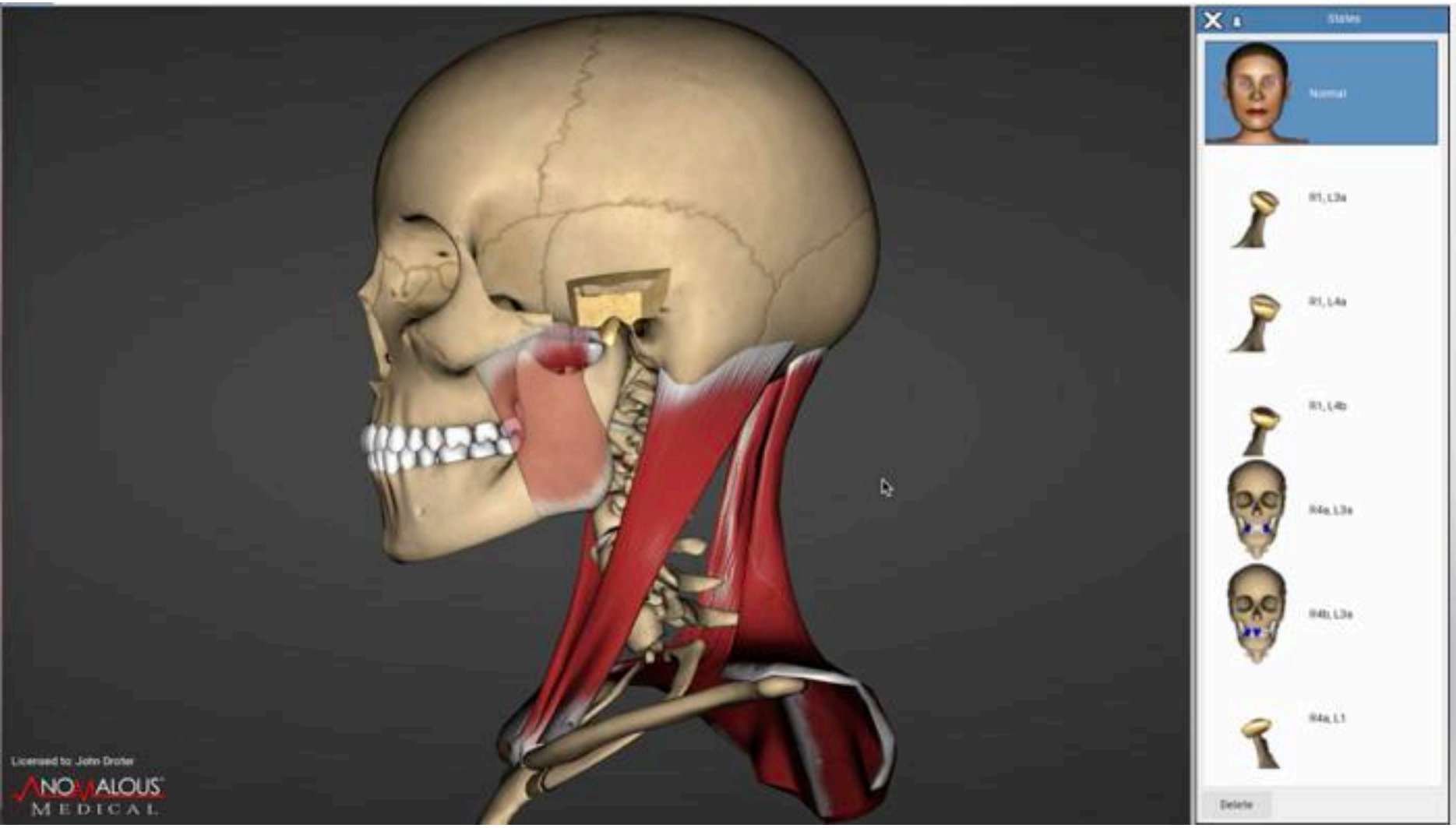
States
Normal
R1, L3a
R1, L4a
R1, L4b
R4a, L3a
R4b, L3a
R4a, L1
Delete
Licensed to: John Droter
ANOMALOUS
MEDICAL

4a, 3a

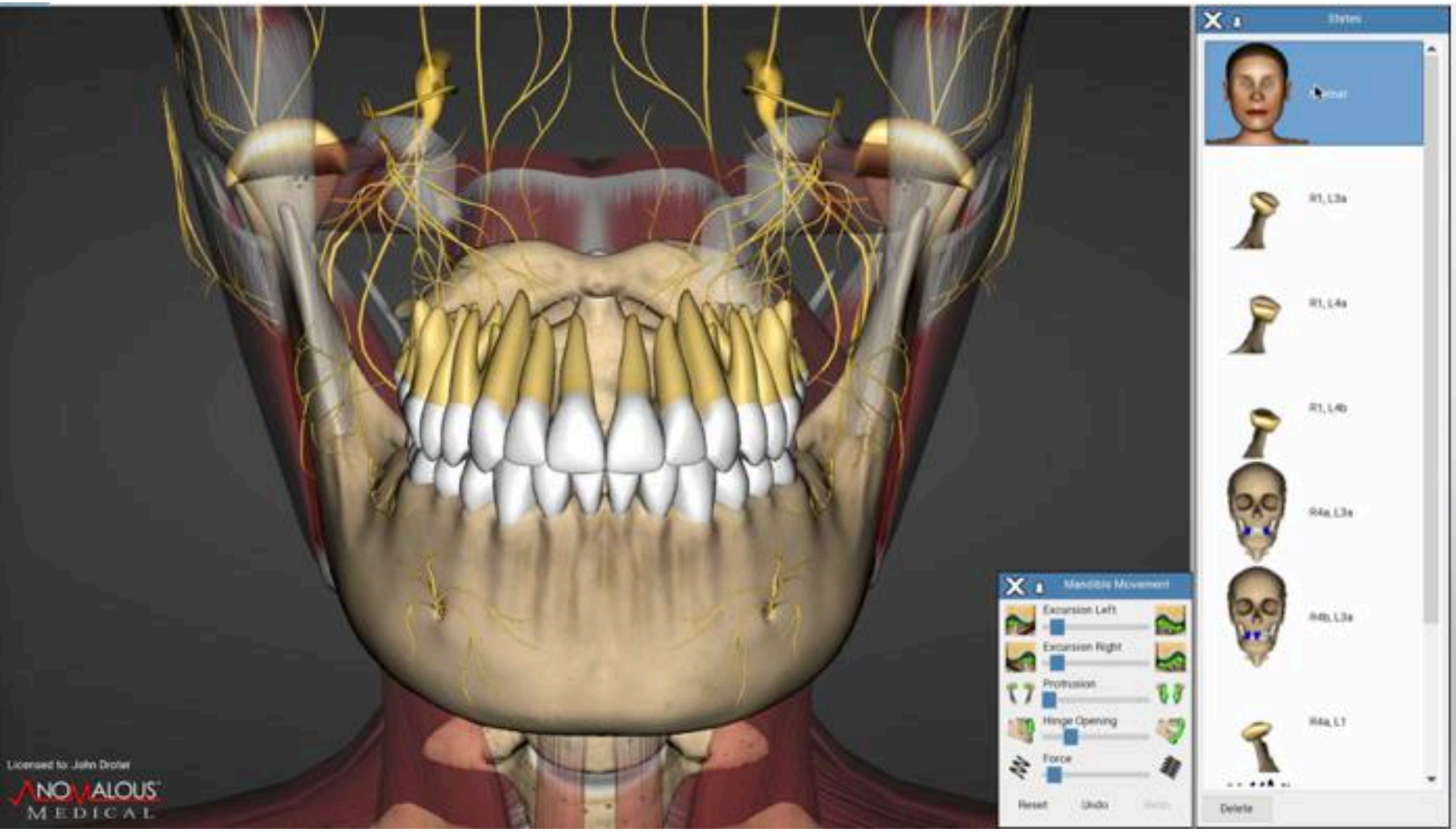

Occlusal Shift

Differential Diagnosis of TMJ Clicking

Normal

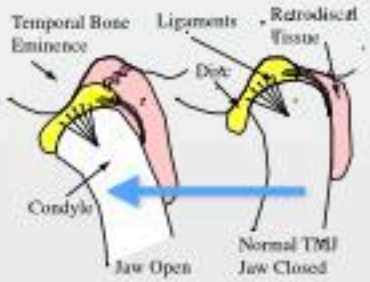

Disc Reduction

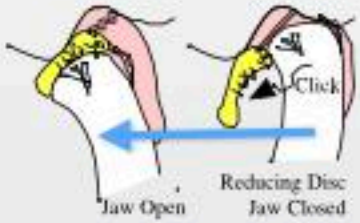

Adhesive Click

"Sticky Disc" - Disc sticks after prolonged clenching, then releases

Eminence Thud

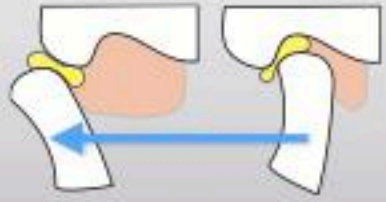

A hypermobile condyle moves past the crest of the eminence and makes a thud sound

3a Condyle Distalized, Disc is in proper location, Lateral pole click on translation

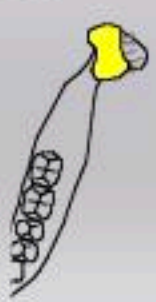

Adhesion Crackle

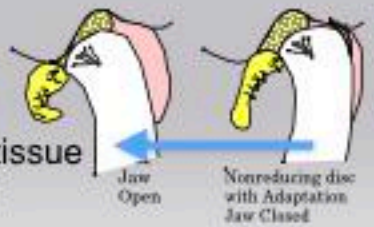

A small piece of fibrous tissue 4b joint is moved across

Basic Orthopedics

Joints are either
- Healthy or
- Damaged

If damaged, joints will be either:
- Actively Breaking Down
- Adapting
- Adaptive Compensation
  - Structurally, Mechanically
  - Favorably, Unfavorably

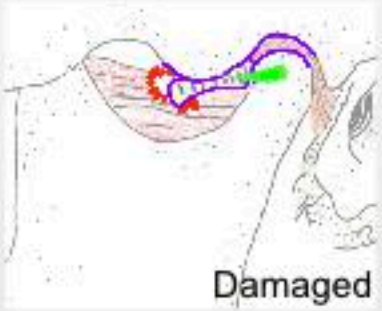

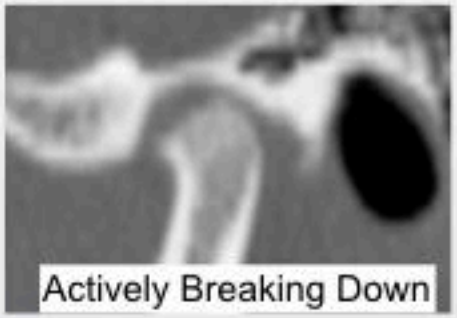

Majority of damaged TMJs adapt favorably

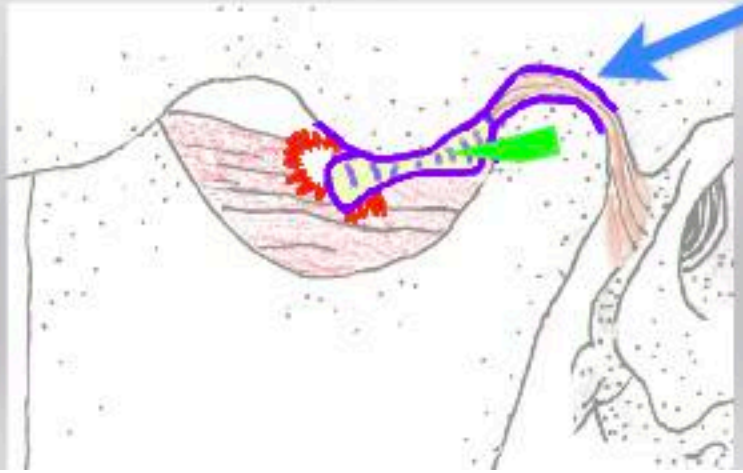

Posterior ligament, synovium, and retrodiscal tissue adapt to form a

Pseudo-disc

Tissue Fibrosis

What is the Clinical Relevance of TMJ Damage Pre-Puberty?

John R Droter DDS
Annapolis, Maryland

TMJ Damage Prepuberty

4b Pre-puberty is not a degenerative process

Can affect growth

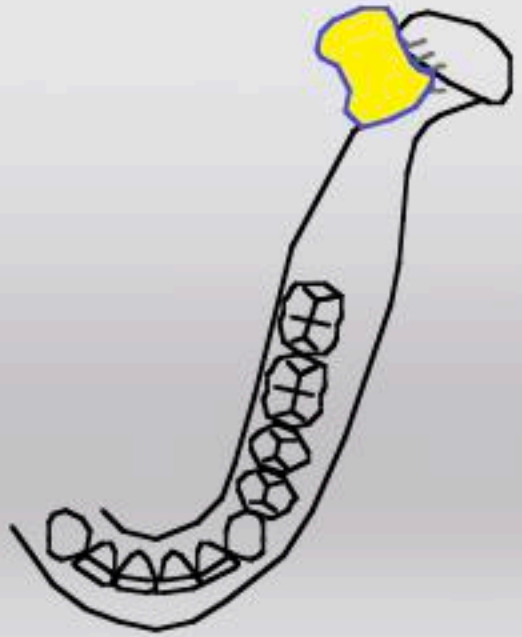

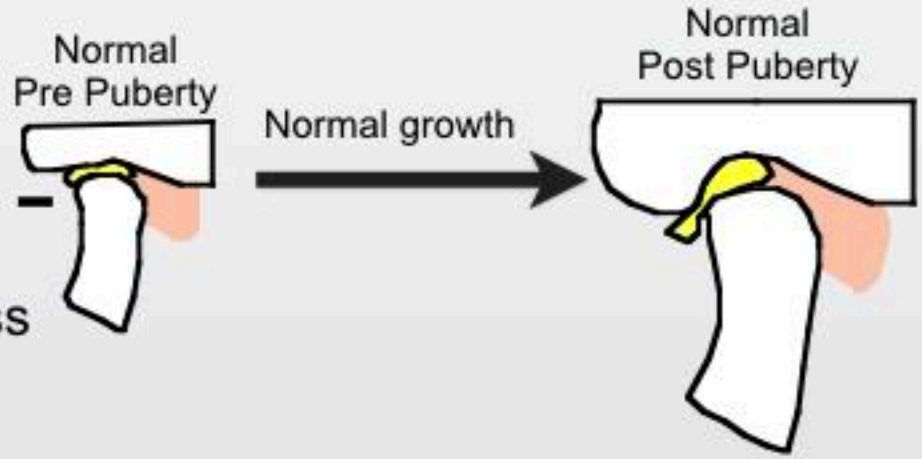

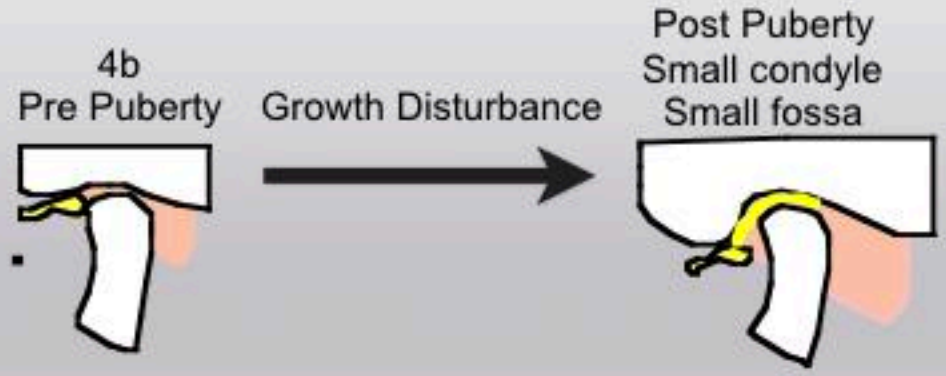

Age 17





R TMJ

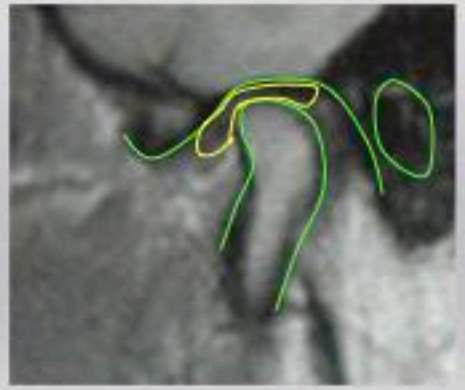

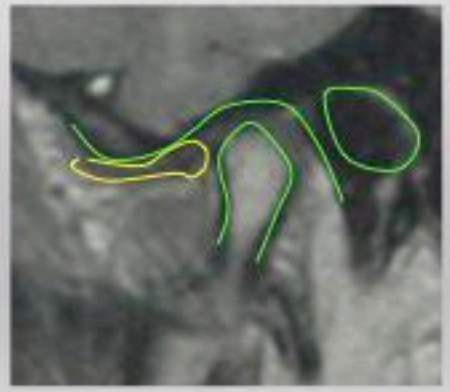

L TMJ

Identical Twin Sister Age 17

Pt of Ed Zebovitz, DDS

Şakar, O., Çalişir, F. (2013). Evaluation of the Effects of Temporomandibular Joint Disc Displacement and Its Progression on Dentocraniofacial Morphology in Symptomatic Patients Using Posteroanterior Cephalometric Analysis. Cranio, 31(1), 23–31.

TMJ Damage Prepuberty

Prevalence Displaced Discs

Asymptomatic Volunteers

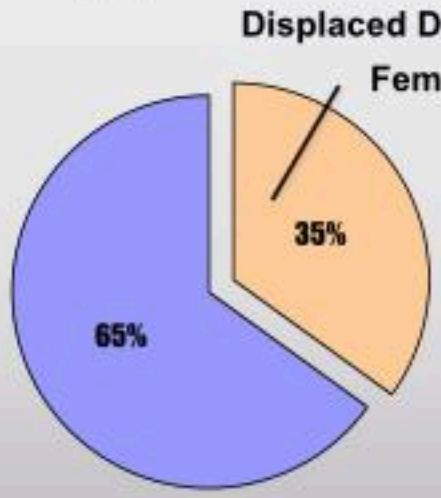

Presenting to Ortho Office

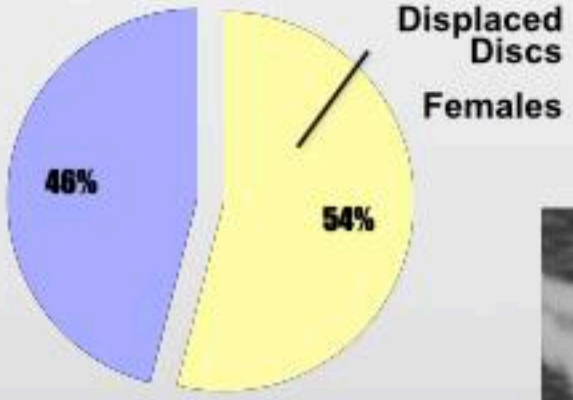

In patients with Displaced Discs
Condyles of Females Distalized
Significantly more than Males

The Prevalence of Disc Displacement in Symptomatic and Asymptomatic Volunteers
Ribeiro R, Tallents R, Katzberg R, J Oral Facial Pain 1997 ;11:37-47

Osseous Morphology and Spatial Relationships of the TMJ Comparisons of Normal and Anterior Disc Positions, Kinniburgh R, Major P, Nebbe B, Angle Orthod 2000;70:70-80

Basic Orthopedics

Joints are either
- Healthy or
- Damaged

If damaged, joints will be either:
- Actively Breaking Down
- Adapting
- Adapted Favorably Structurally and Mechanically
- Adapted Unfavorably

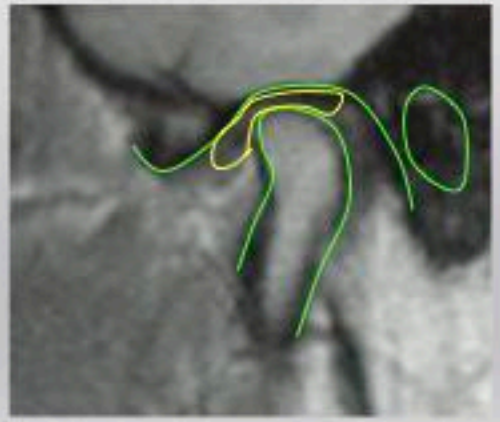

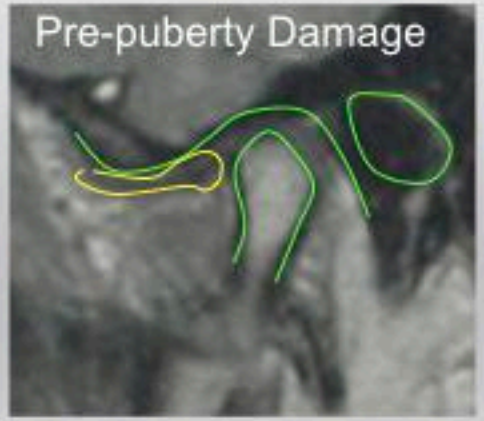

Small condyles due to TMJ damage:

Pre-puberty TMJ damage, the joints adapted, but did not grow.

Post-puberty TMJ damage will be a degenerative process.

Note ratio condyle size to fossa size

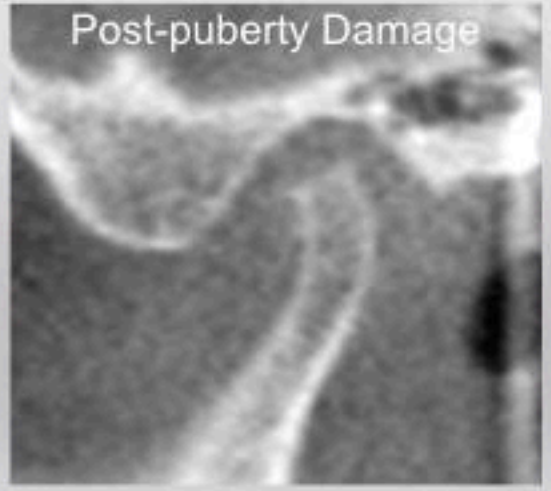

What is the Clinical Relevance of TMJ Damage Post-Puberty?

John R Droter DDS
Annapolis, Maryland

Basic Orthopedics

Joints are either
- Healthy or
- Damaged

If damaged, joints will be either:
- Actively Breaking Down
- Adapting
- Adaptive Compensation
  - Structurally, Mechanically
  - Favorably, Unfavorably

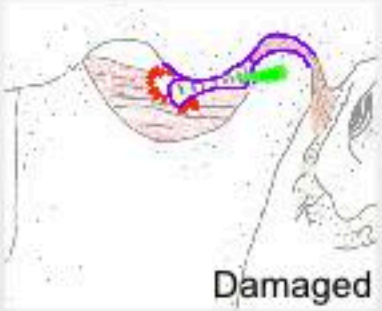

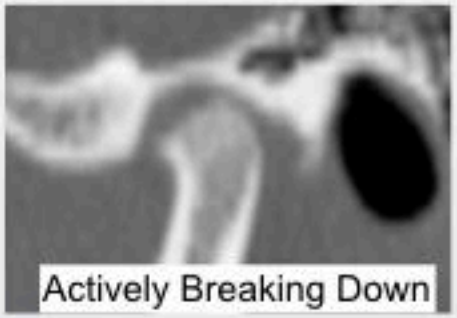

Majority of damaged TMJs adapt favorably

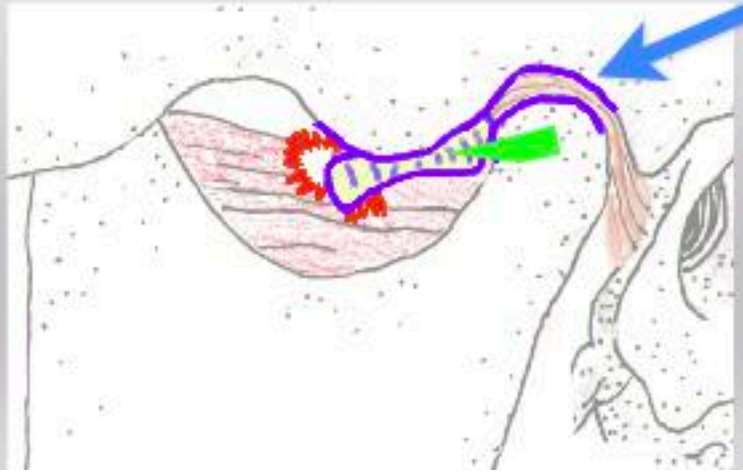

Posterior ligament, synovium, and retrodiscal tissue adapt to form a

Pseudo-disc

Tissue Fibrosis

Symptoms of Temporomandibular Joint Osteoarthrosis and Internal Derangement 30 years after Non-Surgical Treatment.

Leeuw, Boering, Stegenga, Bont,
Journal of Craniomandibular Practice, April 1995, vol. 13, No. 2

- University Hospital, Netherlands: 134 TMD patients, 30 year follow up
- Patients received good clinical work up and diagnosis 30 years ago, but basically no treatment
  - (Reassurance, PT, exercise, limited occlusal adjust)
- 70% satisfied with results
- 25% still had pain on movement
- 15% not able to eat hard foods
- 35 control patients had no apparent symptoms

If you have a disease that is one in a thousand, it is 100% for you

There is no love sincerer than the love of food.

G. B. Shaw



Damaged TMJs

Adapt Favorably	**85%**
Adapt Fairly	**14%**
Adapt Poorly	**<1%**

→ Occlusal Muscle Dysfunction
Osteoarthritis

→ Avascular Necrosis
Progressive Condylar Resorption

*These are my guesses on %, no research to back up to backup

Normal Joint with Normal Occlusion

All teeth touch evenly with condyles seated in fossa

What happens to the occlusion if
the disc is dislocated?

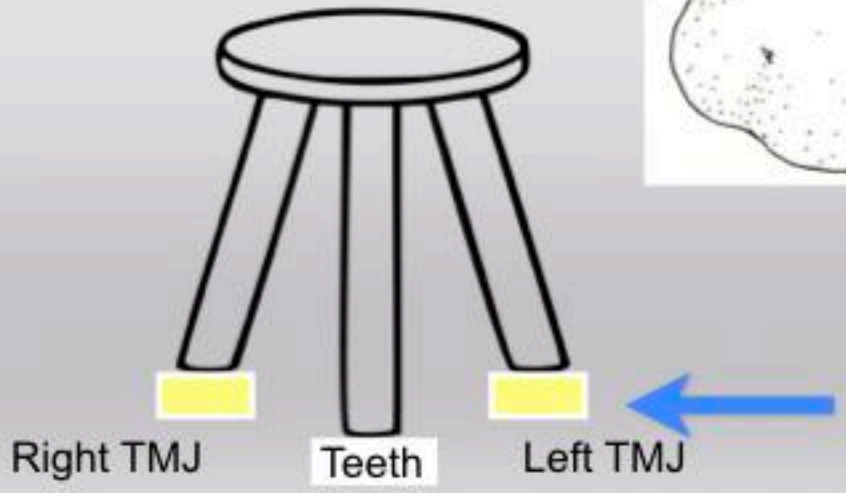

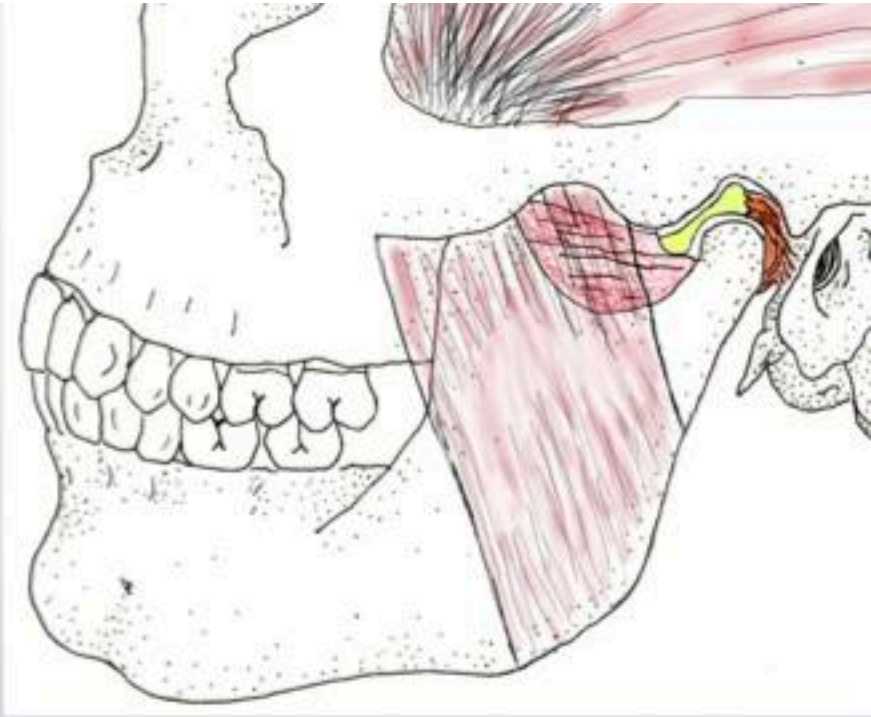

Normal Joint with Normal Occlusion

All teeth touch evenly with condyles seated in fossa

What happens to the occlusion if
the disc is dislocated?

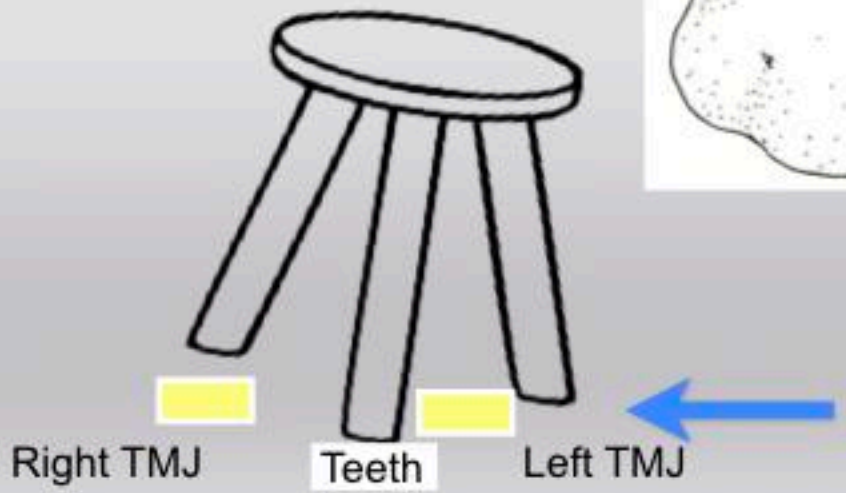

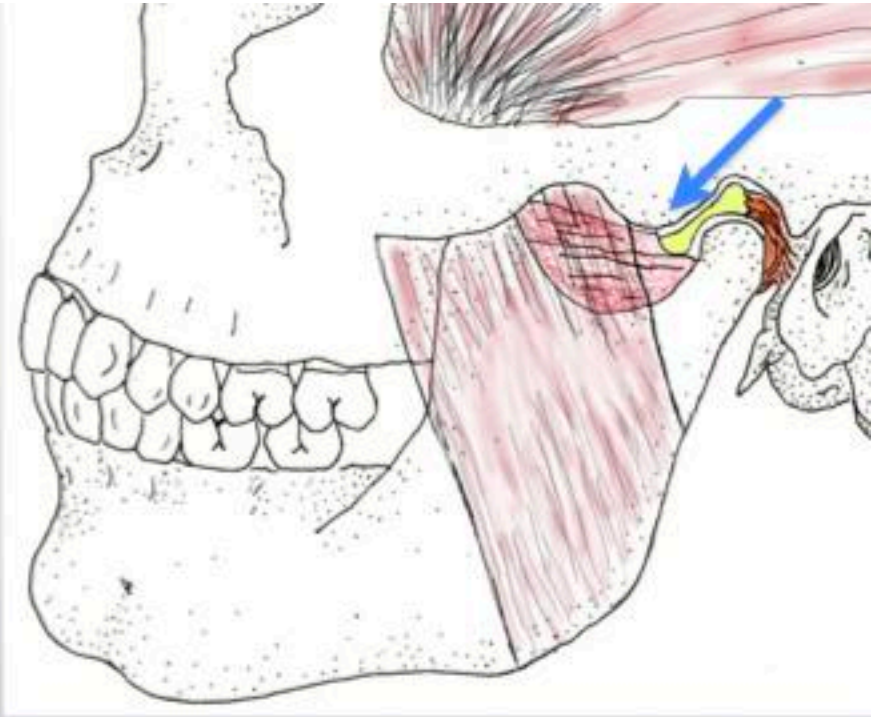

Damaged Joint with Malocclusion

All teeth touch evenly with condyles seated in fossa

What happens to the occlusion if
the disc is dislocated?

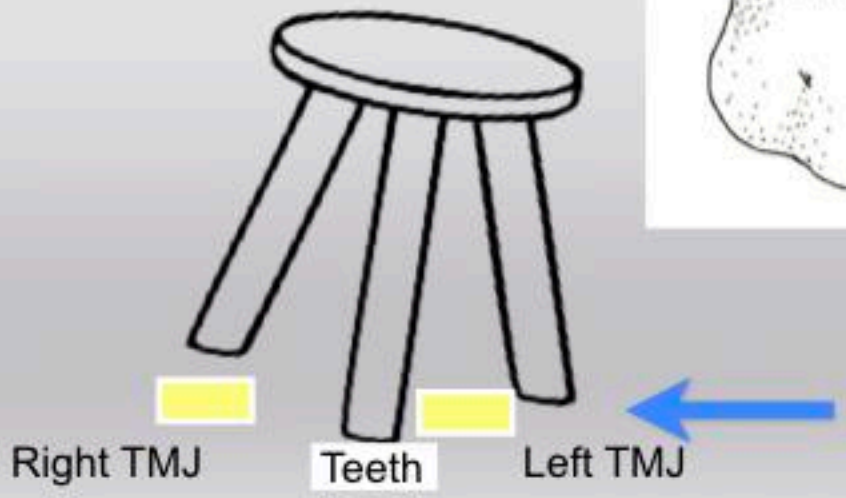

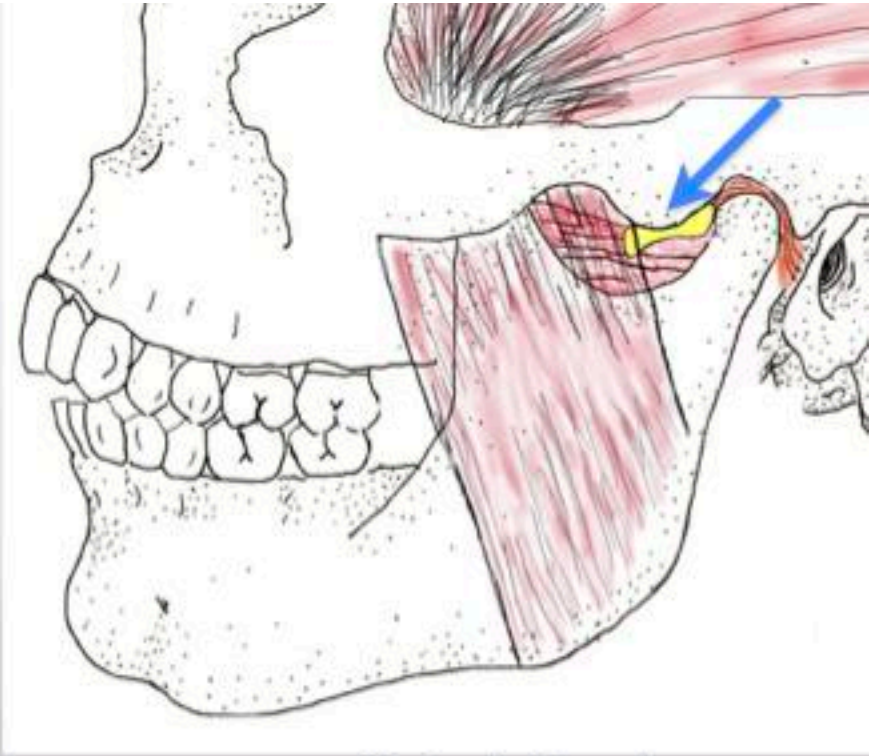

Contact of most
posterior tooth

Damaged Joint with Malocclusion

85% damaged joints adapt favorably with respect to the TMJ.

Anteriorly Dislocated Disc, Mandible shifts: Inadequate Anterior Guidance
Uneven Occlusion,
CR≠MaxIC
Occlusal Muscle Disharmony develops.

Treat adaptive compensation joints with OMD the same as healthy joints with OMD:
Occlusal Adjustment

CR≠MaxIC should be 2mm or less.
(Anterior Posterior 2mm)
If >2mm something else is going on.

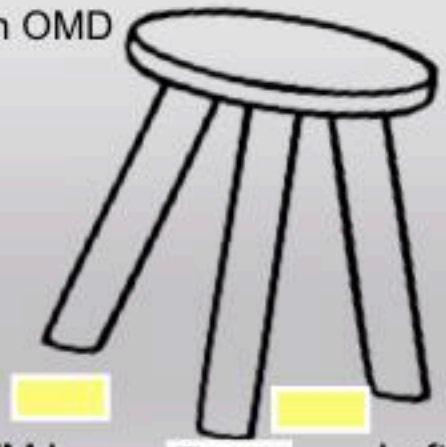

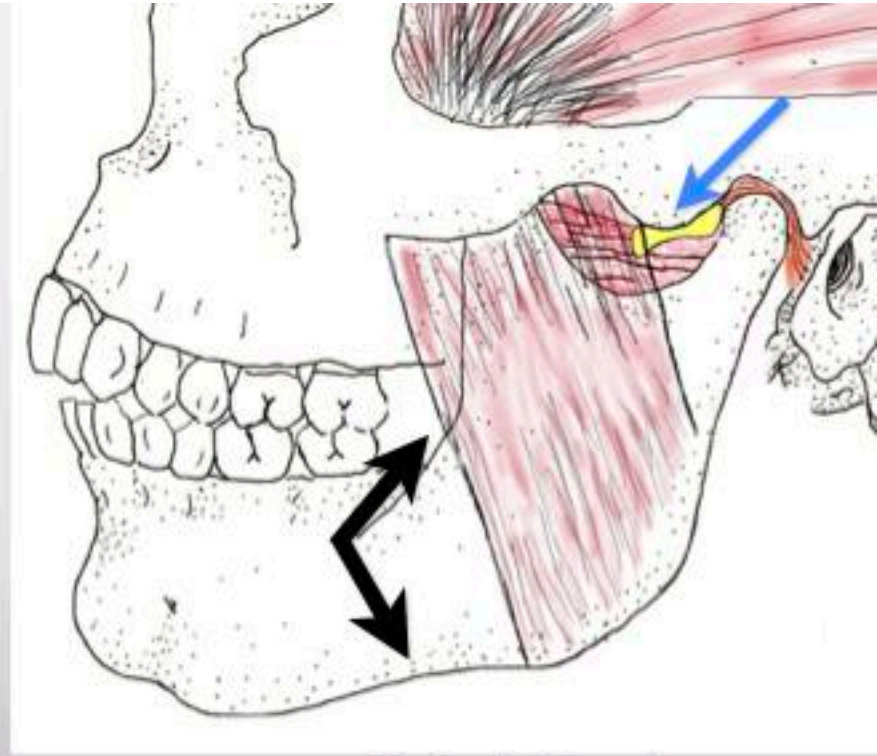

Contact of most posterior tooth

TMDs- What are the choices? (190 Diagnoses, 7 Categories)

1. TMJ Damage

Disc Dislocation

Crystal arthropathy, unspecified, TMJ
Dislocation jaw cartilage due to injury, Sequela
Dislocation jaw cartilage with reduction, favorable adaptation, TMJ
Dislocation jaw cartilage without reduction, favorable adaptation, TMJ
Effusion, TMJ

Impingement Retrodiscal Tissue
Tissue Bone Resorption, TMJ Condyle
(Joint Mice), TMJ
oplasm of bones of skull and face
M.J. Recaming
TMJ, active degeneration
a- Inactive
is Diseases TMJ
andibular Condyle, Active
Perforation Meniscus, TMJ
Perforation Pseudodisc, TMJ
Psoriatic Arthritis TMJ
Rheumatoid Arthritis Sero Negative TMJ

2. Muscles of the TMJ

Occlusal Muscle Disharmony

Muscle Bracing TMJ stabilization
Muscle Bracing Airway **Patentcy** (with Tongue)
Muscle Contracture Fibrosis Lateral Pterygoid
Muscle Contracture Fibrosis Masseter, Medial Pterygoid, Temporalis
Muscle Fatigue Overuse
Muscle Hypertrophy TMJ Muscles

3. Cranial Alignment/Occlusion

Mandible shifts: Inadequate Anterior Guidance
Uneven Occlusion, CR≠MaxIC

Malocclusion Posterior Openbite Bilateral
Malocclusion Posterior Openbite Unilateral
Malocclusion unspecified

Tooth Supereruption

4. Cervical Damage

Cervical Vertebrae Alignment Dysfunction
Cervicocranial Syndrome
Muscle Guarding due Neck Instability
Trigger Point Neck Muscle with Referred Pain
Trigger Point Neck Muscle, Localized Pain

5. Parafunction

Excessive Tooth Wear, Damage
Hypersensitive Occlusion
Parafunction clech/grind wiggle
Parafunctional Clenching Teeth, Awake
Parafunctional Clenching Teeth, Sleep
Parafunctional Grinding Teeth, Awake
Parafunctional Grinding Teeth, Sleep
Parafunctional Tongue Bracing avoiding uncomfortable tooth contact
Parafunctional Tongue Bracing Neck stabilization
Parafunctional Tongue Bracing to maintain Airway
Parafunctional Tongue Bracing unknown cause

6. Whole Body / Systemic

Lyme Disease Arthritis
Magnesium Deficiency
Obstructive Sleep Apnea
Osteoporosis without current pathological fracture
Pathological Habitual Movement Pattern
Postural Disharmony Standing

Otitis Ear Infection
Pain disorder exclusively related to psychological factors. Somatoform pain disorder
Pain disorder with related psychological factors

Stomatognathic System Interrelationship

A change in any one area
will affect the others

"Adaptation"

This is a **dynamic**
orthopedic System

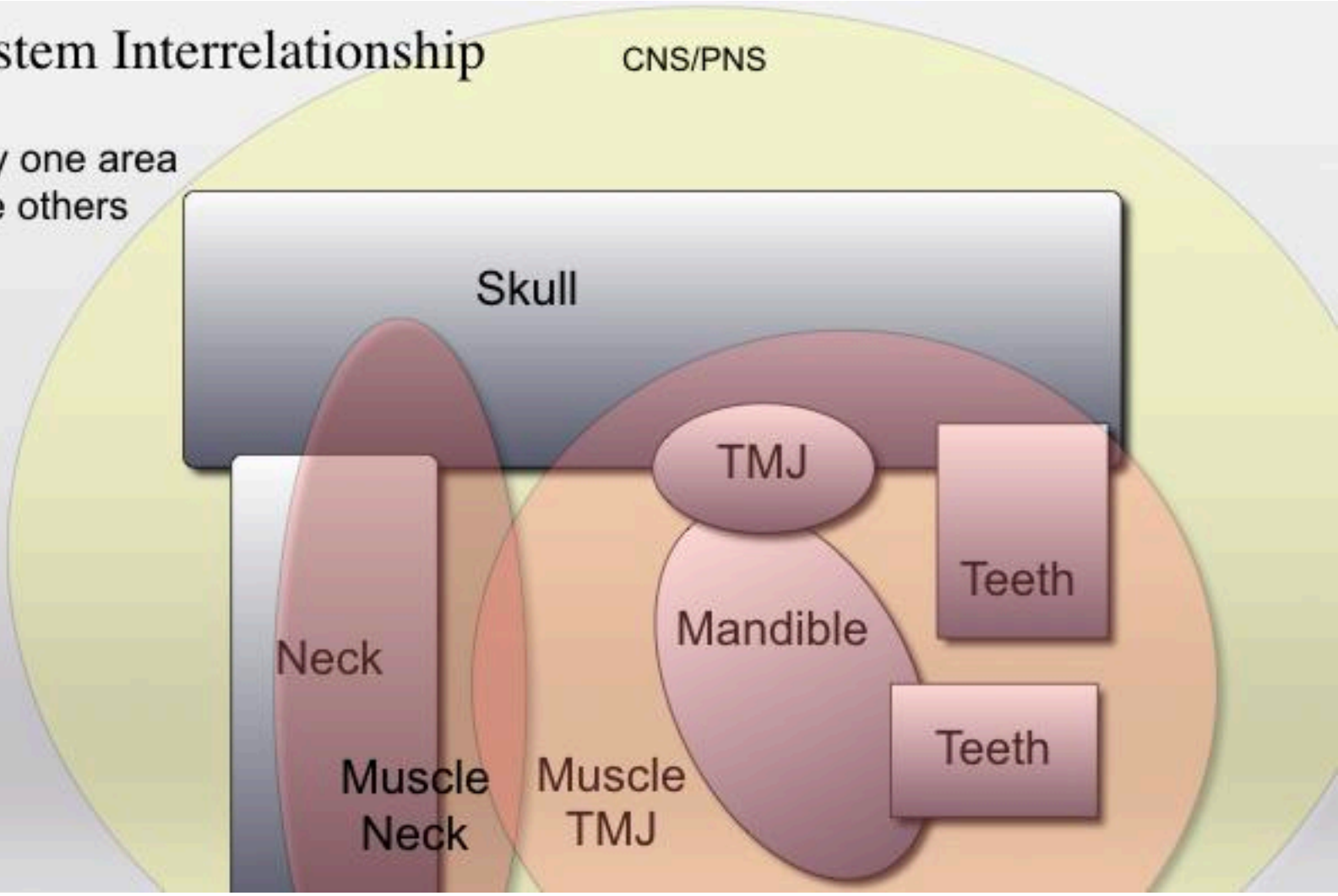

venn diagram

Occlusal Muscle Disharmony

Uneven tooth contact with condyles fully seated triggers muscle activity

Lateral pterygoid fires out of sequence to create even tooth contact on closure

Disharmony in all muscles: Splinting/Bracing

Muscles sore from overuse

Muscles do not think- CNS input

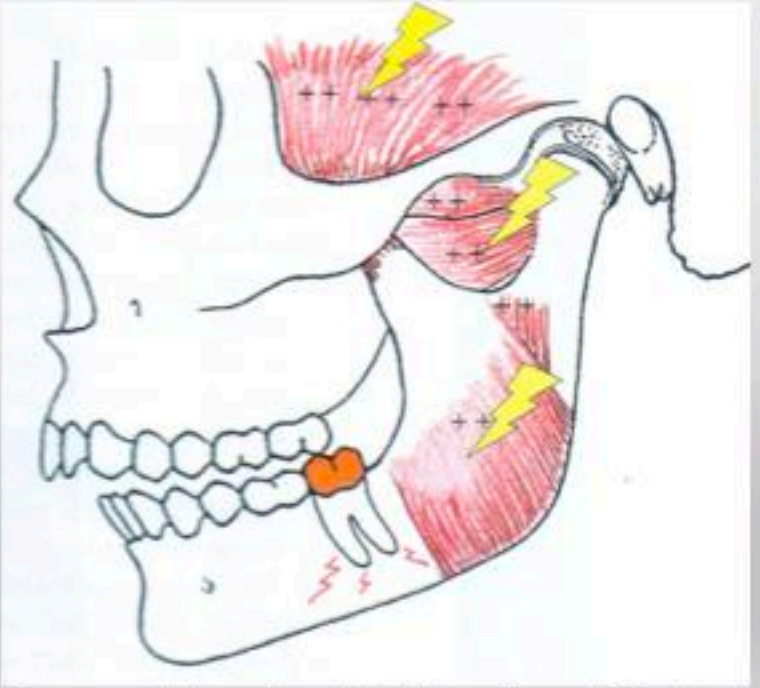

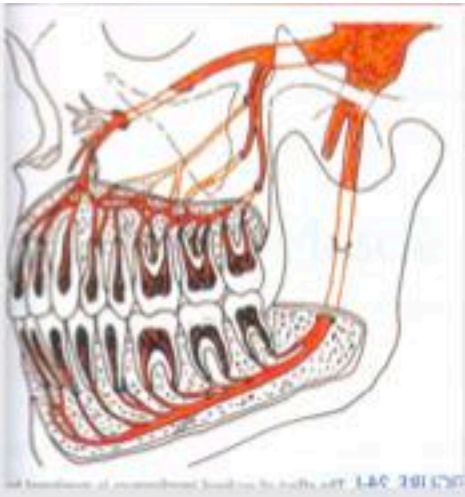

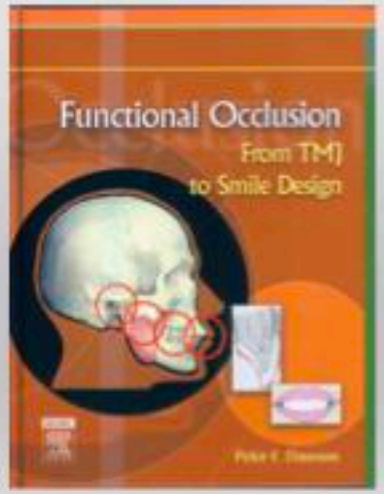

from Dawson's Textbook, "Functional Occlusion"

LD Pankey's 3 Rules of Occlusion

(Clyde Schuyler)

1. With the condyles fully seated in the fossa, all the posterior teeth touch simultaneously and even, with the anterior teeth lightly touching.
2. When you squeeze, neither a tooth nor the mandible moves (in a lateral direction).
3. When you move the mandible in any excursion, no back tooth hits before, harder than, or after a front tooth.

Drawing by Dr Jim Kessler

Bonus Rule- Harmonious Anterior Guidance. Cuspid guidance directs the mandible slightly forward, not backward, with smooth cross over from cuspid to anterior teeth. Protrusive contact even on both central incisors.

Bonus Observation- All the above work much better the closer the teeth are to being on the Curve of Spee and Curve of Wilson

Why LD Never wrote a text book

Slide by Dr John R Droter

2. When you squeeze, neither a tooth nor the mandible moves (in a lateral direction).

Rule #2 = Flat Landing Area

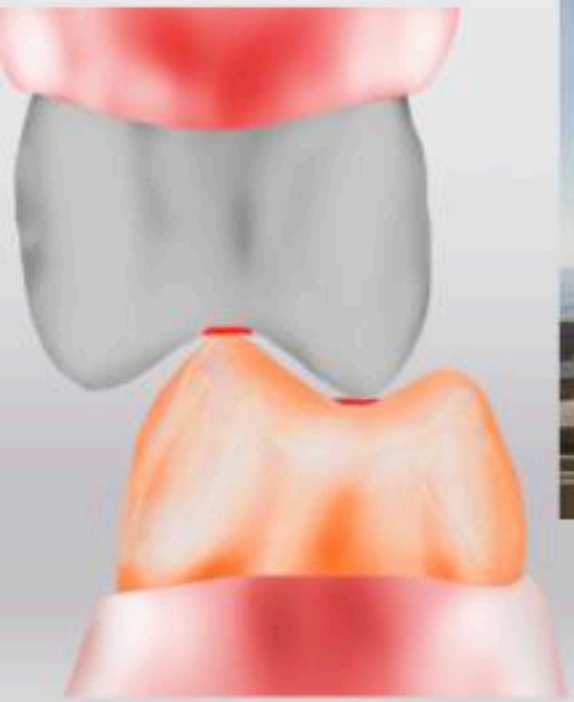

LD Pankey's 3 Rules of Occlusion (Clyde Schuyler)

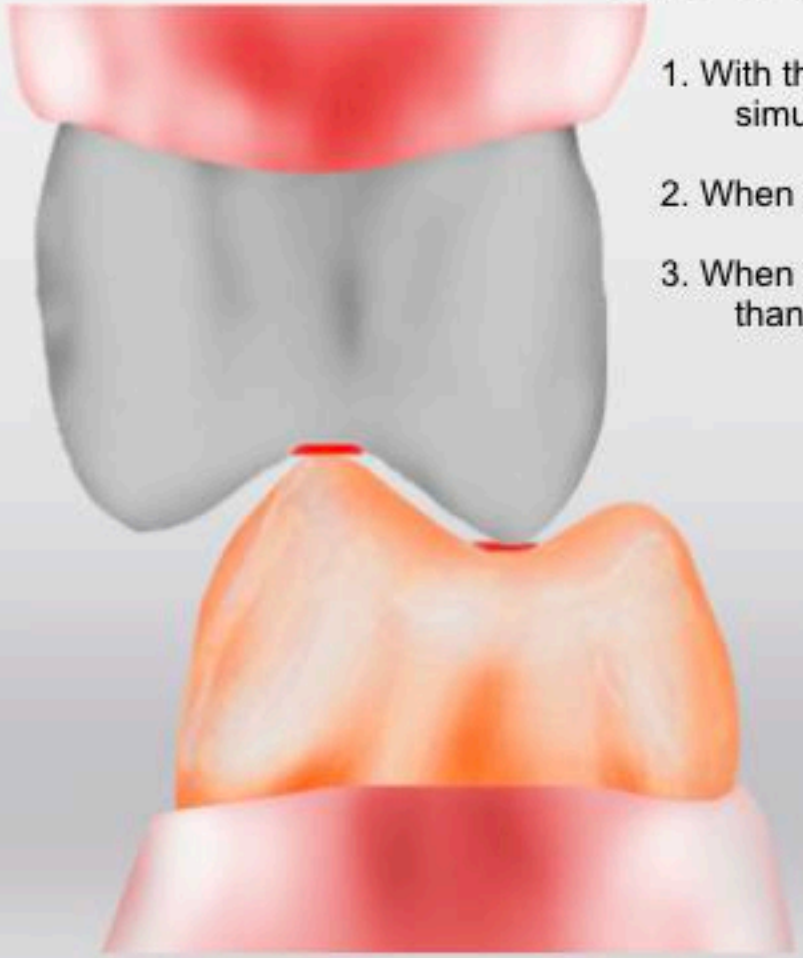

1. With the condyles fully seated in the fossa, all the posterior teeth touch simultaneously and even, with the anterior teeth lightly touching.

2. When you squeeze, neither a tooth nor the mandible moves (in a lateral direction).

3. When you move the mandible in any excursion, no back tooth hits before, harder than, or after a front tooth.

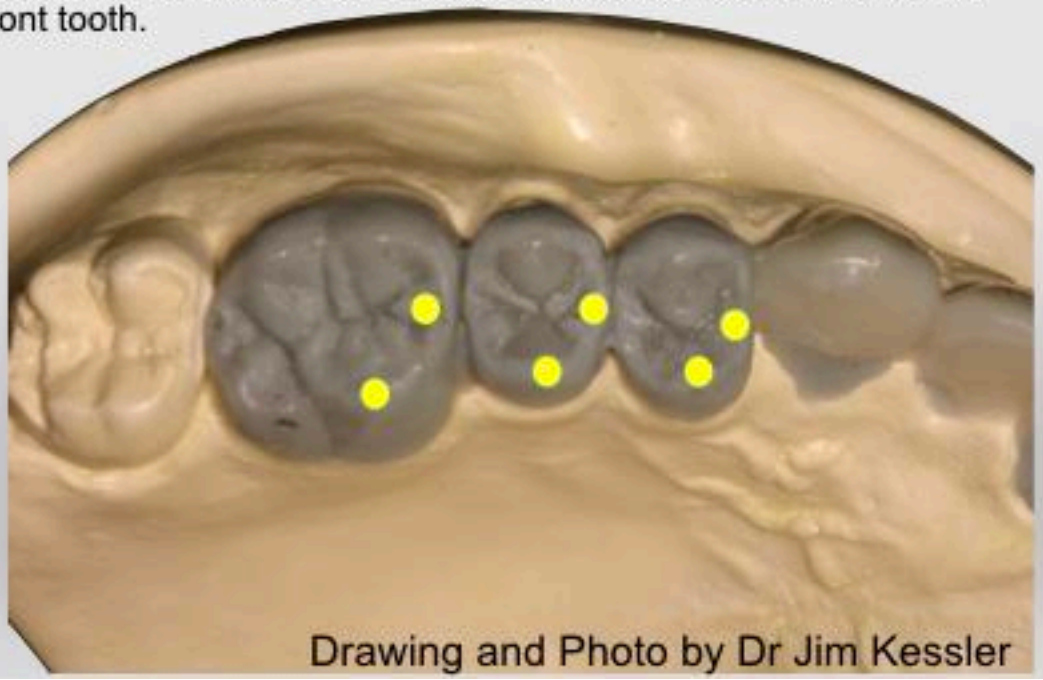

Drawing and Photo by Dr Jim Kessler

LD Pankey's 3 Rules of Occlusion Literature

(Clyde Schuyler)

Schuyler CH. J Florida Dent Soc, 1938.
Occlusal disharmony and its relation to oral discomfort.

Schuyler CH. J Am Dent Assoc. 1958 Aug;57(2):221-31.
Factors of occlusion to be observed in everyday practice.

Schuyler CH. J Pros Dent. 1963 Nov: 13(6): 1011-29.
The function and importance of incisal guidance in oral rehabilitation.

Kerstein, R. B., & Radke, J. (2012). Cranio 30(4), 243–254.
Masseter and temporalis excursive hyperactivity decreased by measured anterior guidance development.

Kerstein, R. B., & Radke, J. (2016). Cranio pp1–17.
Average chewing pattern improvements following Disclusion Time reduction.

Treat Occlusal Muscle Dysfunction- Adjust the Occlusion

Step 1: Trial ideal occlusion on hard orthotic

Step 2: Reshape teeth

Add: Composite
Subtract: Burs

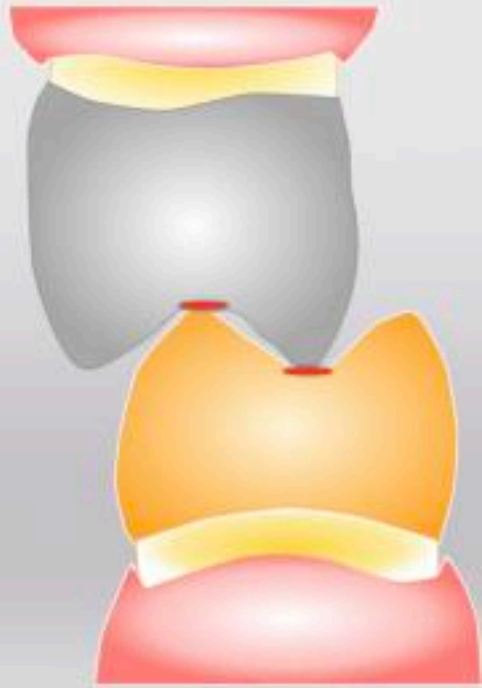

Treat Occlusal Muscle Dysfunction- Adjust the Occlusion

Teeth reshaped so all teeth hit even with condyles seated in fossa. Posterior teeth separate on lateral and anterior excursions.

Before

After

LD Pankey's 3 Rules of Occlusion

(Clyde Schuyler)

1. With the condyles fully seated in the fossa, all the posterior teeth touch simultaneously and even, with the anterior teeth lightly touching.
2. When you squeeze, neither a tooth nor the mandible moves (in a lateral direction).
3. When you move the mandible in any excursion, no back tooth hits before, harder than, or after a front tooth.

Drawing by Dr Jim Kessler

Bonus Rule- Harmonious Anterior Guidance. Cuspid guidance directs the mandible slightly forward, not backward, with smooth cross over from cuspid to anterior teeth. Protrusive contact even on both central incisors.

Bonus Observation- All the above work much better the closer the teeth are to being on the Curve of Spee and Curve of Wilson

Why LD Never wrote a text book

Slide by Dr John R Droter

Diseases that cause bone loss in Joints

Osteoarthrosis/Osteoarthrits
Avascular Necrosis
Hypoxia Induced- Progressive Condylar Resorption

Rheumatoid Arthritis
Infection- Lyme Ds, Syphilis, Staph
Crystalline Deposition Disease
Various other Autoimmune Arthritis
Autoimmune Rheumatic Fever
Cancer

Diseases that cause bone loss in Joints

Osteoarthrosis/Osteoarthrits
Avascular Necrosis
Hypoxia Induced- Progressive Condylar Resorption

Rheumatoid Arthritis
Infection- Lyme Ds, Syphilis, Staph
Crystalline Deposition Disease
Various other Autoimmune Arthritis
Autoimmune Rheumatic Fever
Cancer

Systemic Disease of Synovium
Overgrowth of Synovium into joint space
Pannus- Inflammatory tissue in joint
Cartilage dies lack of synovial fluid flow

Weird = Lyme Disease
Lyme Test has many false negatives

Gout
Uric Acid crystallizes in joint

Psoriatic Arthritis: Look for dry skin patches

Rule cancer out early, rule it out often.
Any sudden onset pain after 50 is suspect

Diseases that cause bone loss in Joints

3 diseases are associated with TMJ disc dislocation

Osteoarthrosis/Osteoarthrits
Avascular Necrosis
Hypoxia Induced- Progressive Condylar Resorption

Rheumatoid Arthritis
Infection- Lyme Ds, Syphilis, Staph
Crystalline Deposition Disease
Various other Autoimmune Arthritis
Autoimmune Rheumatic Fever
Cancer

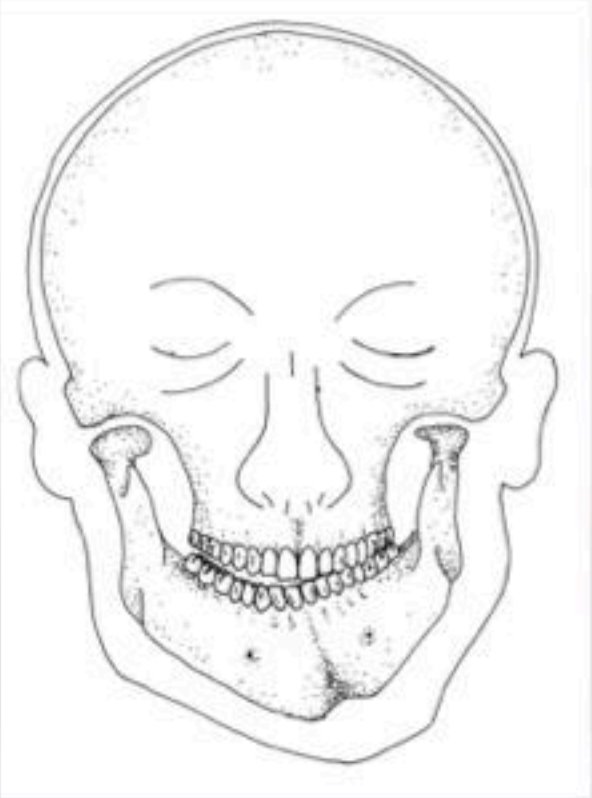

Diseases that cause bone loss in the TMJ alter the Occlusion

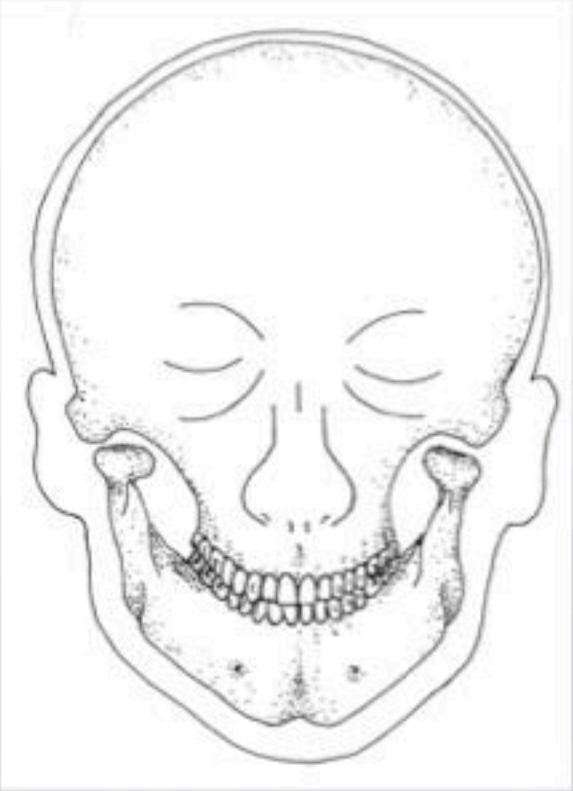

Condylar Bone Loss

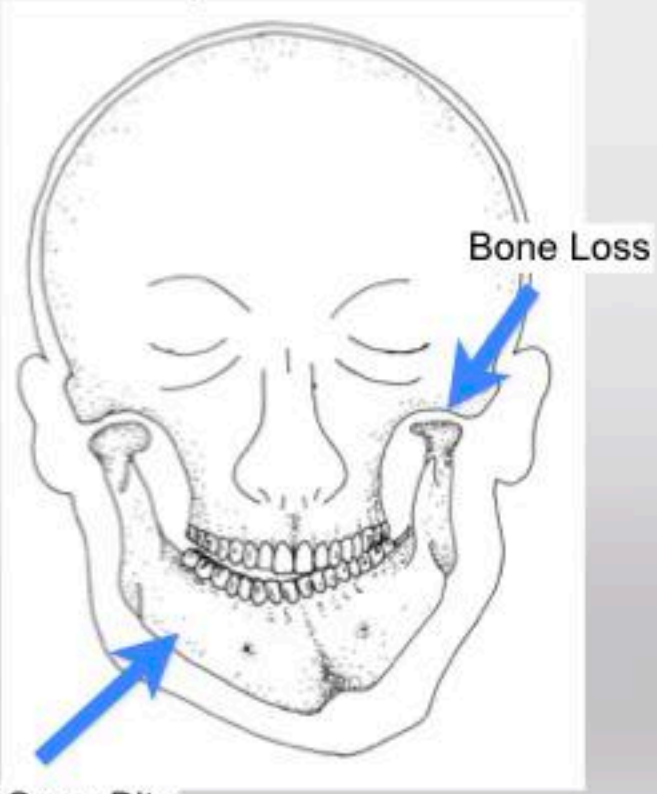

Adaptation Over Time

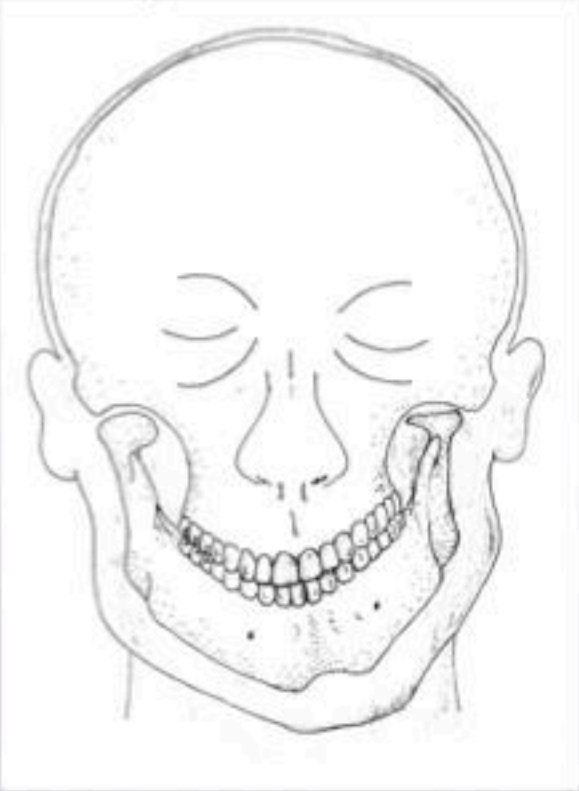

What happens if you lose 2mm joint height in both Right and Left TMJ?

Can lose joint height with bone loss or disc displacement

Minus 2mm TMJ RL joint height

Stomatognathic System Interrelationship

A change in any one area
will affect the others

"Adaptation"

This is a **dynamic**
orthopedic System

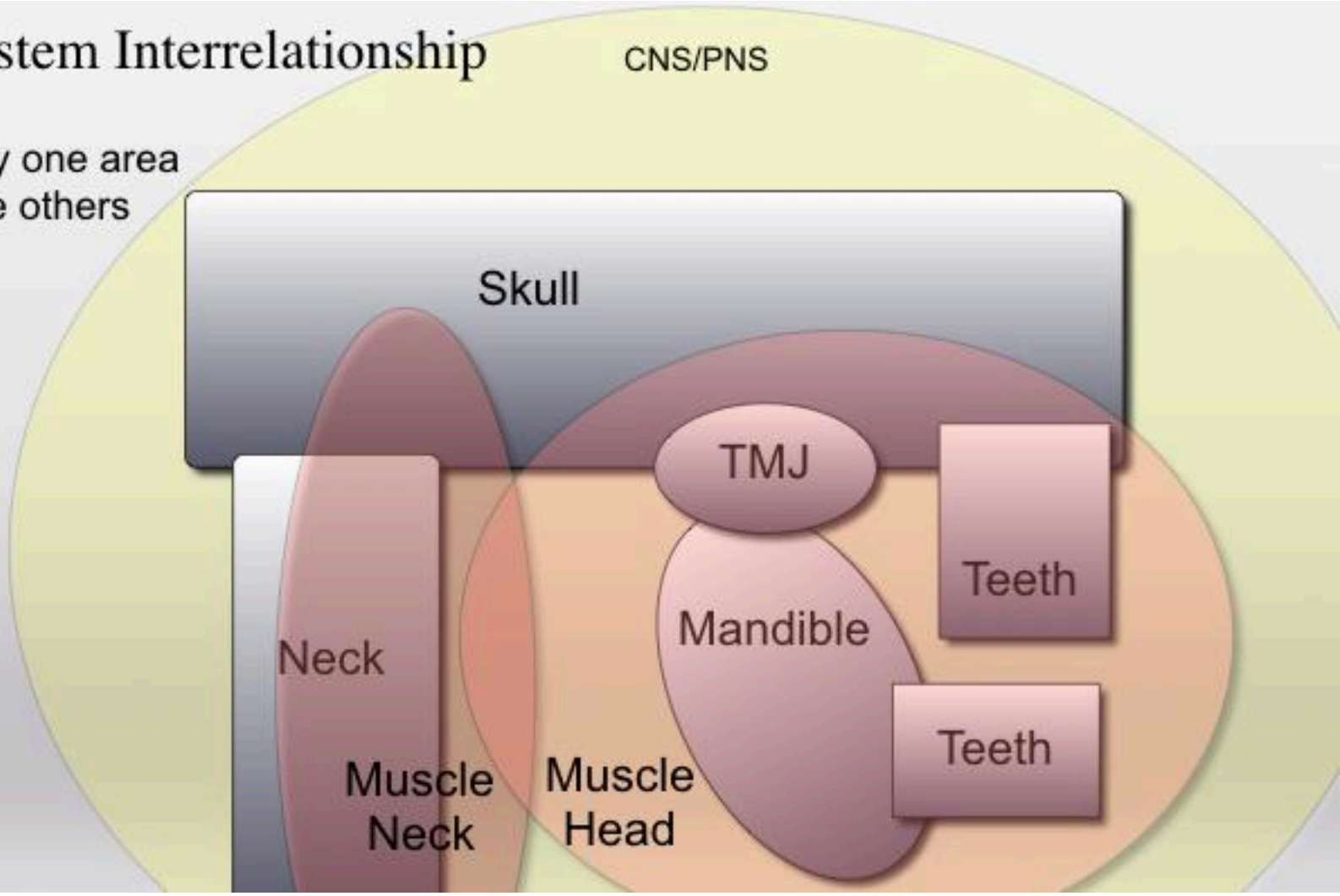

venn diagram

Diseases that cause bone loss in Joints

Osteoarthrosis/Osteoarthrits
Avascular Necrosis
Hypoxia Induced- Progressive Condylar Resorption

Rheumatoid Arthritis
Infection- Lyme Ds, Syphilis, Staph
Crystalline Deposition Disease
Various other Autoimmune Arthritis
Autoimmune Rheumatic Fever
Cancer

Osteoarthrosis/Osteoarthritis

Healthy joints have no friction or wear.
Damaged joints have Friction. Friction causes wear.
OA is a wearing out of a joint which starts in cartilage.
Parafunction increases wear.

Normal

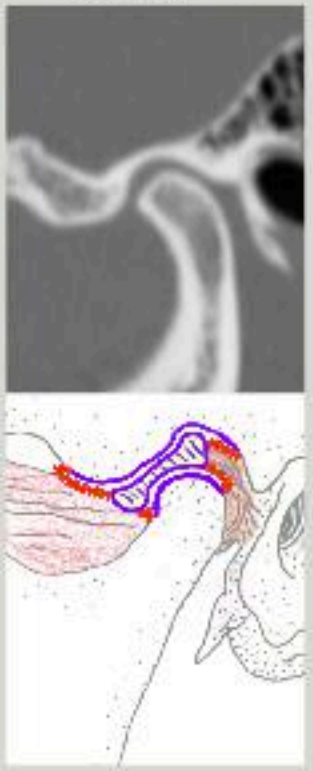

Early

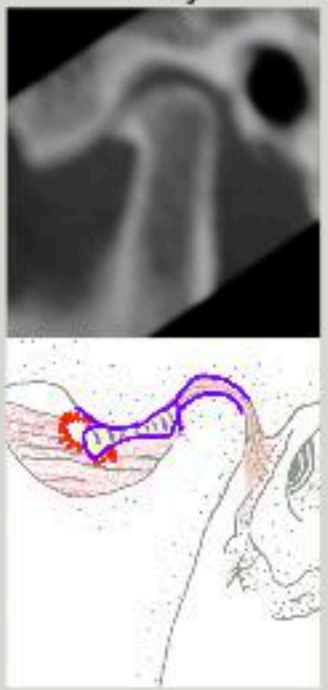

Early/ Moderate

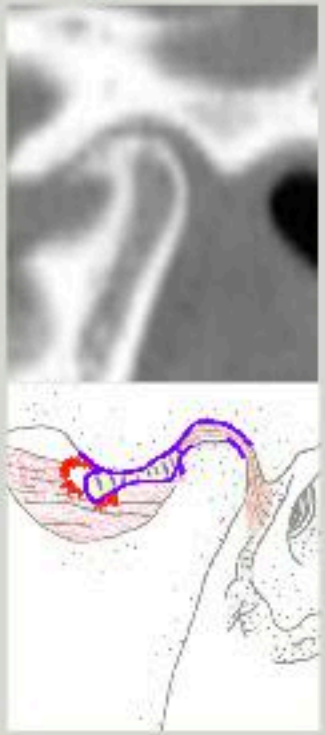

Moderate

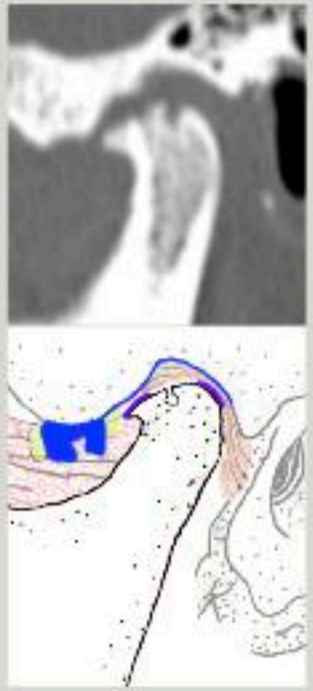

Severe OA, Eburnation

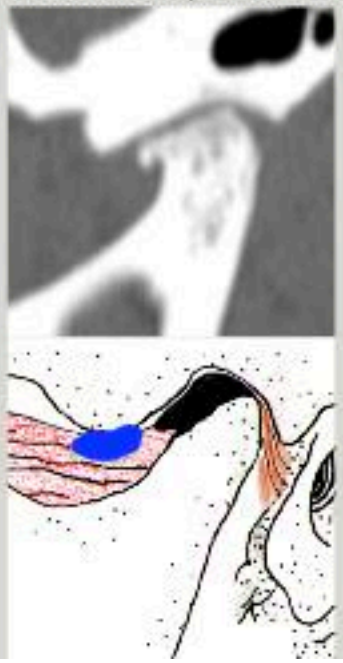

Representative examples of OA
in different patients

Adaptation Chronic Bilateral Osteoarthrosis

Mandible recedes Slowly
Teeth Move/ Adapt
Anterior Guidance gets steeper as Condylar Guidance get shallower

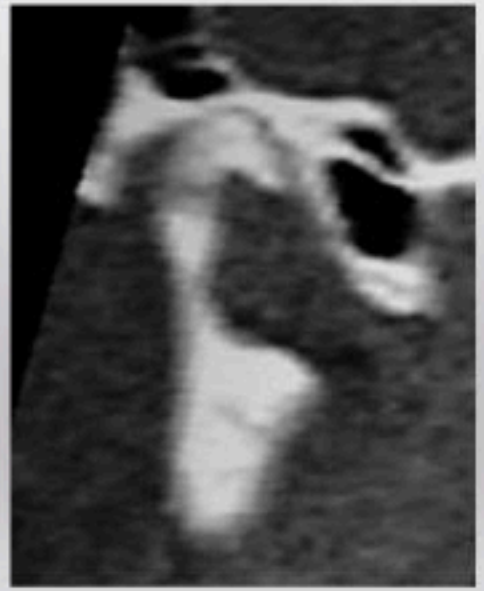

OA Right and Left Bone Loss
#8 Ankylosed

Diseases that cause bone loss in Joints

Osteoarthrosis/Osteoarthrits
Avascular Necrosis
Hypoxia Induced- Progressive Condylar Resorption

Rheumatoid Arthritis
Infection- Lyme Ds, Syphilis, Staph
Crystalline Deposition Disease
Various other Autoimmune Arthritis
Autoimmune Rheumatic Fever
Cancer

Disease of Cartilage.
Slow Bone loss over 10+ years.

Death of Subchondral Bone.
Single event bone collapse.
May lead to Inflamed Tissue.

Disease of Subchondral Bone
Progressive bone lose over several months/years

Diseases that cause bone loss in Joints

Osteoarthrosis/Osteoarthrits
Avascular Necrosis
Hypoxia Induced- Progressive Condylar Resorption

Death of Subchondral Bone.
Single event bone collapse.
May lead to Inflamed Tissue.

Rheumatoid Arthritis
Infection- Lyme Ds, Syphilis, Staph
Crystalline Deposition Disease
Various other Autoimmune Arthritis
Autoimmune Rheumatic Fever
Cancer

Disease of Subchondral Bone
Progressive bone lose over several months/years

Bone is not a static tissue

Constant turnover- 6 months to 1.5y

There is a delicate balance of cell activation/deactivation between the osteoclast and osteoblast.

Osteoclasts
- Resorption- Bone removal

Osteoblasts
- Bone Formation

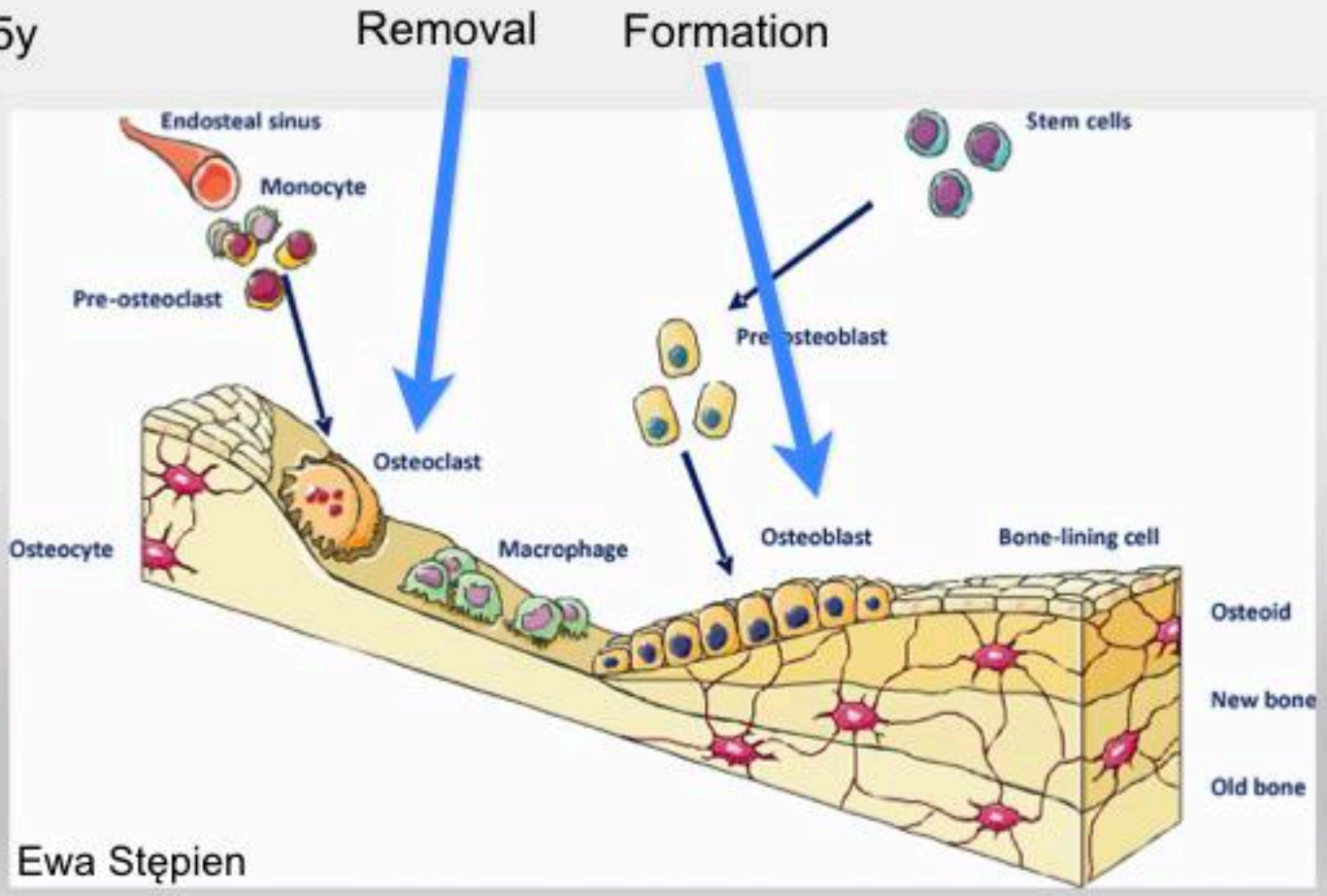

Ewa Stępien

Low Oxygen: Hypoxia

Hypoxia induces pathological bone resorption by activating osteoclast, inhibiting osteoblast

Hypoxia and reperfusion maintains osteoclast activation

Progressive Resorption

Hypoxia increases Osteoclasts

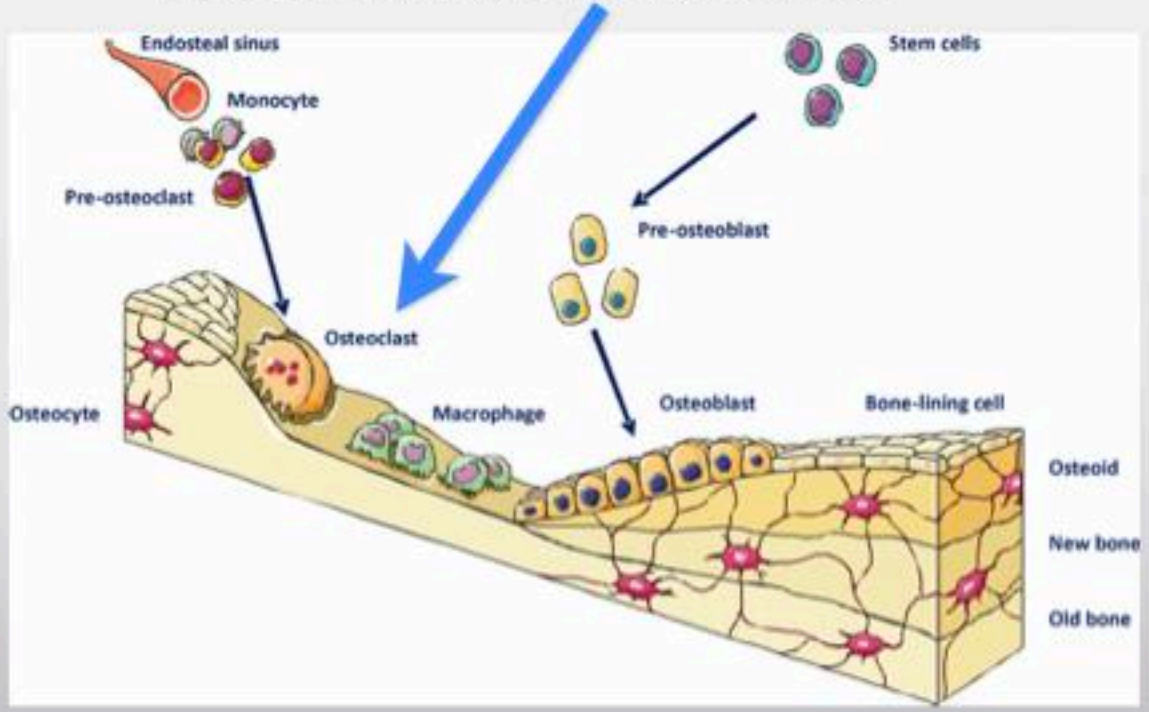

Knowles, H.J. & Athanasou, N.A., 2009. Acute hypoxia and osteoclast activity: a balance between enhanced resorption and increased apoptosis. The Journal of Pathology, 218(2), pp.256–264.

Knowles, H.J. et al., 2010. Hypoxia-inducible factor regulates osteoclast-mediated bone resorption: role of angiopoietin-like 4. FASEB journal : official publication of the Federation of American Societies for Experimental Biology, 24(12), pp.4648–4659.

Condylar Perfusion

Blood flows in and out of the condylar head through vessels that pierce the cortex

Sagittal

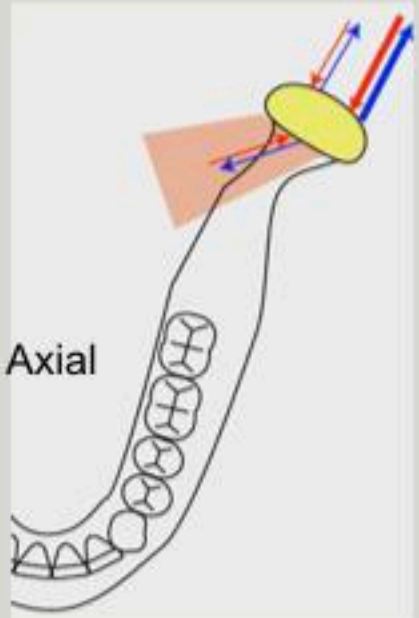

Axial

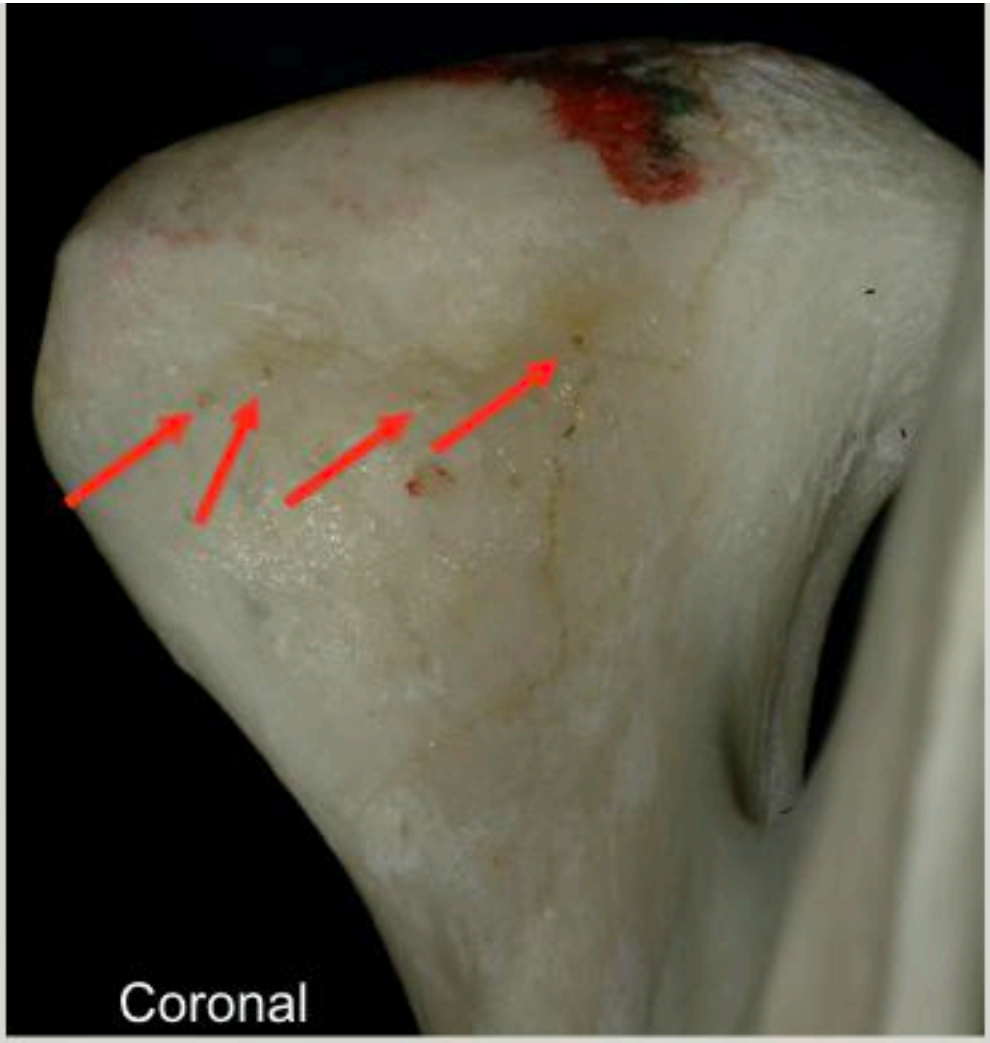

Coronal

Subchondral Bone only has blood vessels from intramedullary

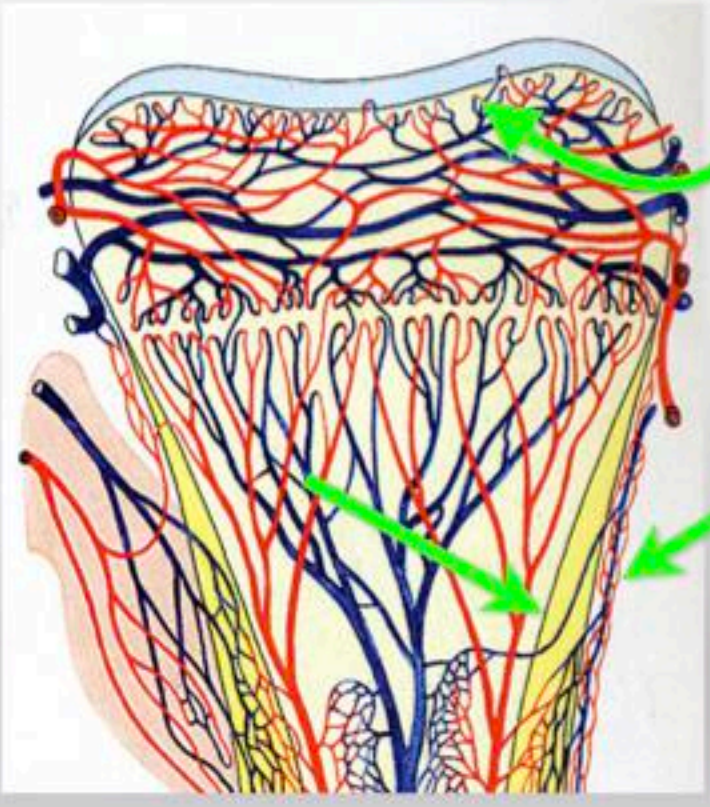

Cortical bone gets blood vessels from both intramedullary and periosteum

Abundant collateral circulation

When the clicking stops (4a to 4b):

Condyle Distalized

Venous return compromised

Compromised Condylar Perfusion
Blood flow through condyle is decreased

Disc Anterior

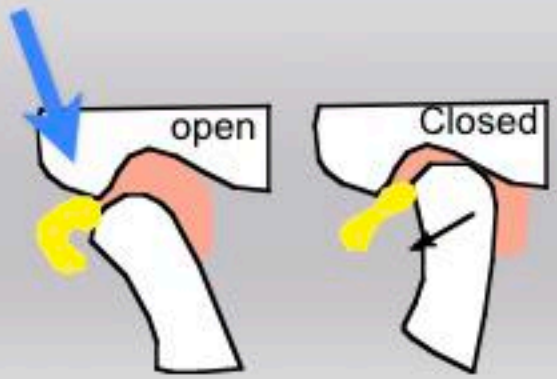

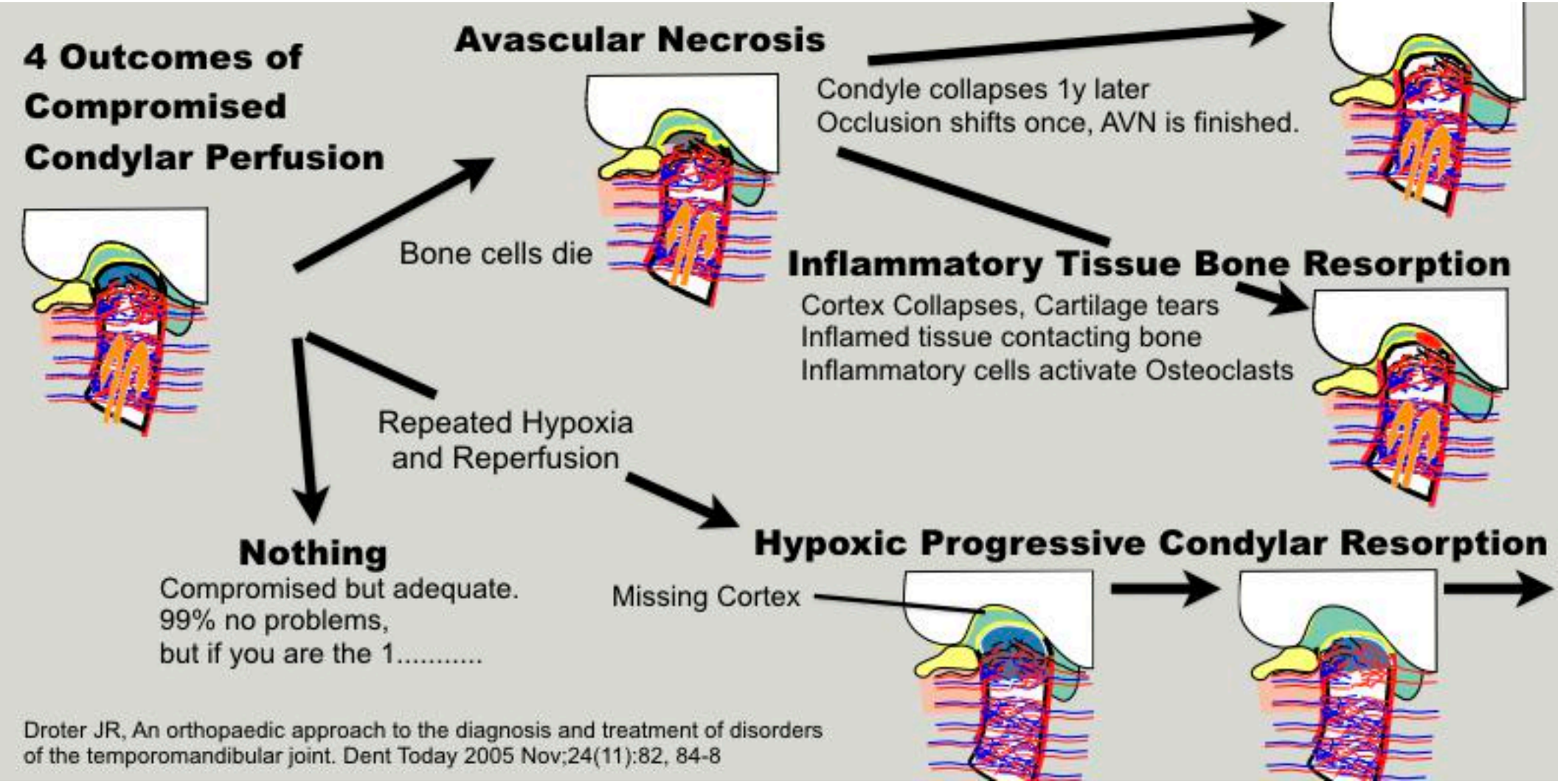

Droter JR, An orthopaedic approach to the diagnosis and treatment of disorders of the temporomandibular joint. Dent Today 2005 Nov;24(11):82, 84-8

Anterior Open Bite Differential Diagnosis

Iatrogenic

TMJ Bone loss

Tongue moved teeth

Hypoxia Induced Progressive Condylar Resorption
HI-PCR

On CT see Flat condylar surface
Missing Subchondral Cortex During Active Phase
Slow, Progressive Condylar Resorption

Occlusion will constantly be changing

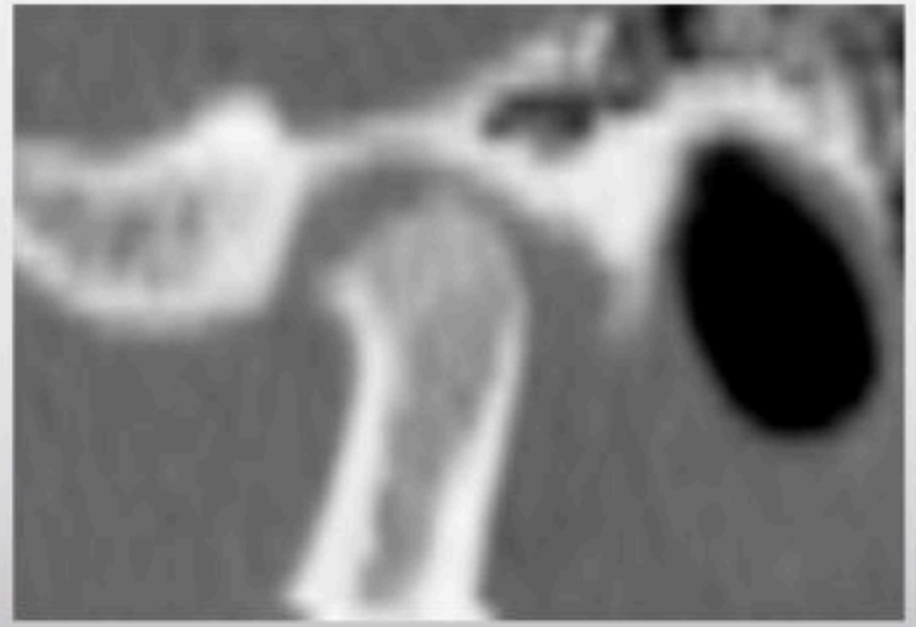

$558,000 Malpractice Verdict

Failure to diagnose condylar resorption during orthodontic treatment

Dental Liability Alert, Vol 5, Issue 6, May 2002

Additional Dental Malpractice Verdicts

■ **$558,000 VERDICT - Failure to diagnose Condylar Resorption - Excessive use of cervical head-gear as part of orthodontic treatment - TMJ Syndrome - Occlusal deficiencies - Osteotomy recommended for minor plaintiff.**

This dental malpractice action was brought on behalf of the minor female plaintiff, age 11 at the time in question, against her treating orthodontist. The plaintiff alleged that the defendant failed to diagnose idiopathic condylar resorption (a condition similar to osteoarthritis) and excessively utilized cervical head gear in her orthodontic treatment, causing permanent mouth and jaw injuries.

The minor plaintiff treated with the defendant for approximately two years for a Class II malocclusion (secondary to crowding in the upper arch), a midline shift and a deep bite/overbite. The defendant prescribed cervical head-gear, comprised of a wire which connects behind the head to pull the molars rearward and leave more room for the incisors. The plaintiff wore the headgear for approximately nine months.

The plaintiff's dental experts testified that the plaintiff suffered from condylar resorption of the jaw during the time period the plaintiff was under the defendant's care and that the condition would have been evidence on x-ray. The plaintiff contended that the standard of care required the defendant to stop all orthodontic treatment under these circumstances and allow the condylar resorption to run its course. The plaintiff contended that the defendant failed to recognize that the plaintiff's jaw was rotating open due to the loss of calcification of the teeth and jaw associated with condylar resorption and that the defendant negligently attempted to reverse the open bite by inappropriate methodology.

The plaintiff's dental expert testified that the methodology employed by the defendant worsened the plaintiff's open bite, causing her to develop TMJ syndrome and requiring a future Lefort I (lower jaw) osteotomy. The cost of the plaintiff's surgery was estimated as between $25,000 and $30,000, according to the plaintiff's oral surgeon. The plaintiff alleged that had the defendant performed a proper examination, treated the dental dysfunction adequately and referred her to the proper specialists, the plaintiff would have suffered no injury.

The defendant denied negligence and contended that the plaintiff's resorption process was not detectable with any routine diagnostic study normally used in orthodontic treatment. The defense expert opined that the treatment provided by the defendant comported with the standard. The defense expert additionally maintained that all injuries suffered by the plaintiff were the result of her idiopathic condition. The defendant asserted that he made a timely referral to an oral surgeon who diagnosed the bilateral condylar resorption, a rare condition which is not well understood by the medical community.

The jury found for the plaintiff and awarded $558,000.

"DENTAL LIABILITY ALERT, USPS 010947 is published Bi-monthly for $150/year by Jury Verdict Review Publications, Inc., 45 Springfield Ave., Springfield, N.J. 07081. Periodical Postage Paid at Springfield, N.J. and additional mailing offices. Postmaster: Send Address Changes to Dental Liability Alert 45 Springfield Ave., Springfield, N.J. 07081"

EXPERTS

Plaintiff's orthodontic expert: Ira Farber from Woburn, Ma. Plaintiff's expert oral surgeon: Charlotte White from Tallahassee, Fla. Defendant's dental experts: Charles S. Green from Skokie, Il. and Daniel M. Laskin from Richmond, Va. Defendant's orthodontic expert: Cyril Sadowsky from Skokie, Il.

REFERENCE

Orange County, Fla. Haughey vs. Fowel. Case no. 98-1024. Judge Jefferson D. Miller. Attorney for plaintiff: Christopher M. Larmoyeux of Montgomery & Larmoyeux in West Palm Beach, Fla.; Attorney for defendant: Kenneth L. Baker and John S. Derr of Bush & Derr in Orlando, Fla. ■

The TMJ: What You need to Know

TMJ

Does it Hurt?
Does it Move?
Does it Wobble?
Is it Structurally Stable?

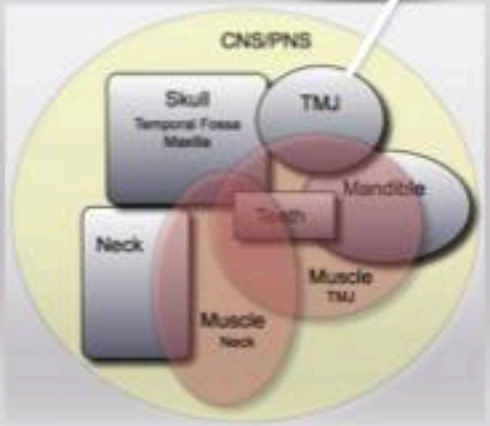

Evaluate every TM joint for:

1. Comfort
2. Movement
3. Mechanical stability- Does the joint wobble on loading?
4. Structural stability- Will the joint lose bone, shift occlusion

If there is a TMJ problem it will be in one of these four areas.

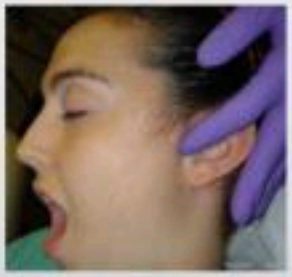

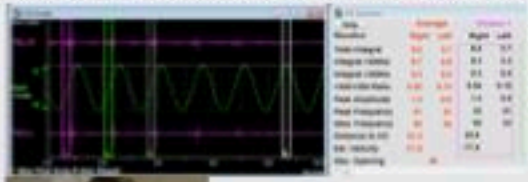



The Bottom Line:

<u>To Minimize Risk and Maximize Benefit before you change an Occlusion:</u>

Palpate and Load the TMJ.
Measure Smoothness and Range of Motion (Quality and Quantity), Record JVA
Put in Anterior Stop Orthotic 24/7 for 2 days- Not Painful
Take CT scan- see intact cortex of condylar bone and fossa

History: Chews well, no pain. No change joint sounds,ROM,or occlusion in past year.

1 year after the clicking stops is the "Danger Zone"

Look for TMJ bone loss, anterior open bite developing
- Avascular Necrosis
- Hypoxia Induced Progressive Condylar Resorption

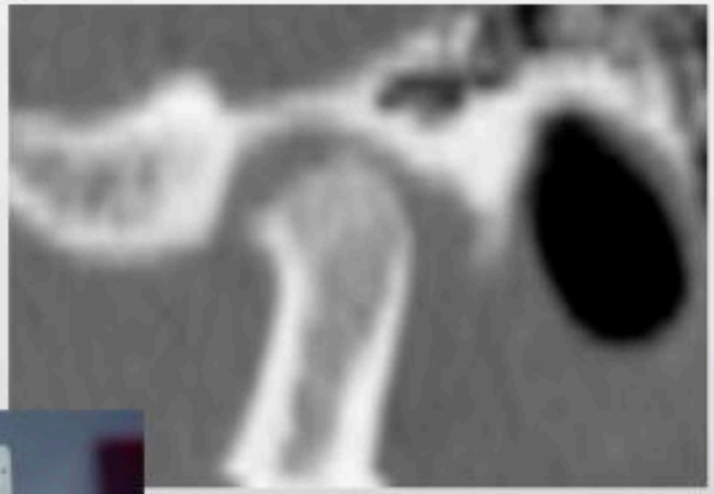

After clicking stops:
- Get CT or CBCT scan of the TMJ
- Maintain jaw motion: PT, exercises
- Get photos
- Mounted models
- Monitor occlusion over the next year
- Follow up CBCT scan 1 year later
- After 1 year "Adapted Favorably"

All Clicking Joints are Damaged

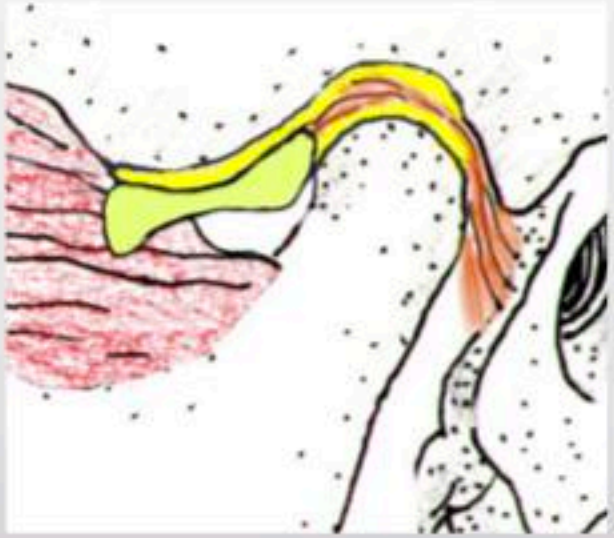

Not so Dangerous Clicks

- Unchanging click for 2+ years
- Consistent, easy reduction of Disc
- Good range of motion with clicking
- Stable occlusion with clicking

Clicks that need further Evaluation/ Scans

- Clicking that has stopped in the past year
- Clicking has changed in the last 2 years
- Wiggling jaw to open. Locking.
- Chronic Painful click
- Unstable Occlusion

Many Dangerous things do not Click

Blinded by the Click

There is no rule that says you only get one disease

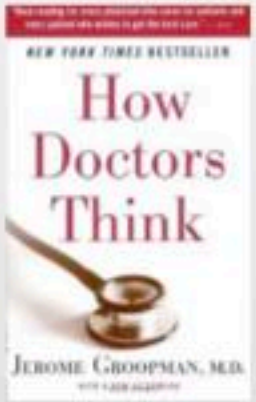

Always make a differential diagnostic list
Ask, " It appears to be this, but what else could it be?
Be aware you are blinded by your beliefs

Jaw is clicking, ear pain

Jaw is clicking, sudden onset headache, 53 year old

Jaw is clicking, temple pain, pain increases with chewing, 62 year old

Jaw use to click, Jaw stopped clicking and can not open wide

History is key, physical exam is next most important, palpate the muscles and joint.
Notice the Age group does not fit OMD for the second and third patient.
None of the above patients will pass the D-PAS test.
The third patient does not have time for the D-PAS test

My Core Belief

The TMJ is a synovial joint of the human body and will undergo the same disease processes as any other synovial joint

Understanding orthopedic medicine is the key to understanding joints, including the TMJ



Buy Salter's Orthopedic Textbook.
When you have a patient with specific disease (i.e. osteoarthritis), read that chapter.

Textbook of Disorders and Injuries of the Musculoskeletal System
Robert Salter MD

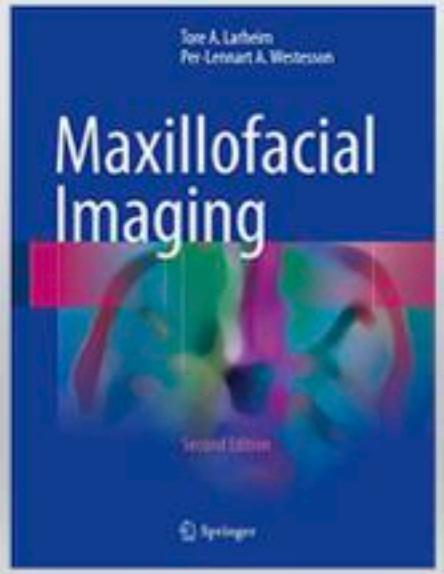

Maxillofacial Imaging
Larheim
Westesson

Basic Orthopedics

Joints are either
- Healthy or
- Damaged

If damaged, joints will be either:
- Actively Breaking Down
- Adapting
- Adaptive Compensation
  - Structurally, Mechanically
  - Favorably, Unfavorably

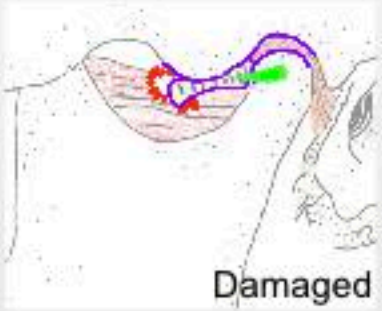

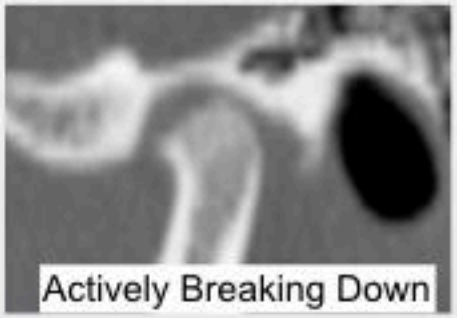

Majority of damaged TMJs adapt favorably

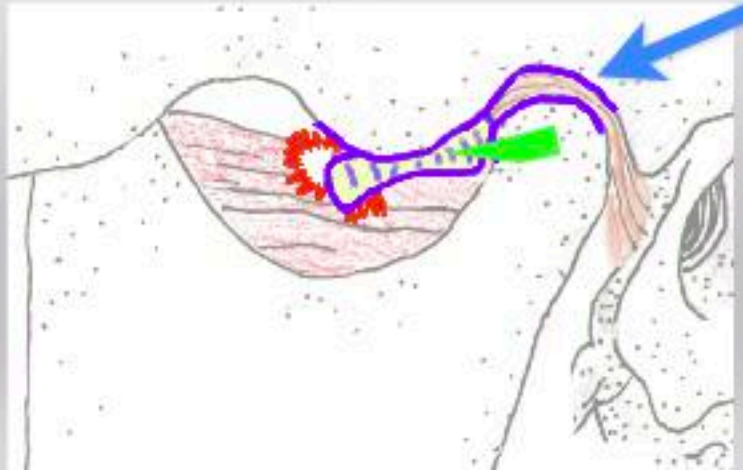

Posterior ligament, synovium, and retrodiscal tissue adapt to form a

Pseudo-disc

Tissue Fibrosis

Stomatognathic System Interrelationship

A change in any one area
will affect the others

"Adaptation"

This is a **dynamic**
orthopedic System

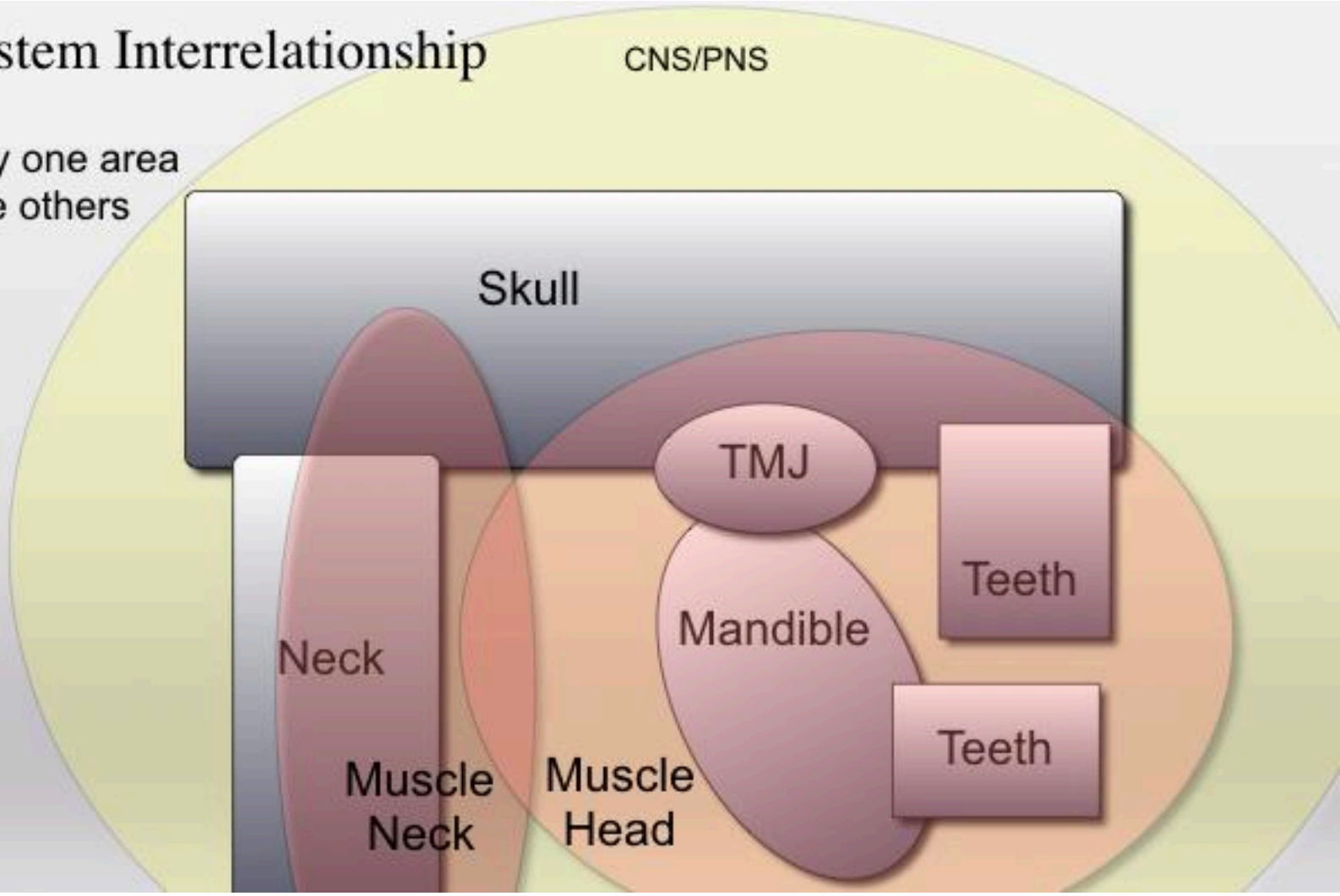

venn diagram